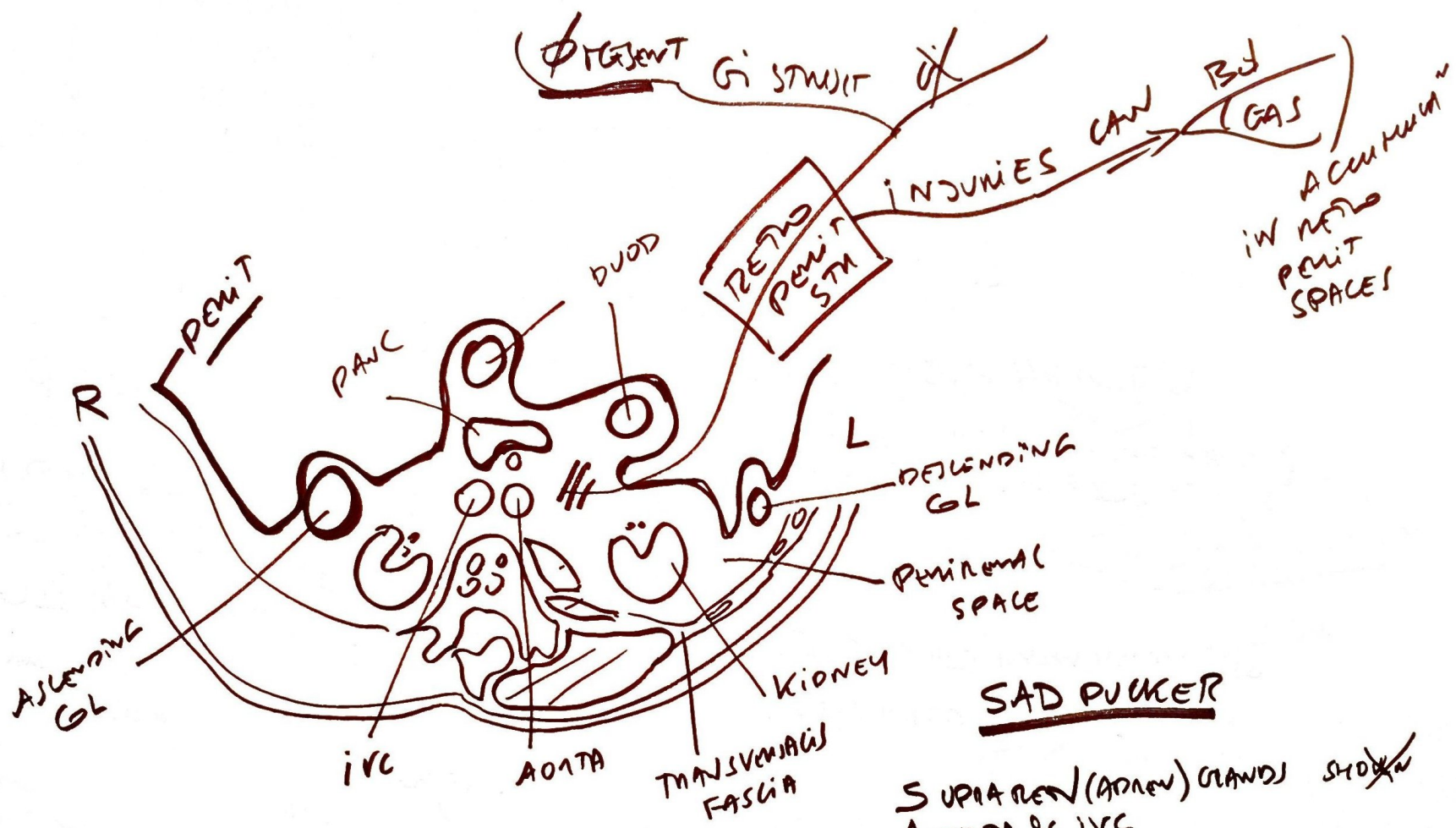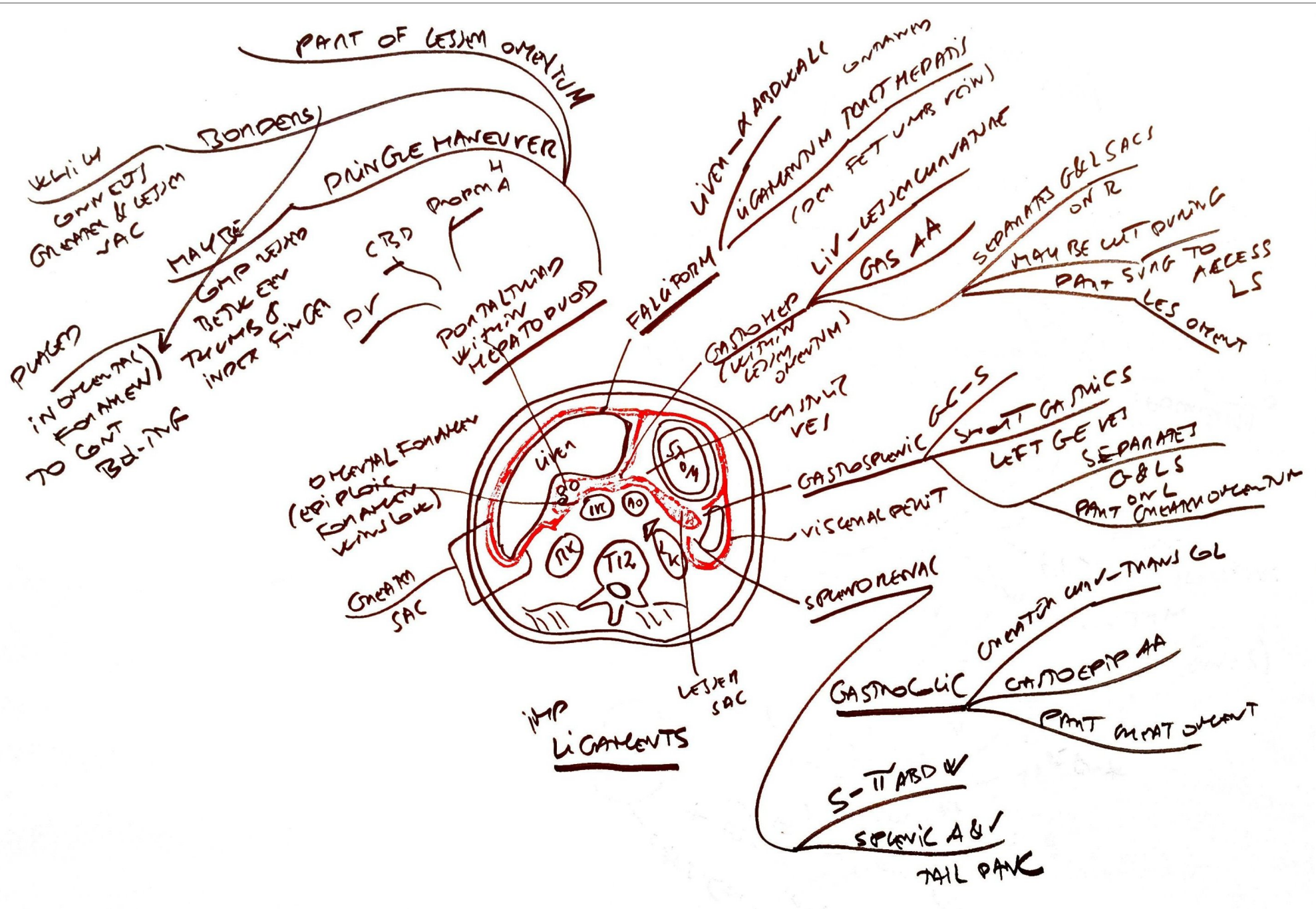

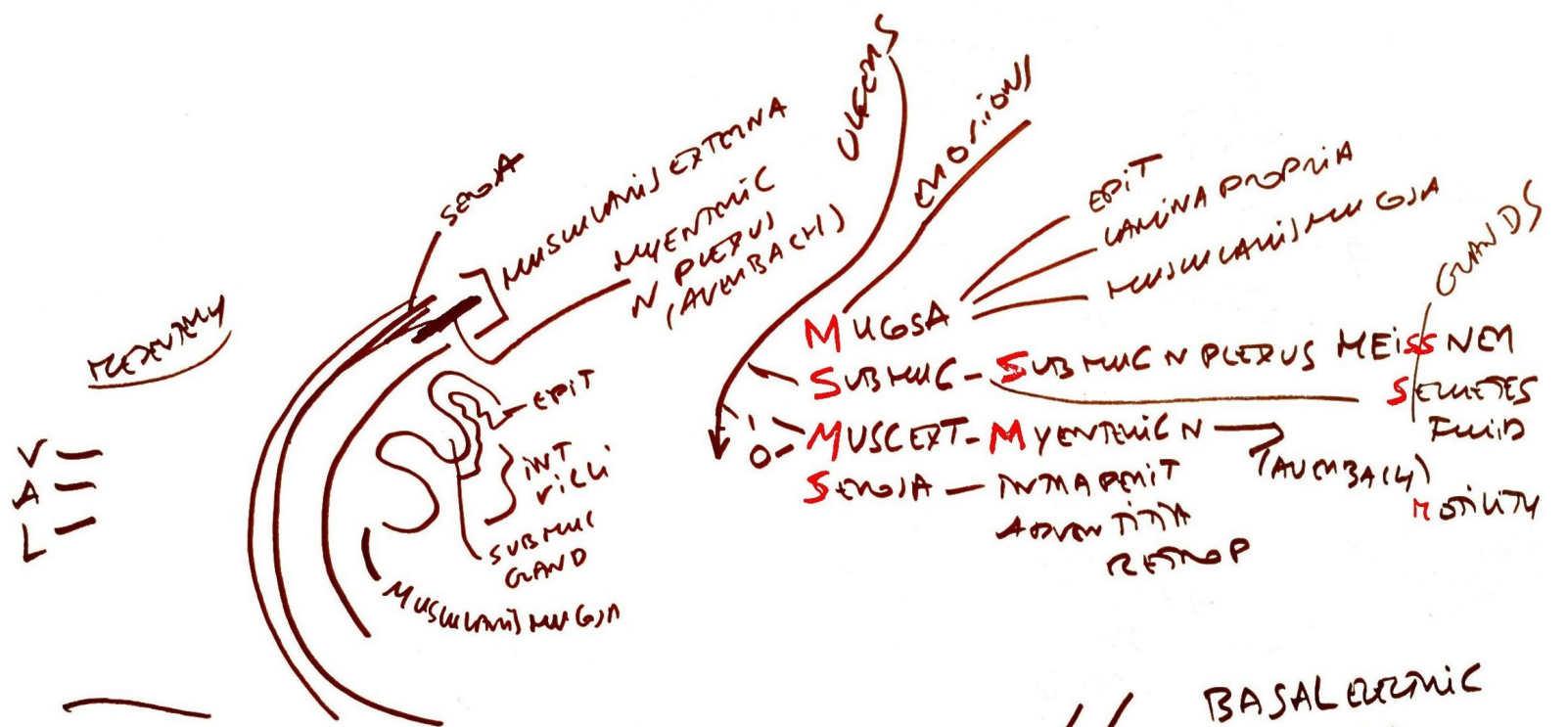
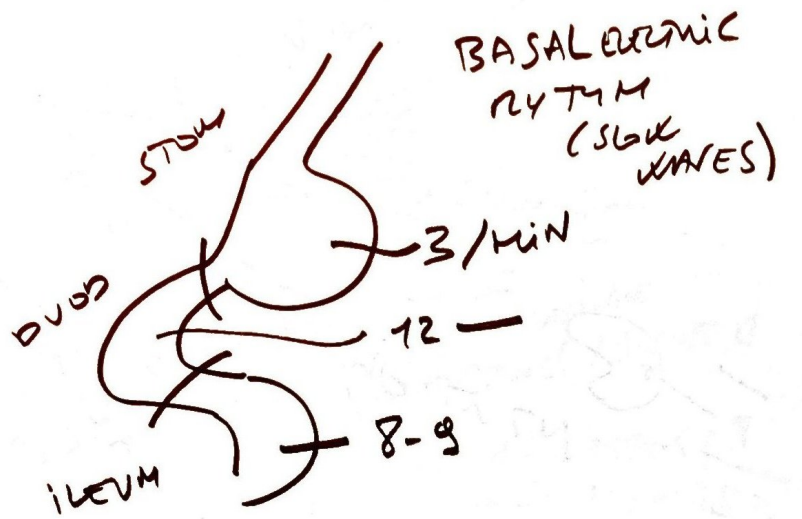
SAD PUCKER

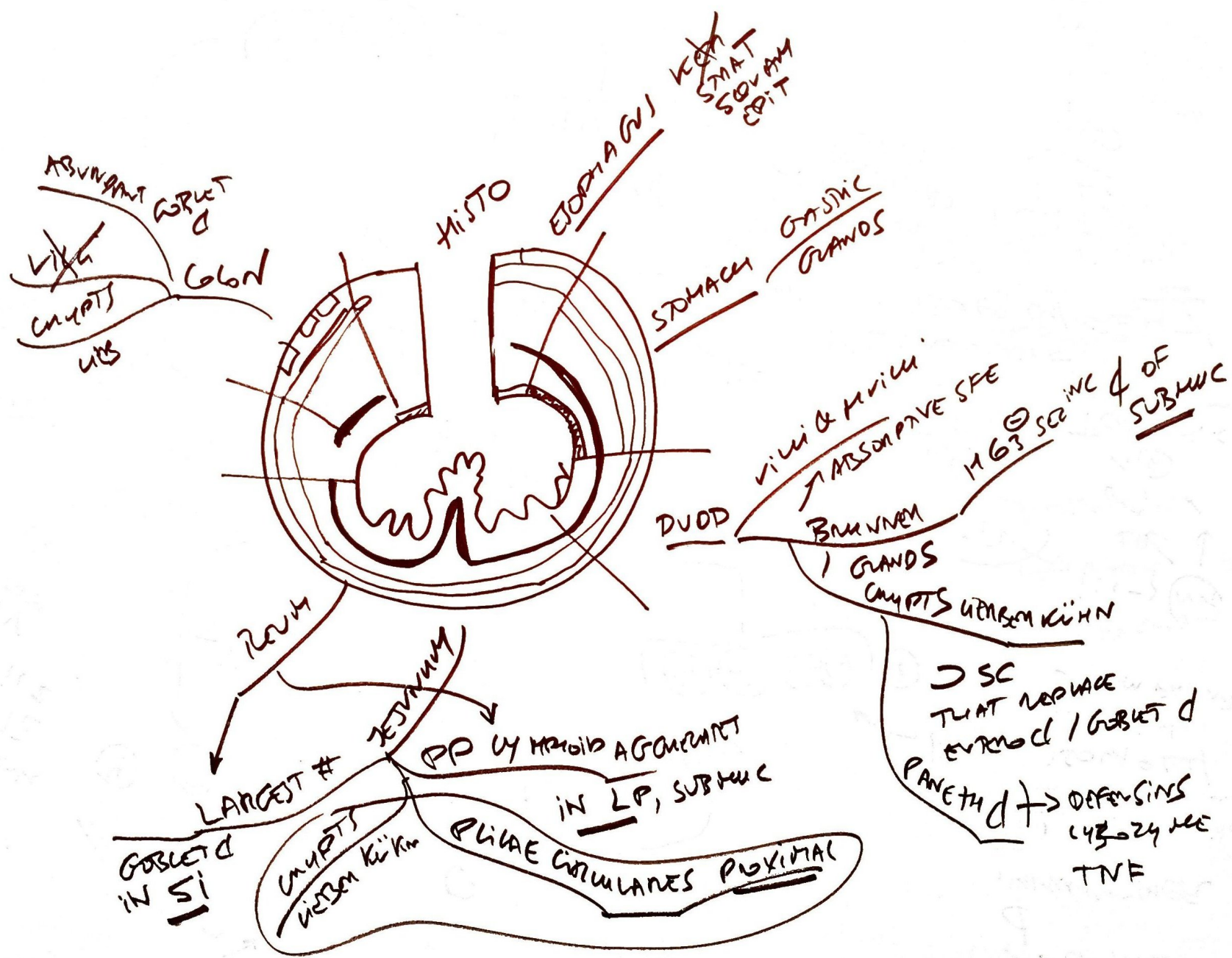
- SUPRAREN (ADREN) GLANDS ~~SHOWN~~
- AORTA & IVC
- DUOD 2ND → 4TH PARTS
- PANC EXCEPT TAIL
- URETERS ~~SHOWN~~
- COLON (DESCENDING & ASCENDING)
- KIDNEYS
- ESOPHAGUS (THORACIC PORTION)
- RENAL PARIETAL ~~SHOWN~~

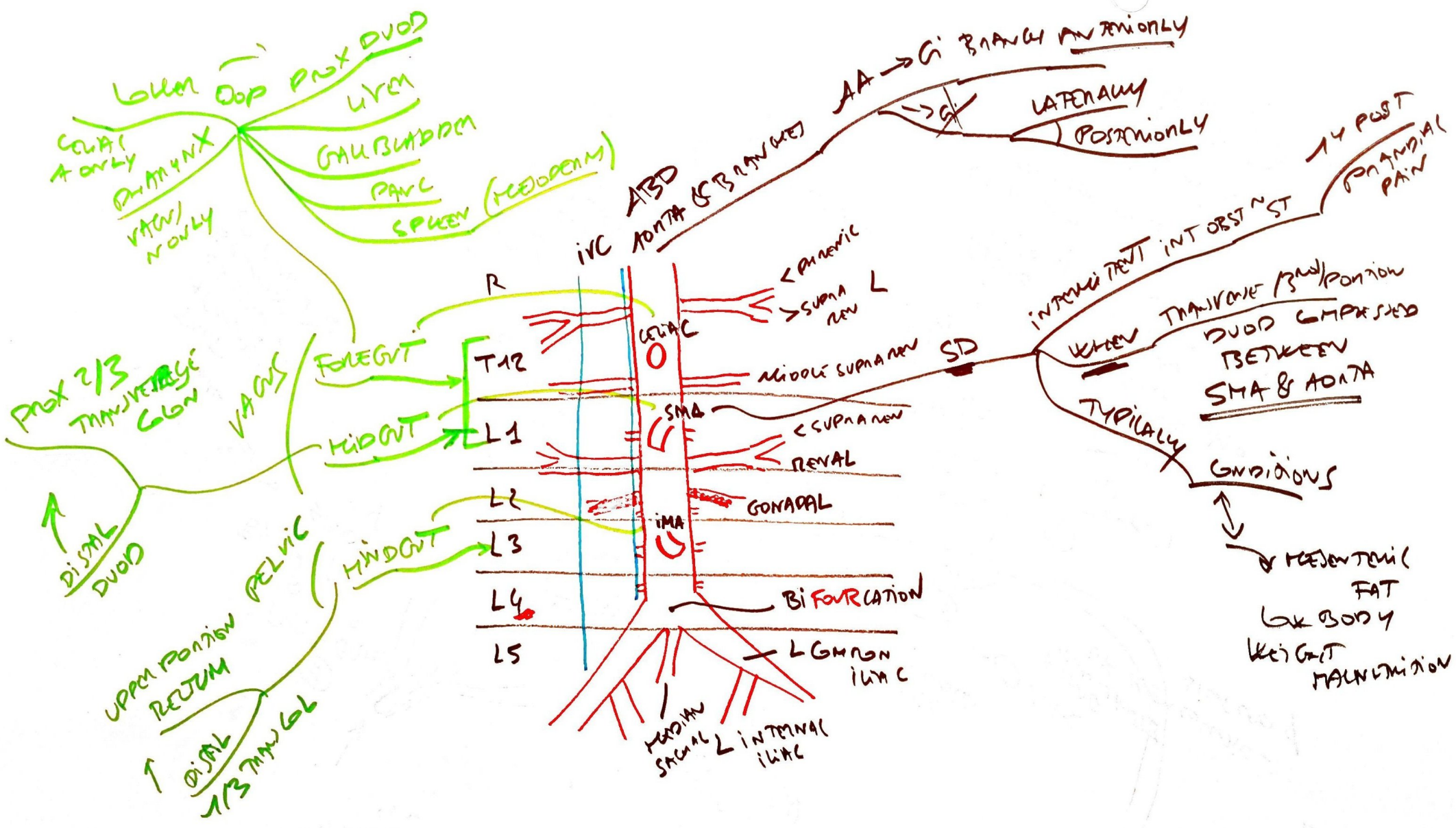


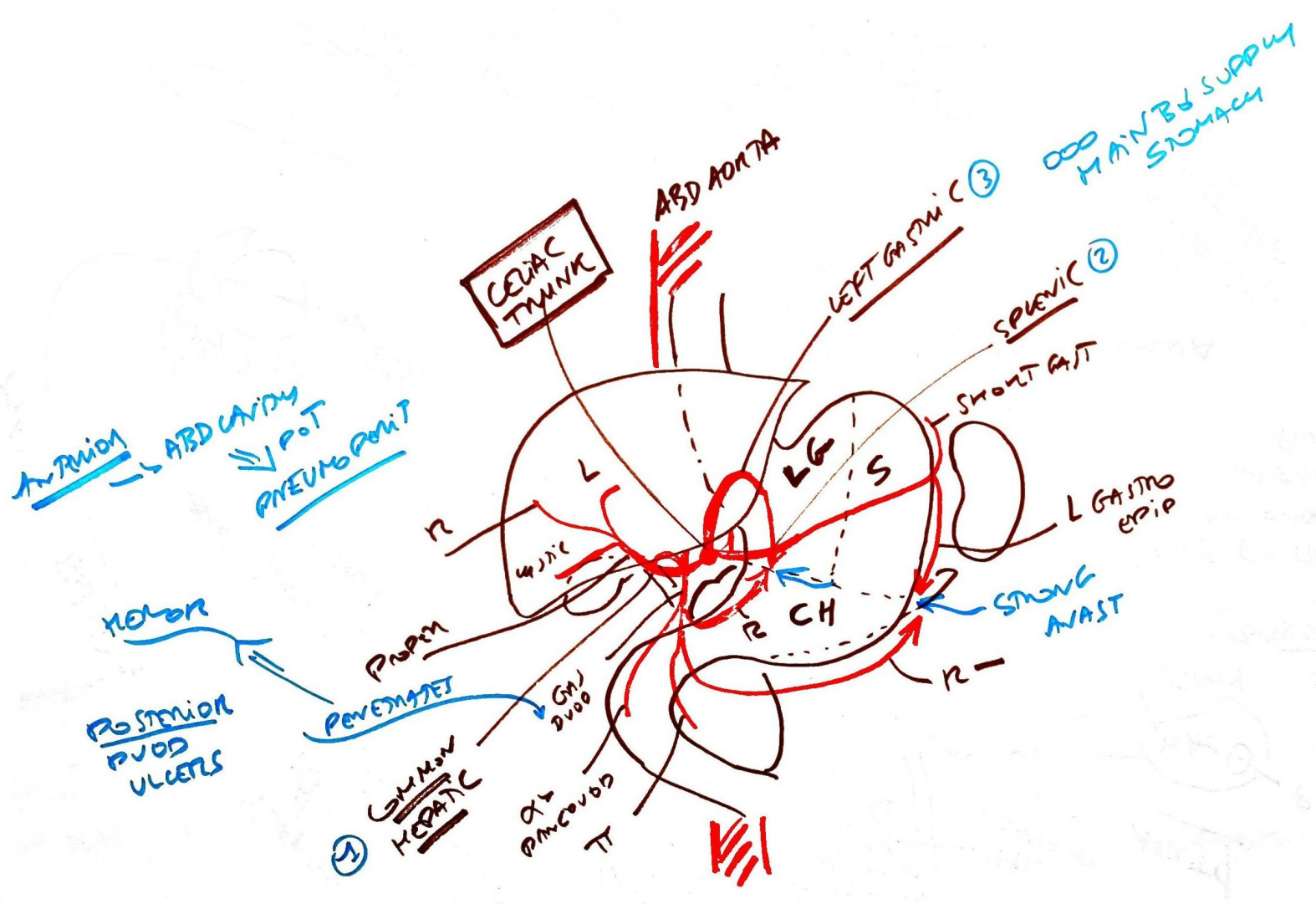


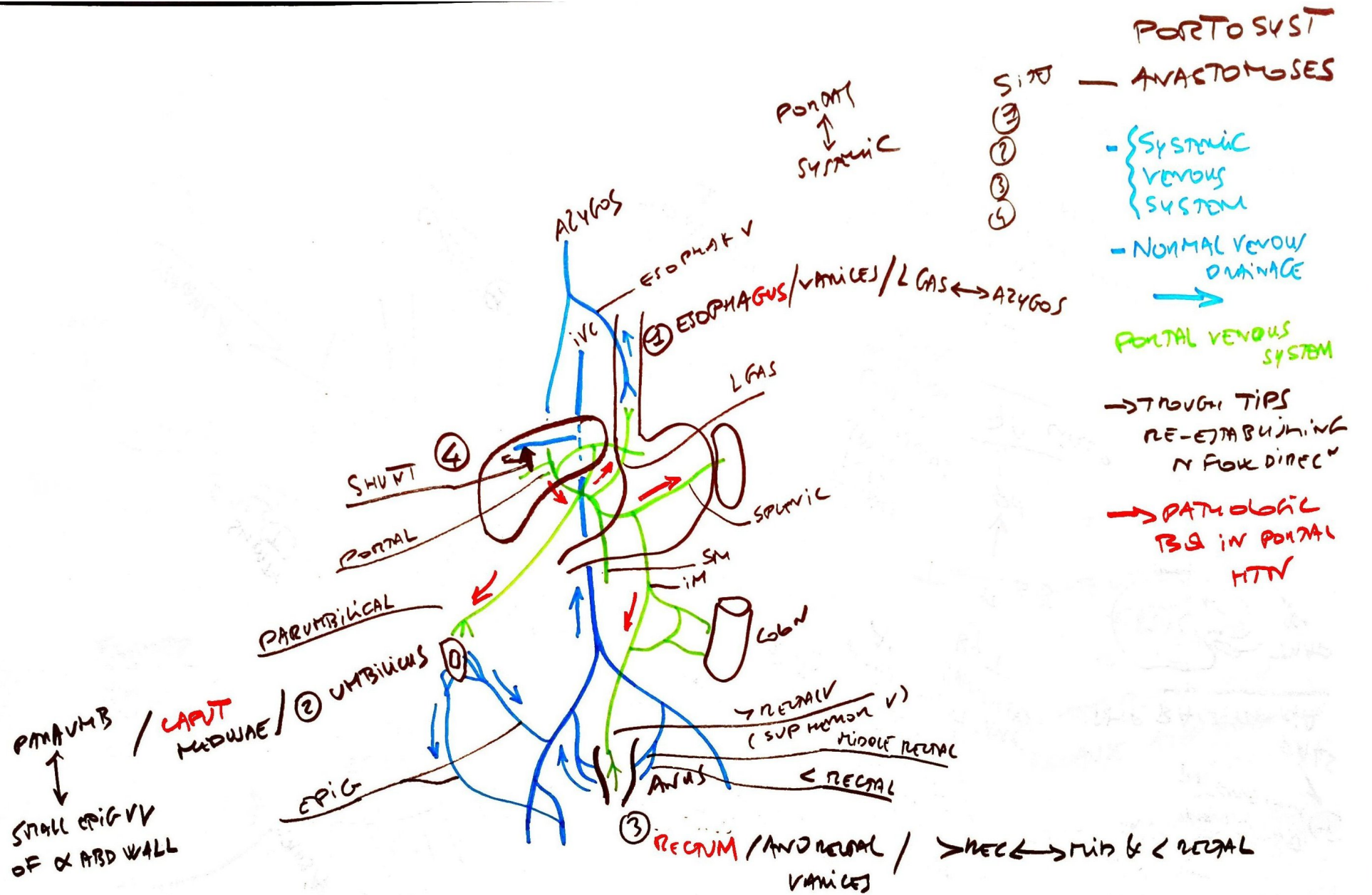
DIGESTIVE TRACT ANATOMY







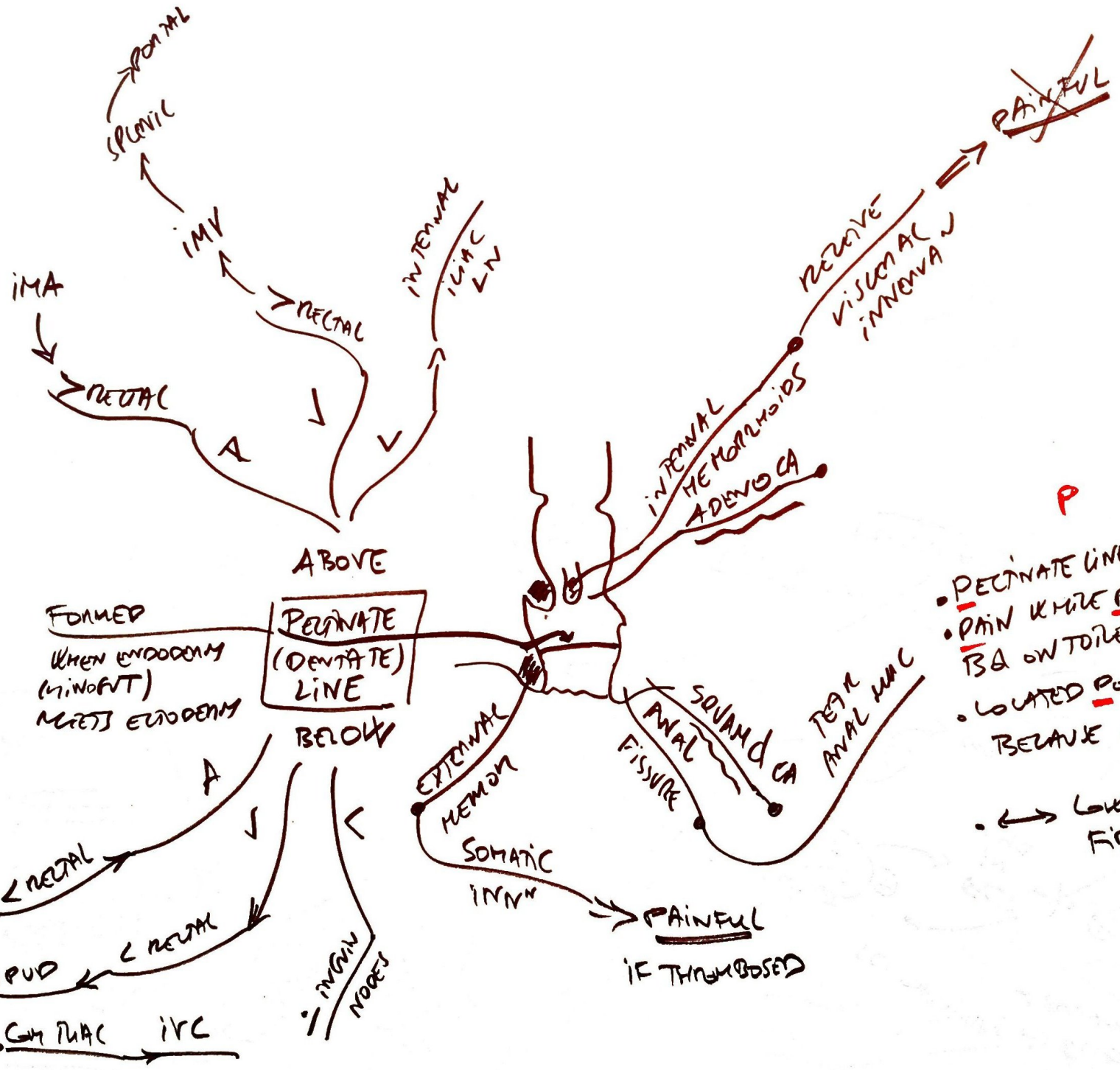




- PORTO SYST ANASTOMOSES
- ③
 - ②
 - ①
 - ④
- SYSTEMIC VENOUS SYSTEM
 - NORMAL VENOUS DRAINAGE
 - PORTAL VENOUS SYSTEM
 - THROUGH TIPS RE-ESTABLISHING N FLOW DIRECTION
 - PATHOLOGIC TIPS IN PORTAL HTN

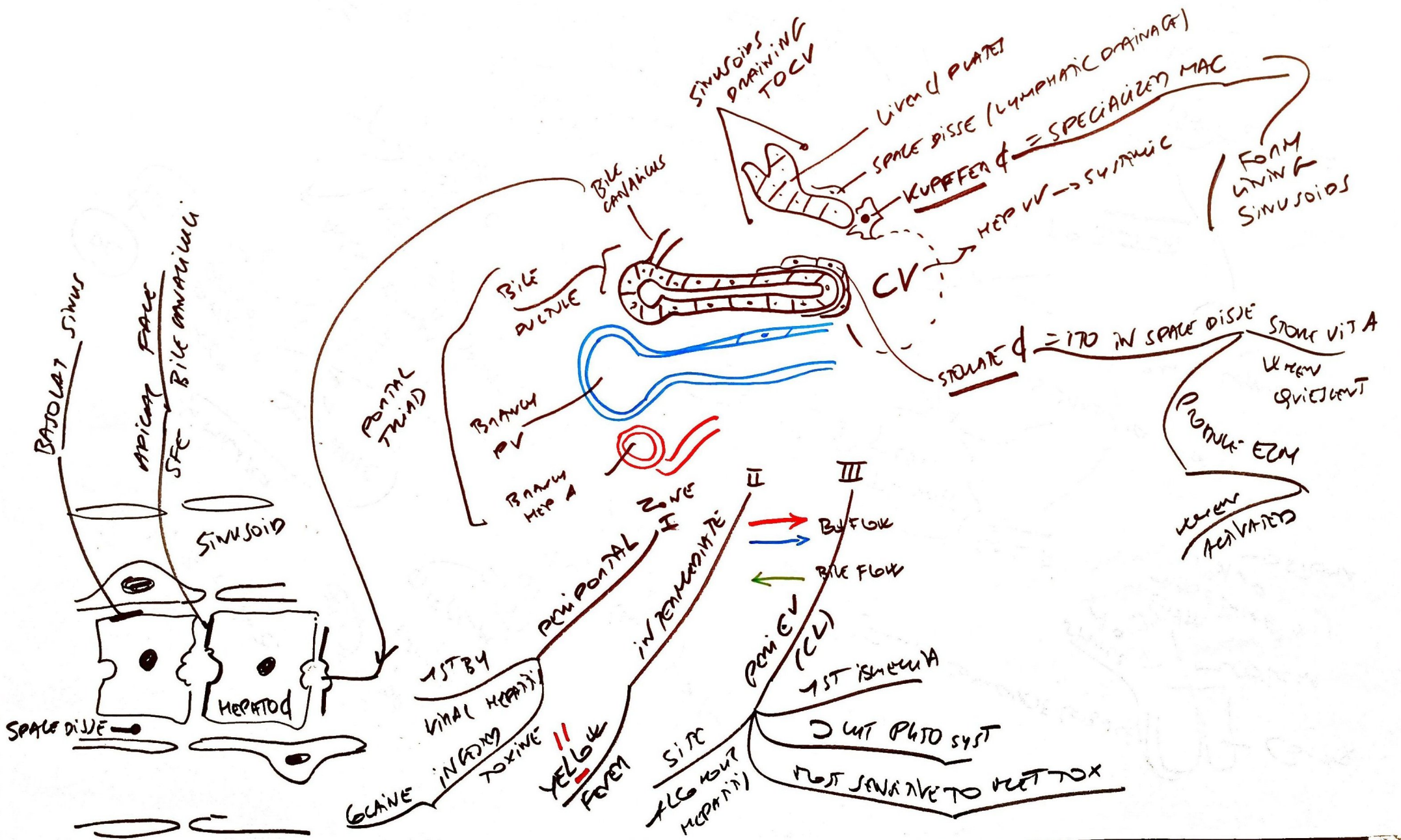
VARIJES OF GUT BUTT CAPUT GM SEEN WITH PORTAL HTN

④ TIPS BETWEEN PORTAL V & HDV → REVERSED
 BY SHUNTING BD TO SYSTEMIC CIRC BYPASSING LIVER • CAN PRECIPITATE HEPATIC ENCEPHALOPAT

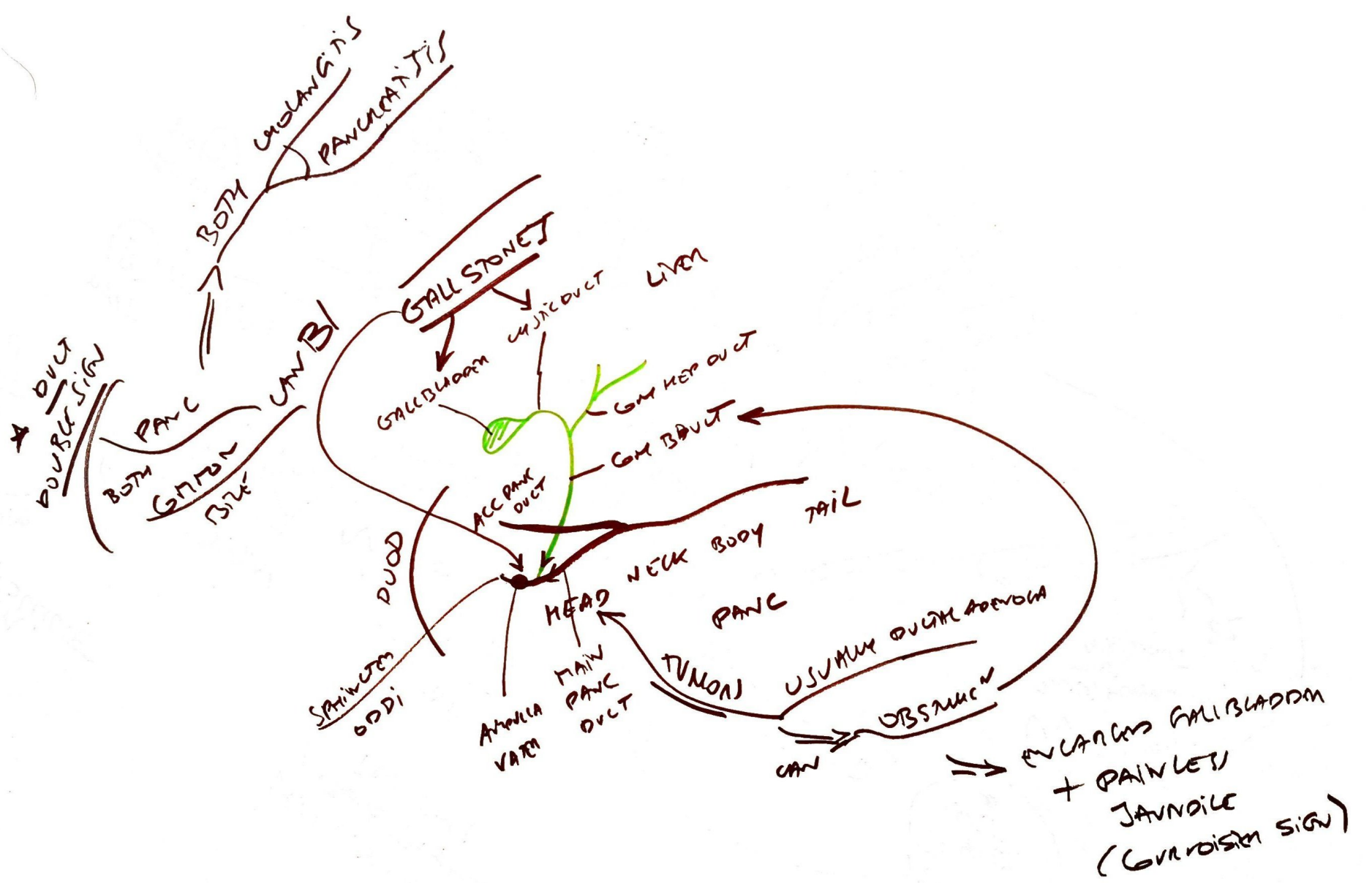


- P
- PECTINATE LINE
 - PAIN WHILE POOPING
 - TSA ON TOILET PAPER
 - LOCATED POSTERIORLY BECAUSE AREA POORLY PERFUSED
 - ← LOW DIET FIBER & CONSTIPATION

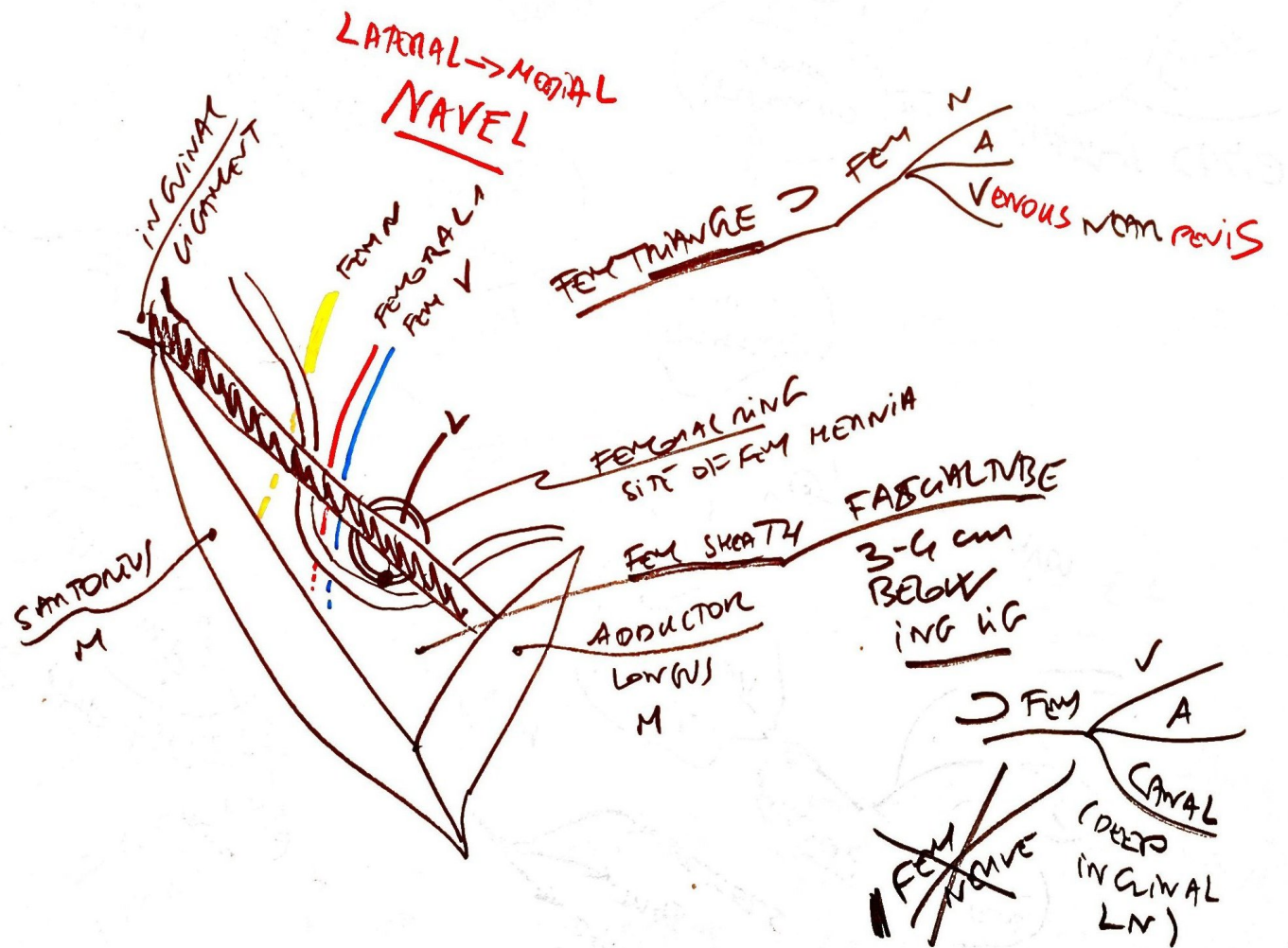
LIVER TISSUE
ARCHITECTURE



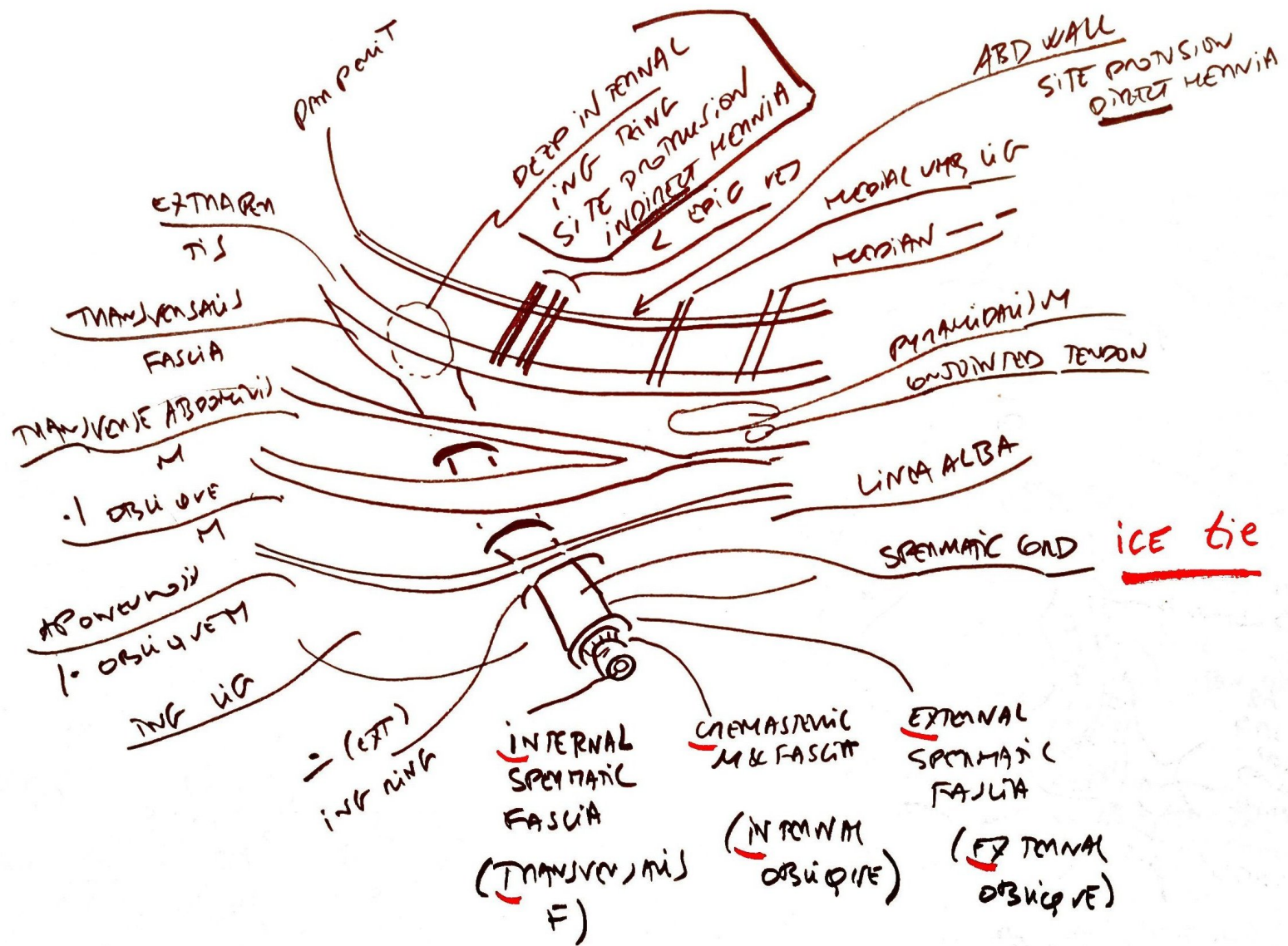
Biliary
STR



FEMORAL REGION



INGUINAL CANAL



MEDICAL DONT LIE

MEDIAL TO \angle EPIC VES = DIRECT
LAT = INDIRECT

