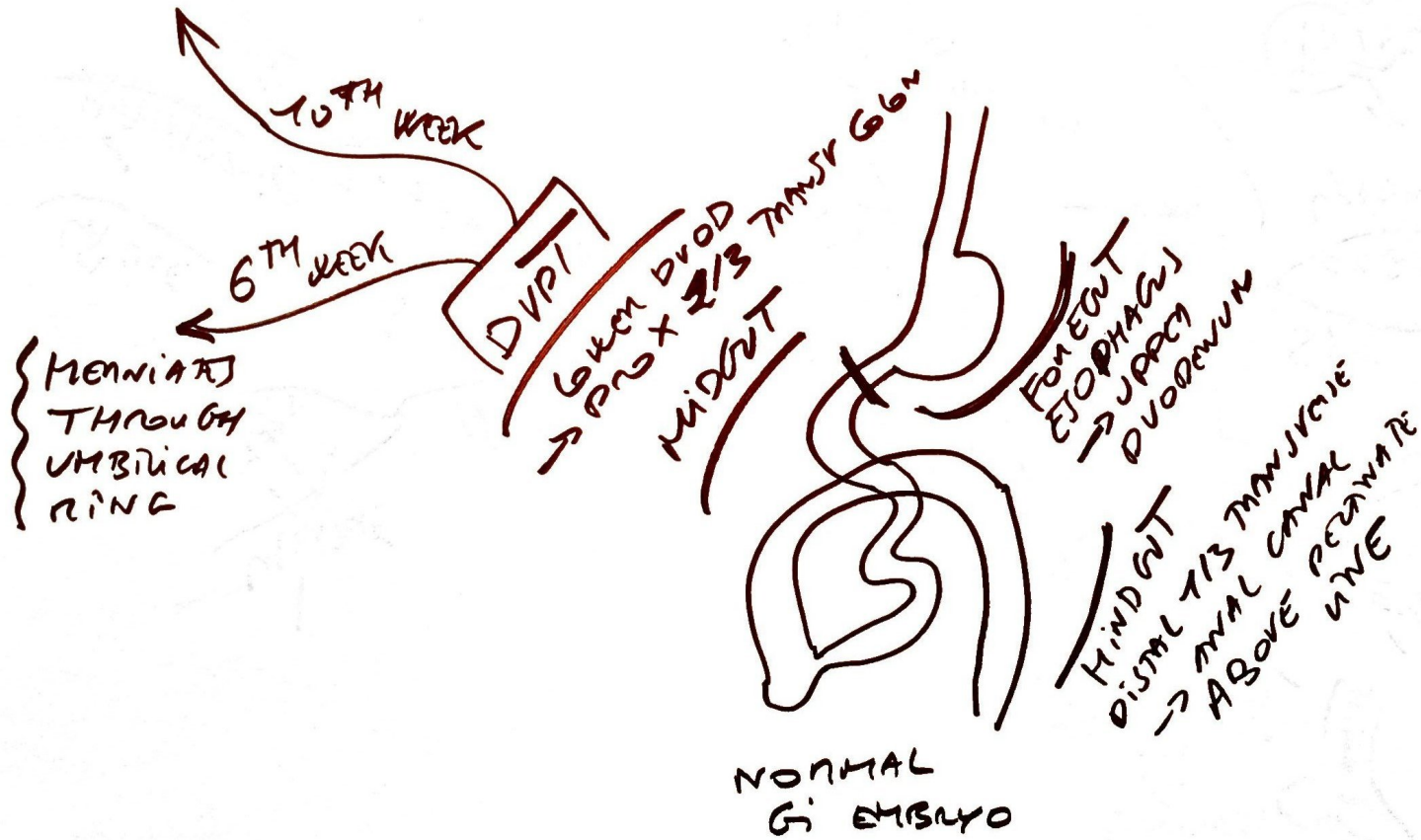
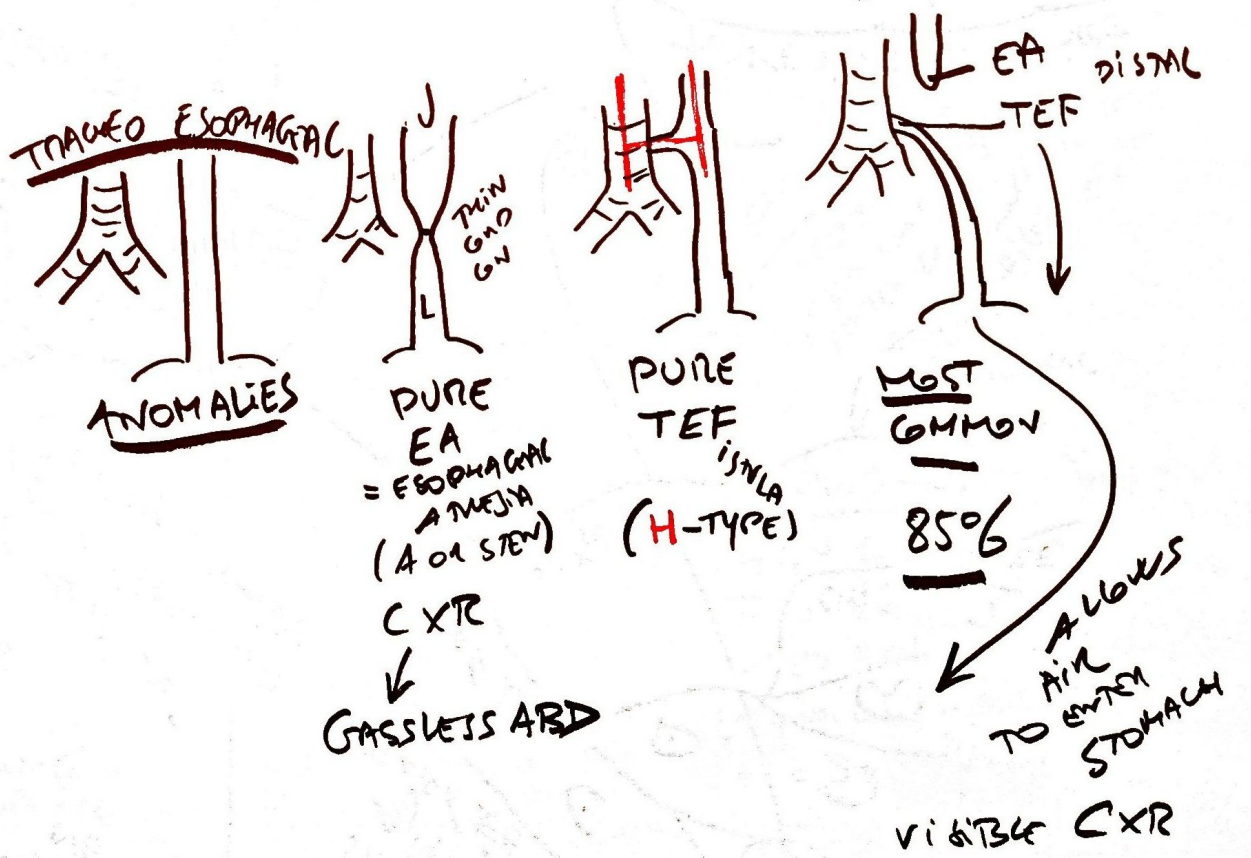
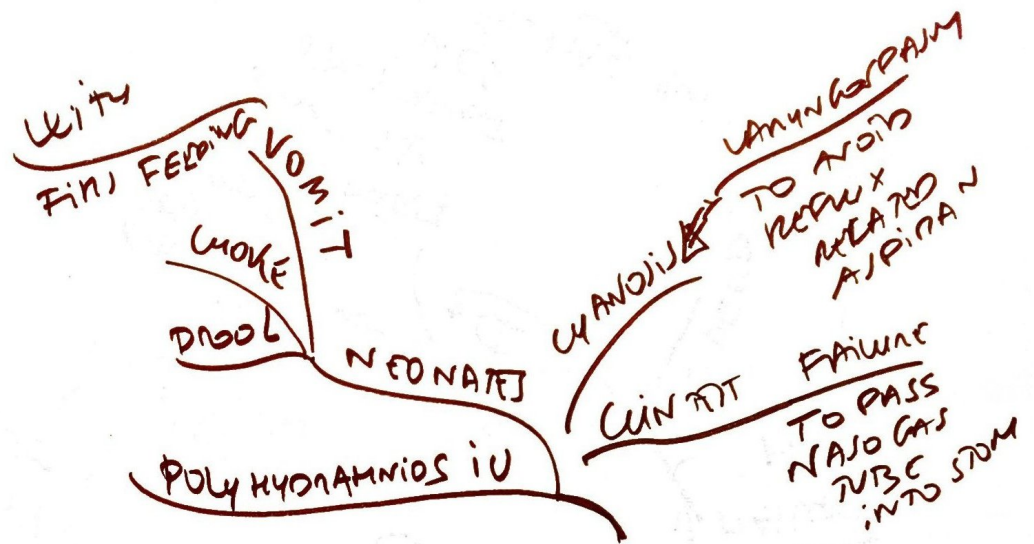
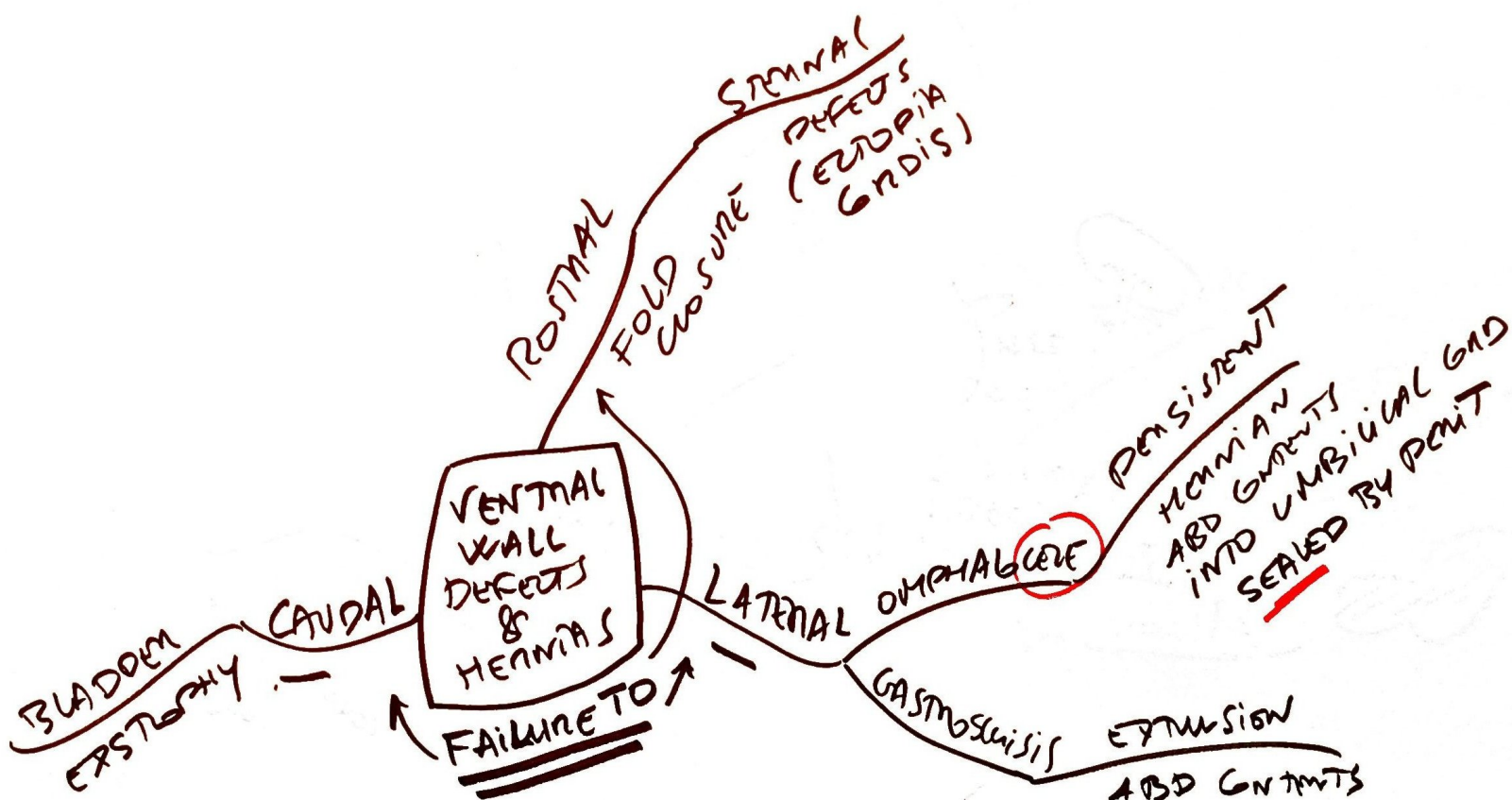


{ RETURNS TO ABD CAVITY
+ ROTATES AROUND SMA TOTAL 270° COUNTER CLOCKWISE







GADIS
 UMBIL
 HERNIA

= INCOMPLETE CLOSURE OF UMBILICAL GROOVE
 MAY CLOSE SPONT

