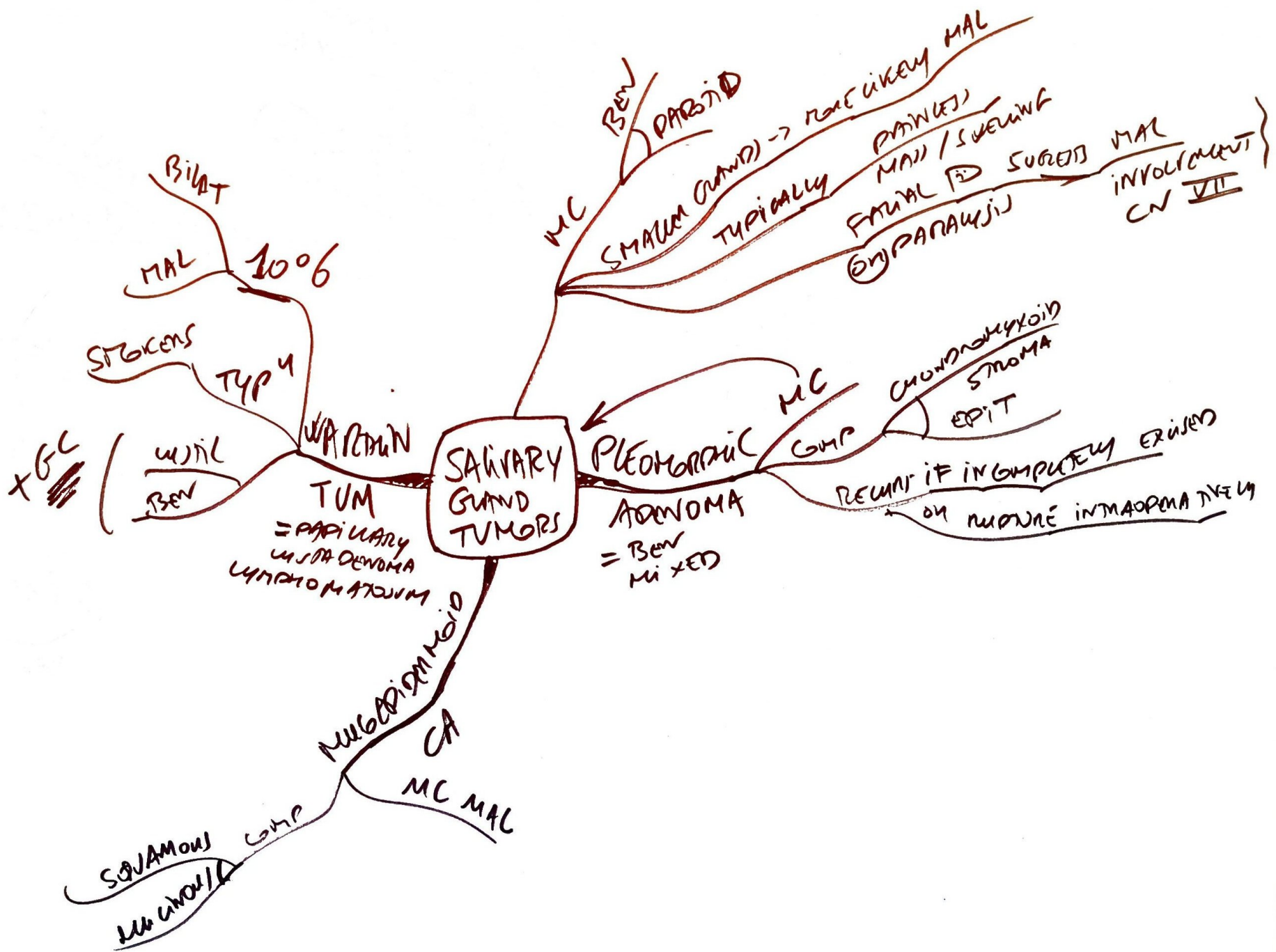
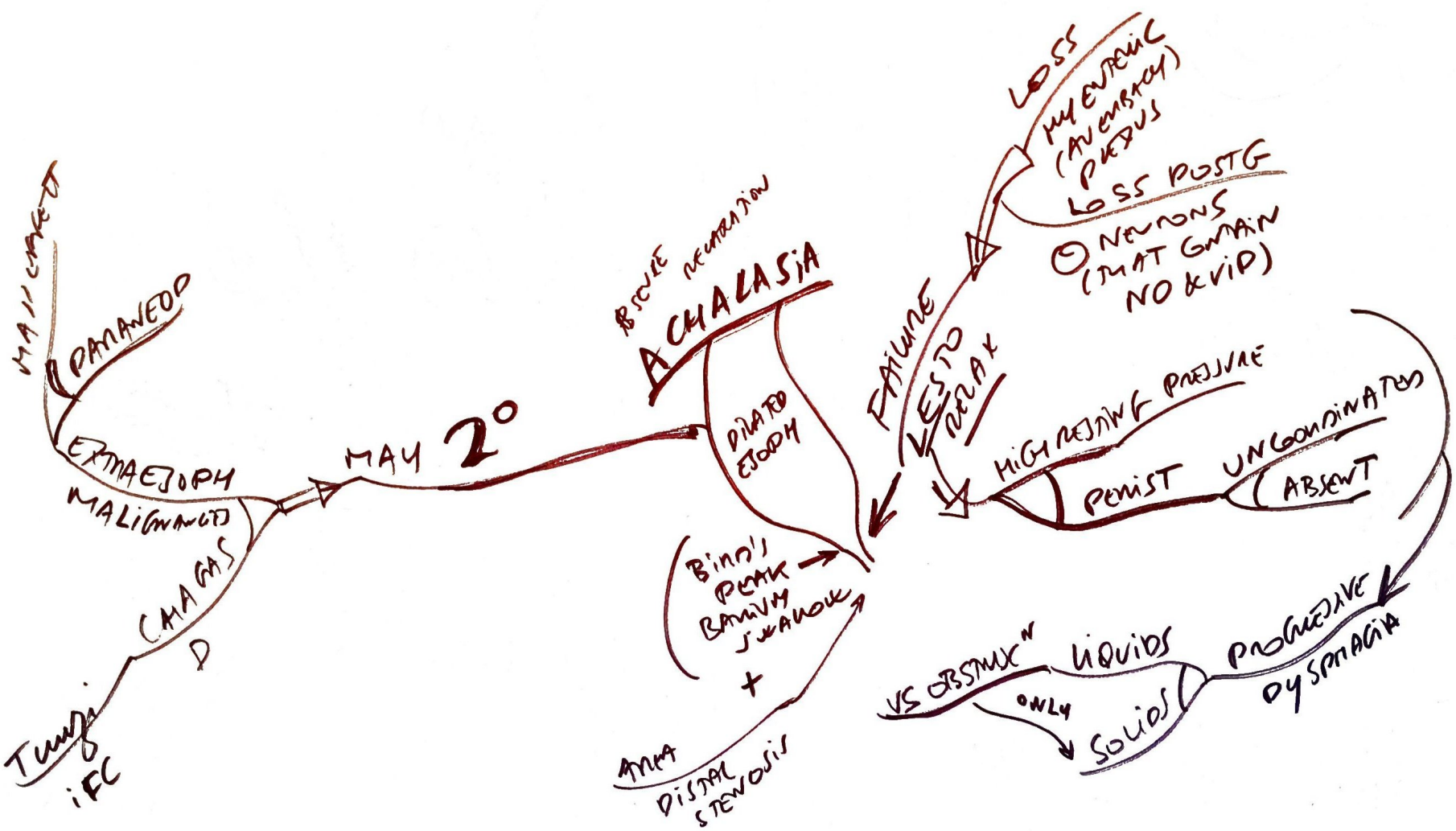
"PUMBS"

DYSPHAGIA  
IRON DEFIC ANEMIA  
ESOPHAGEAL LESIONS

STRICTURE BE & ASPIRIN  
A REFUX & DYSPHAG

LET  
PRESSURE & DISTENSIBILITY  
ESOPH  
SCC  
GLOSSITIS  
MAY

TRIAD

PULLNER-VINSON  
OBSTRUCTION SD

BULIMICS  
ALCOHOLICS  
HEMATEMESIS  
PRET

MAYBE MIS  
OFTN  
MALLORY-WEISS SD  
LACERATIONS

SEVERE VOMITING  
PARTIAL MUC  
LACERATIONS

GET

TRANSIENT  
INLET TONE  
ASTHMA

HOARSENESS  
LARYN TO PHAR REF  
LINDOL  
GUGL  
DYSPHAG  
RETCHING  
HEART BURN  
MAY ALSO  
PRET  
GM

ESOPHAGEAL PATHOLOGIES

GERD

VARICES

ITIS

REFUX

PILL

KCl  
IRON  
NSAIDS

BI-PHOSPHATES  
TETRACYCLINE

CAUSING  
INE

IEC

IMMUNOCOMP

MAN

LIFE THREATENING  
HEMATEMESIS

DILATED W  
SUBMUC  
20

GM

PORAL HITW  
CIRN

CANDIDA WHITE PSEUDO HTS

HSV1 PUNGED OUT ULCERS

CMV LINEAR ULCERS

TRANSJUNCTAL USUALLY  
RUPTURE DISTAL  
+ PNEUMO MEDIASTINUM

BOERHAVIUS SD  
LACERATIONS  
INFILTRATION  
EOSINOPHILIC  
ITIS

STRICTURES  
CAUSING INFLAM AND REFUX

ESOPHAGEAL PATHOLOGIES

GERD

VARICES

ITIS

REFUX

PILL

VIOLENT  
RETCHING

SUBCUT EMPHYSEMA  
MAY DISTINGUISH  
COPD (MAY BE FEET IN NECK REGION ON CHEST WALL)

ESOPHAGEAL PATHOLOGIES

GERD

VARICES

ITIS

REFUX

PILL

IEC

IMMUNOCOMP

MAN

LIFE THREATENING  
HEMATEMESIS

VIOLENT  
RETCHING

SUBCUT EMPHYSEMA  
MAY DISTINGUISH  
COPD (MAY BE FEET IN NECK REGION ON CHEST WALL)

ESOPHAGEAL PATHOLOGIES

GERD

VARICES

ITIS

REFUX

PILL

IEC

IMMUNOCOMP

MAN

LIFE THREATENING  
HEMATEMESIS

VIOLENT  
RETCHING

SUBCUT EMPHYSEMA  
MAY DISTINGUISH  
COPD (MAY BE FEET IN NECK REGION ON CHEST WALL)

ESOPHAGEAL PATHOLOGIES

GERD

VARICES

ITIS

REFUX

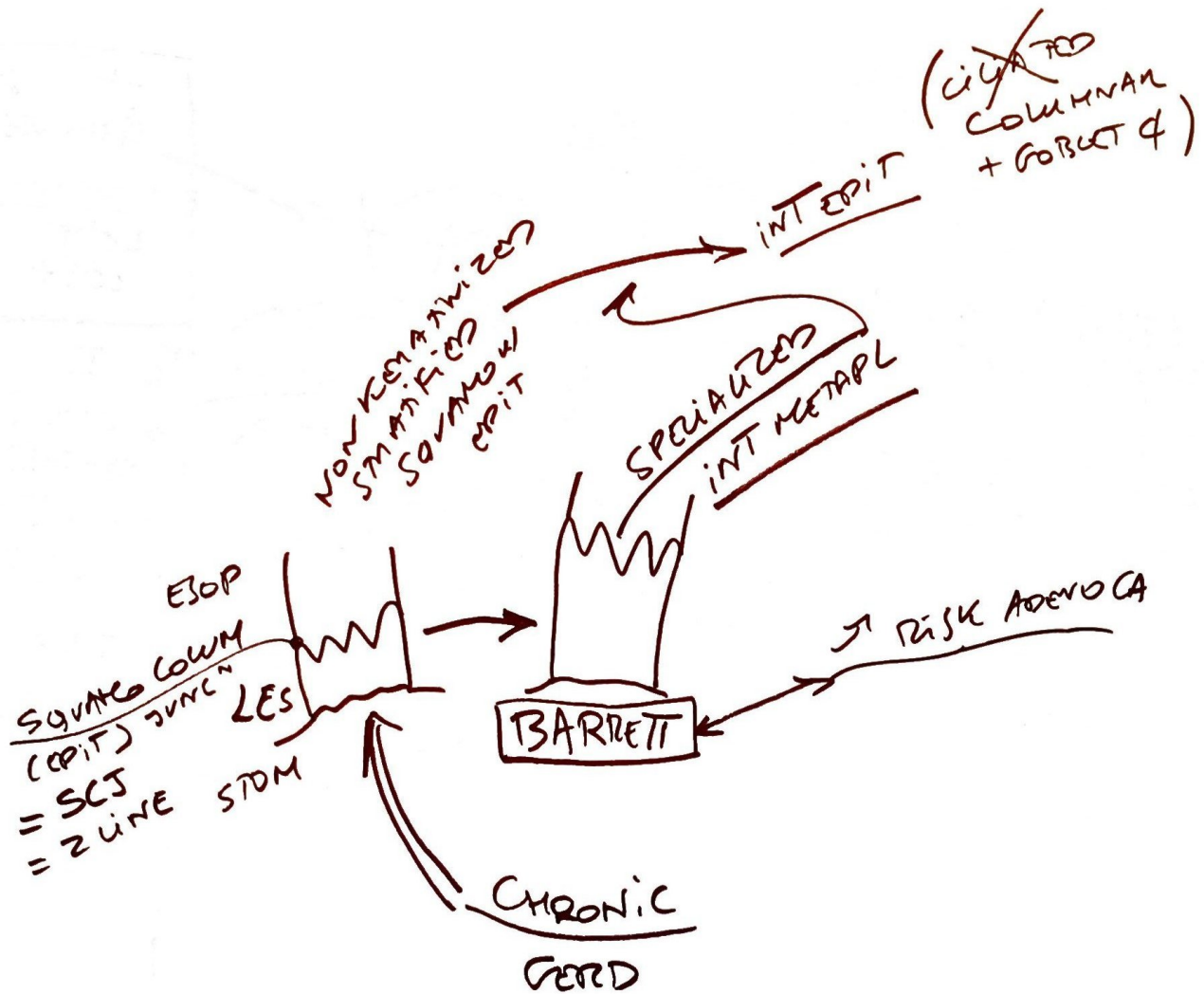
PILL

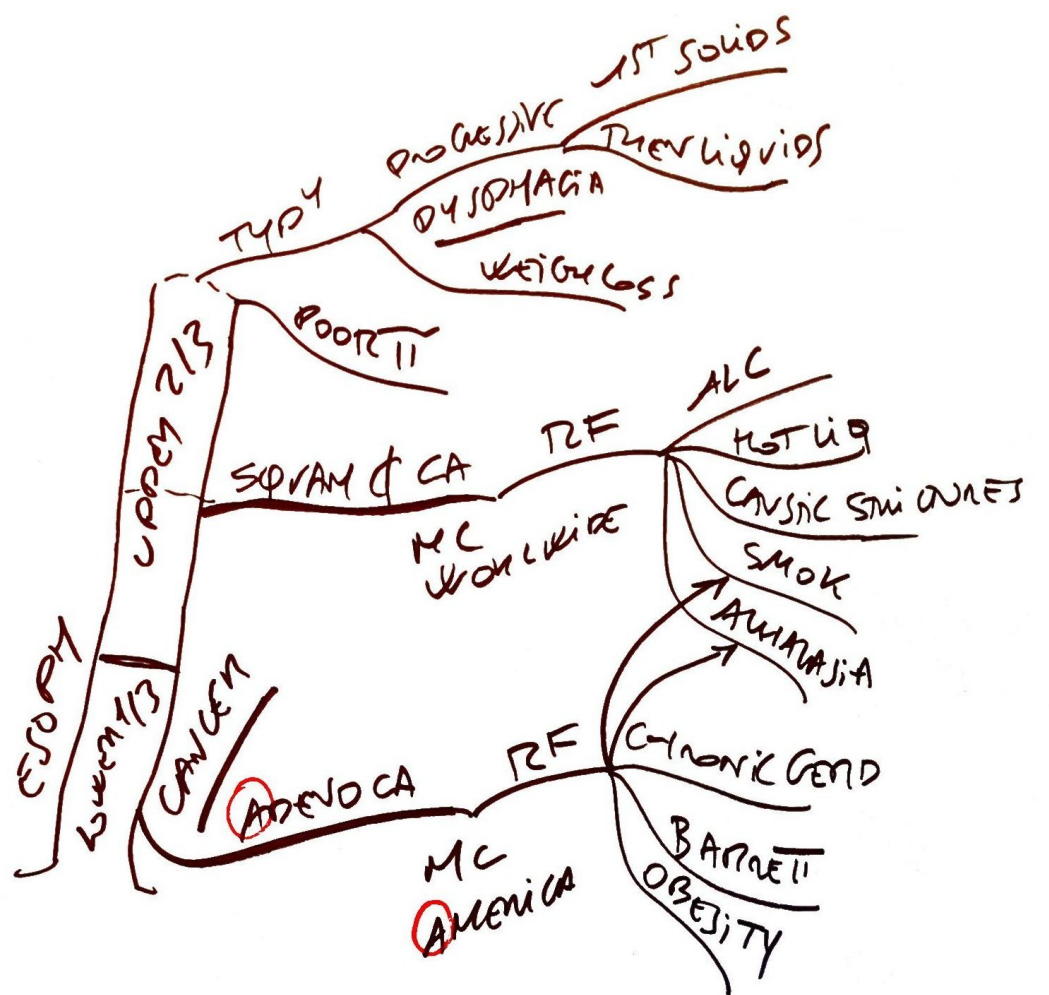IEC

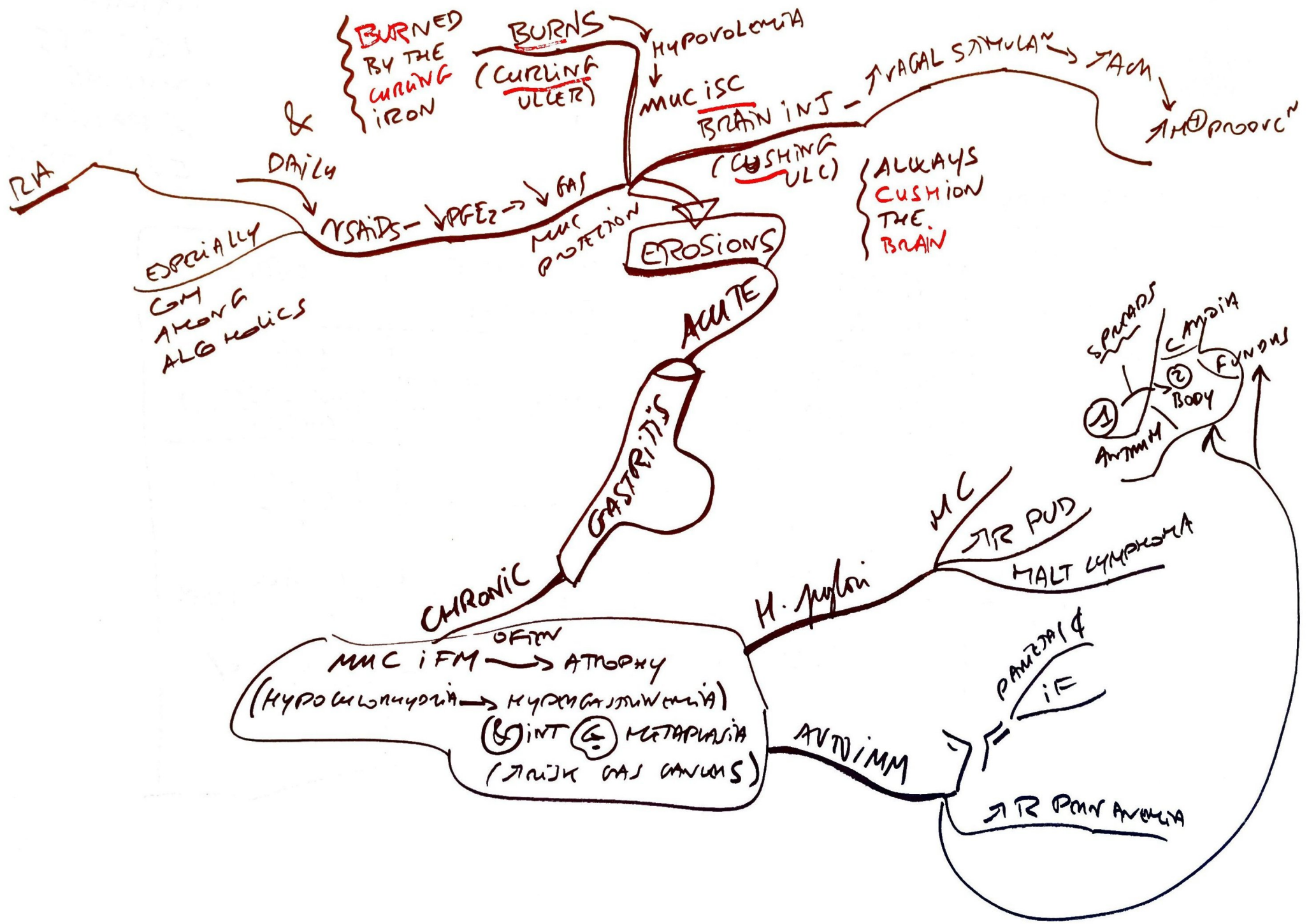
IMMUNOCOMP

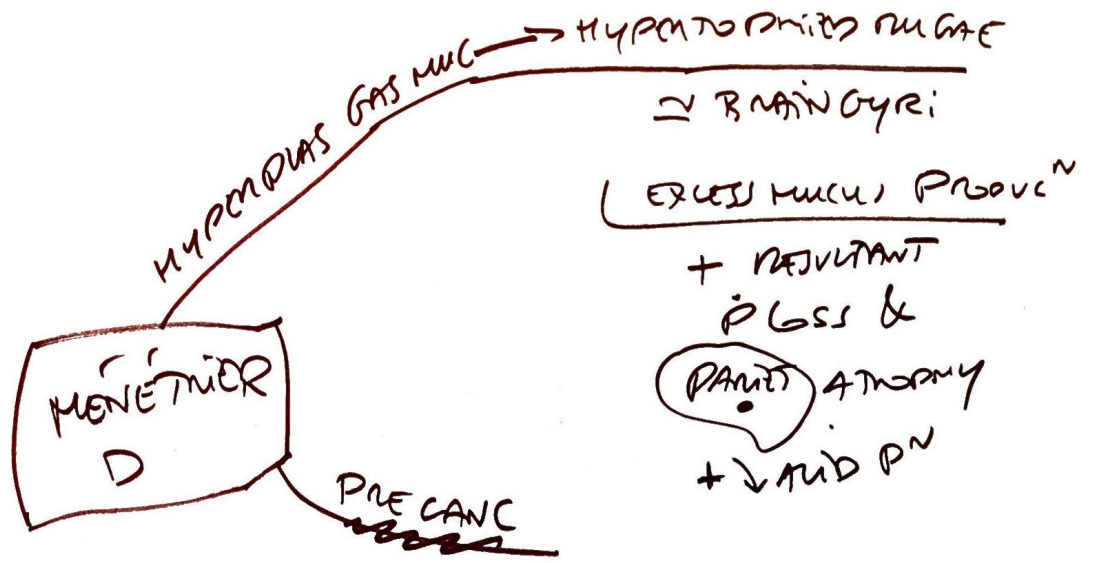
MAN

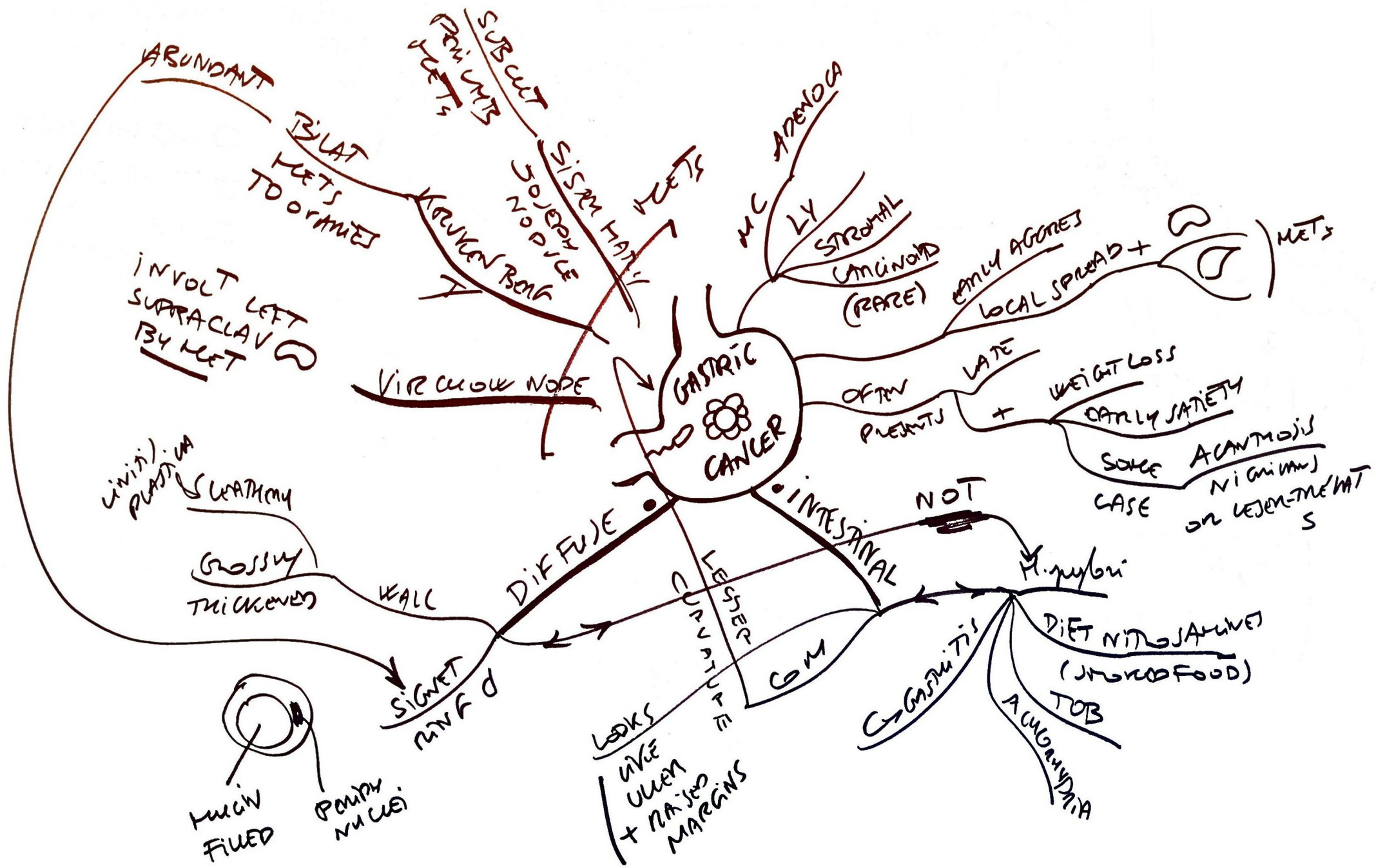
LIFE THREATENING  
HEMATEMESIS



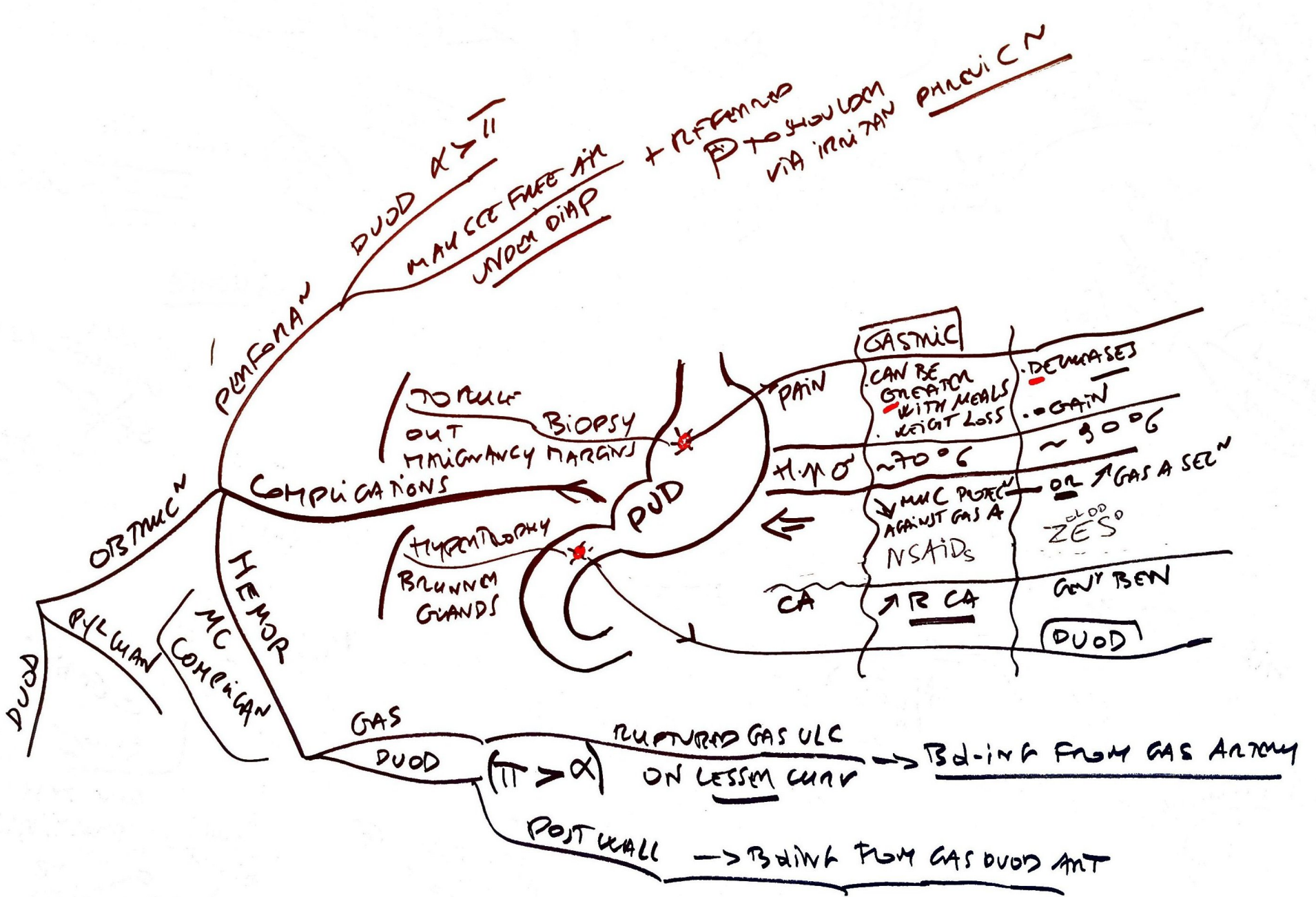


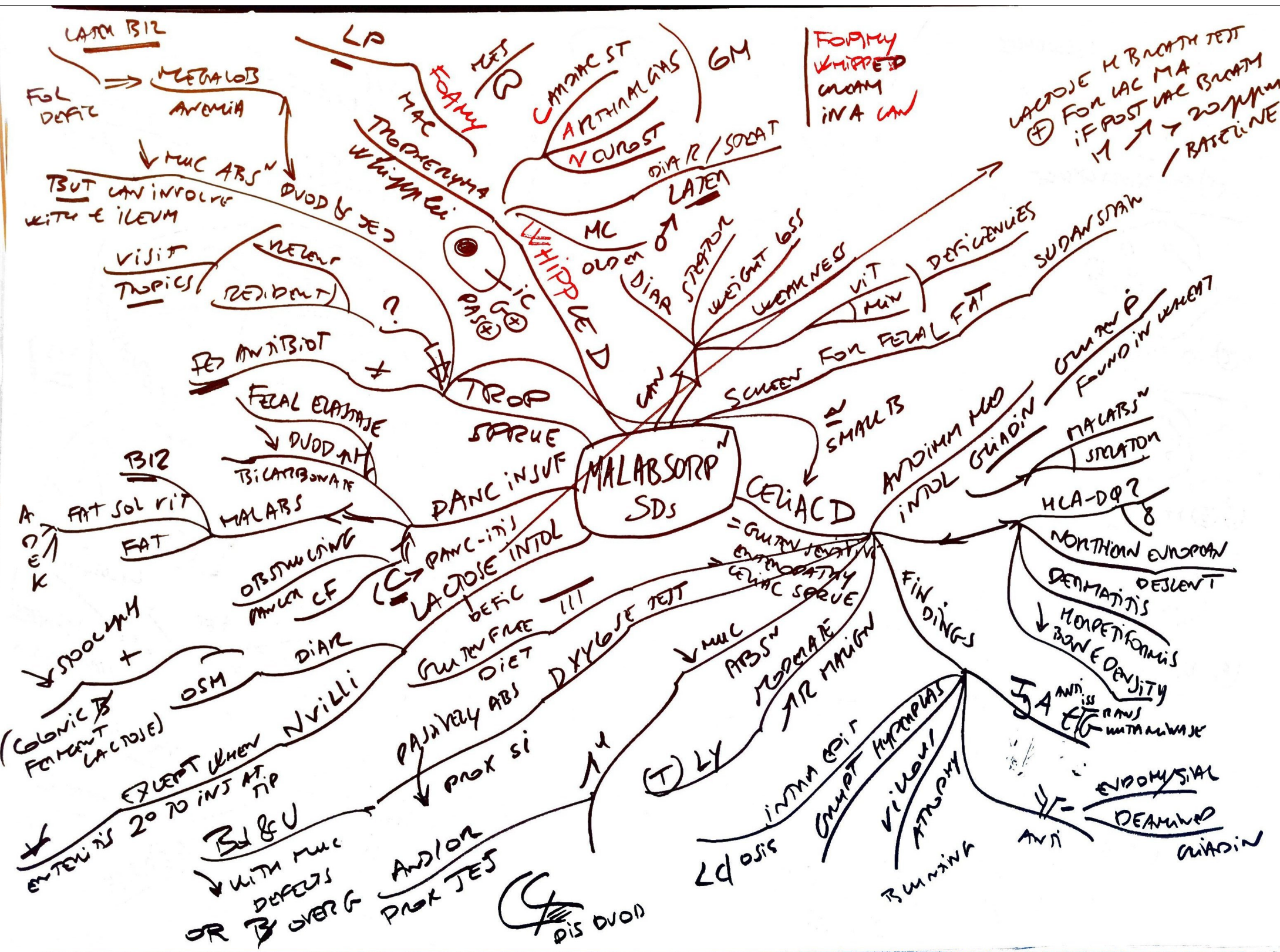












EXTRAIINT

- KIDNEY STONES (usually Ca oxalate)

- GALL STONES

- MAY BE ⊕ FOR ANTISACCHARINYLGLUCOSAMINASE

ASCA  
CS, AZAT, ANTI-SIOL, ANTI-CCP, ANTI-AMA, ANTI-LKM, ANTI-MITO

CROHN D

ANY PORTION USUALLY FROM ILEUM TO COLON

1/3 ILEUM "MOSE PIPE" ITI  
1/3 ONLY COLON  
MAINLY R USUALLY SPARES RECTUM BUT 3/4 OF ANUS

RASH (PYODERMIA EN)  
UPPER EYE LID  
ORAL ULCN  
EPIS  
VITILIGO

ULCERATIVE COLITIS

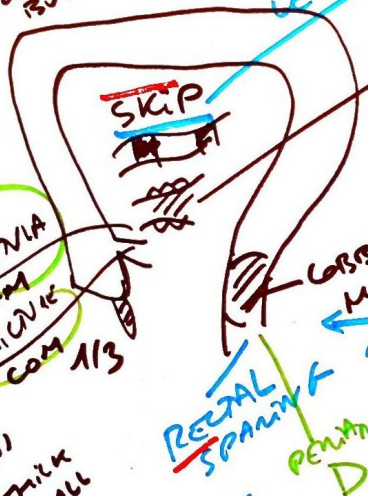
GEOMETRICAL ONLY

EXTRAIINT

5 AMINO PAPP METAMININ  
6 MERE INFIX COLITIS

ULCER  
LARGE INT  
CONTINUOUS  
COBRECT CA  
CRYPT  
EXTENSIVE PROX  
RED DIAR  
SLIMING (MUCUS)

FAT GRANNY & A MOLD  
CRONE SLIPPING DOWN A GORRIN  
ROAD ALONG FOR THE WEEK (ALL SPANNING)  
PHLEGM/ABS  
ENTMOVES  
OBSTINEN



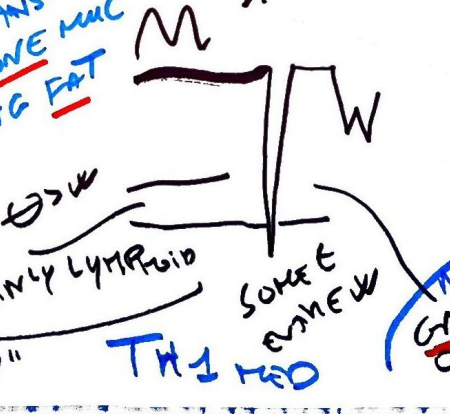
"FAT WRAPPING"  
MUC MALABSN  
MALNUTN CRC  
RECTAL SPANNING  
PENITRAL



CONTINUOUS  
ALWAYS RECTAL  
FUMINANT COLITIS  
TOX METAL  
PERFORAN

DIAR  
MAY OR MAY NOT BLOODY  
BRAIN XRAY

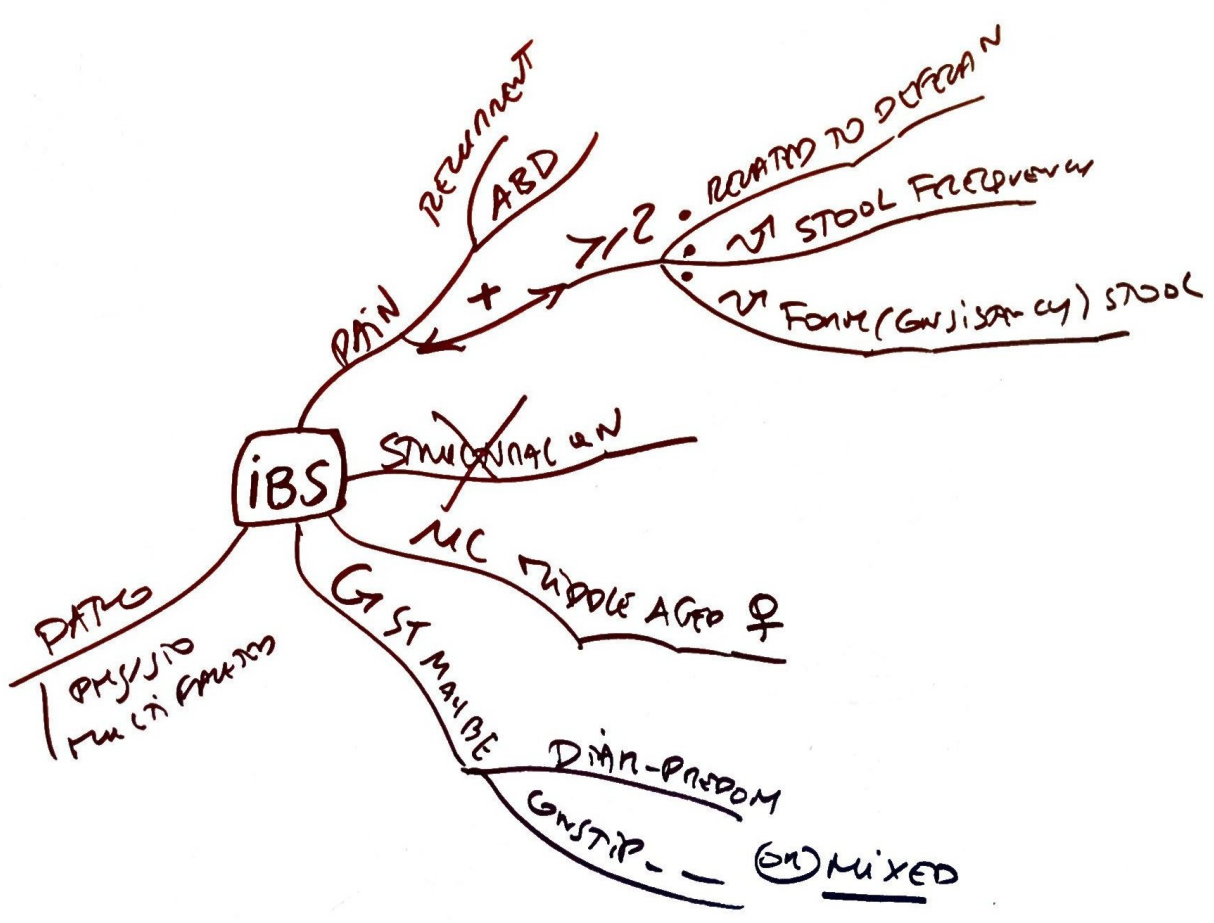
- FISURE  
- LIN ULC  
- WALL THICKENING  
- TRANSVERSE IFM → FISTULAS  
- COBBLESTONE MUC  
- CREEPING FAT

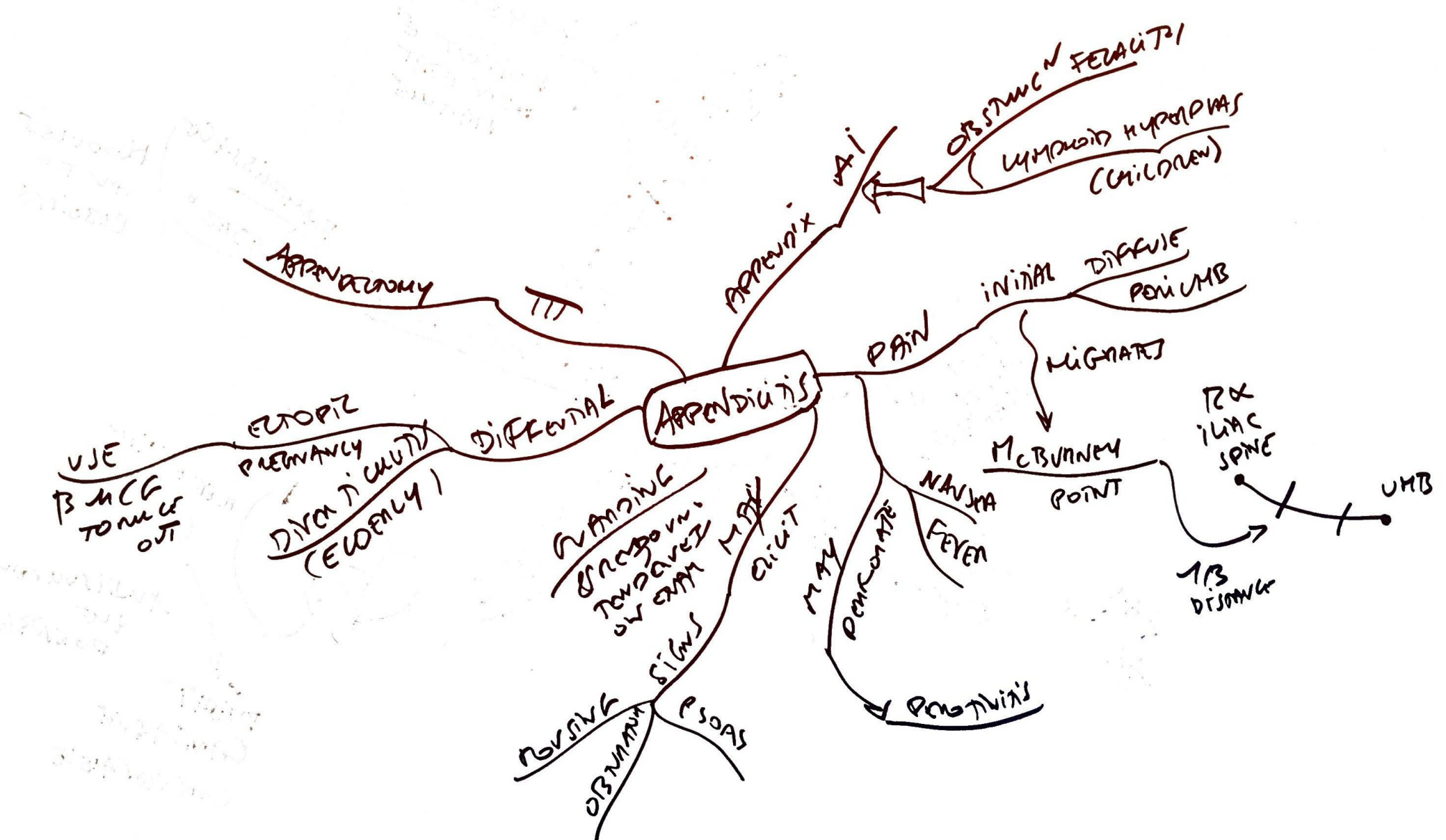


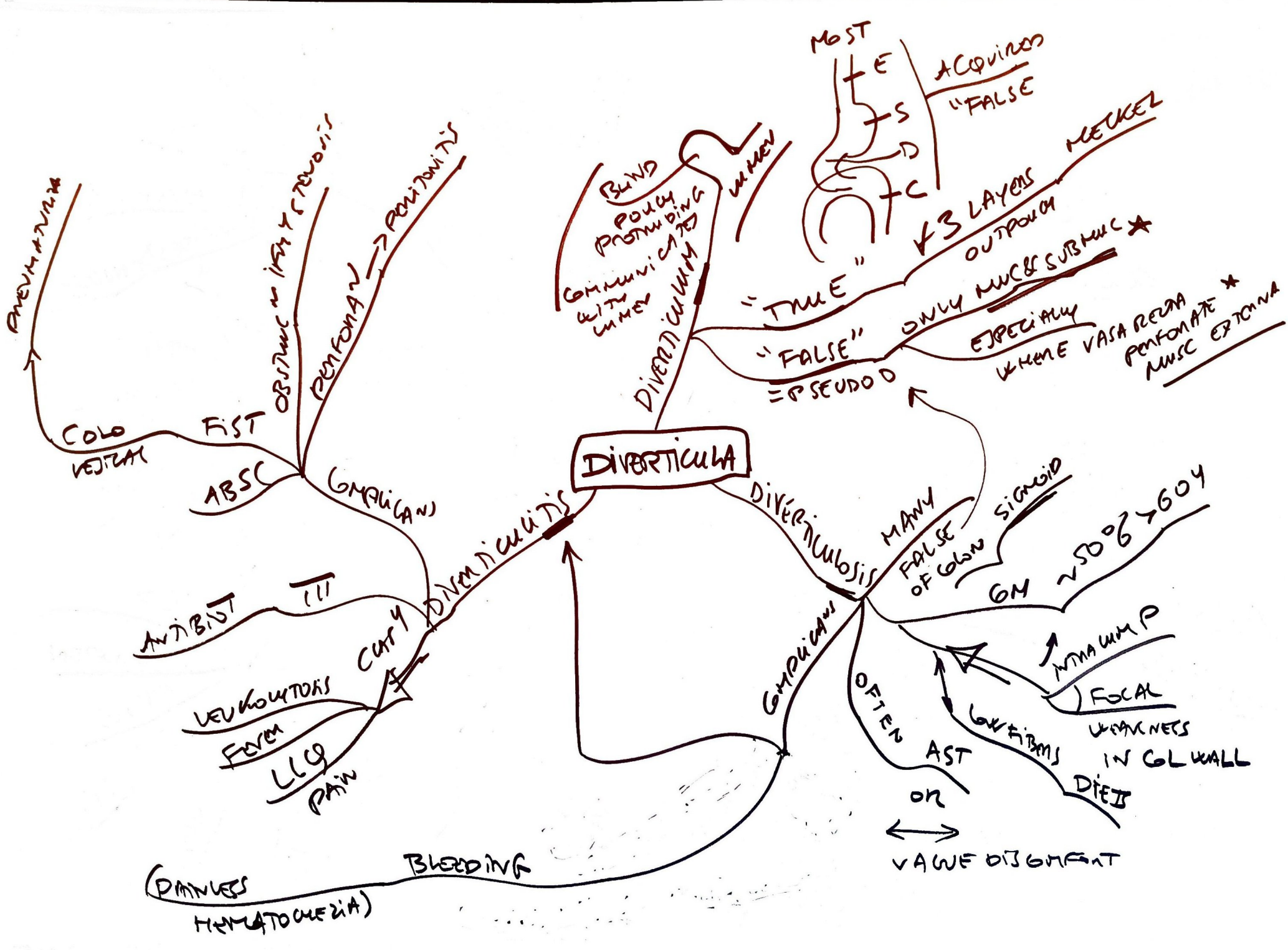
TH1 MED  
TH2  
MUC MIXED  
A&C  
CRYPT  
BRANING  
ABSUSSES  
GRAV  
OF LN + BOWEL

- MUC & SUBMUC IFM ONLY  
- FRIABLE MUC + AVOIDANCE  
- ULCUS  
- B&L MUCS  
- LOW MUCOSA → "MOSE PIPE"  
- WIDE SHALLOW ULC  
- ILM LYING TO MUC  
- CRYPTS ABS & ULC  
- B&LING  
- TH2

BLOODY DIAR

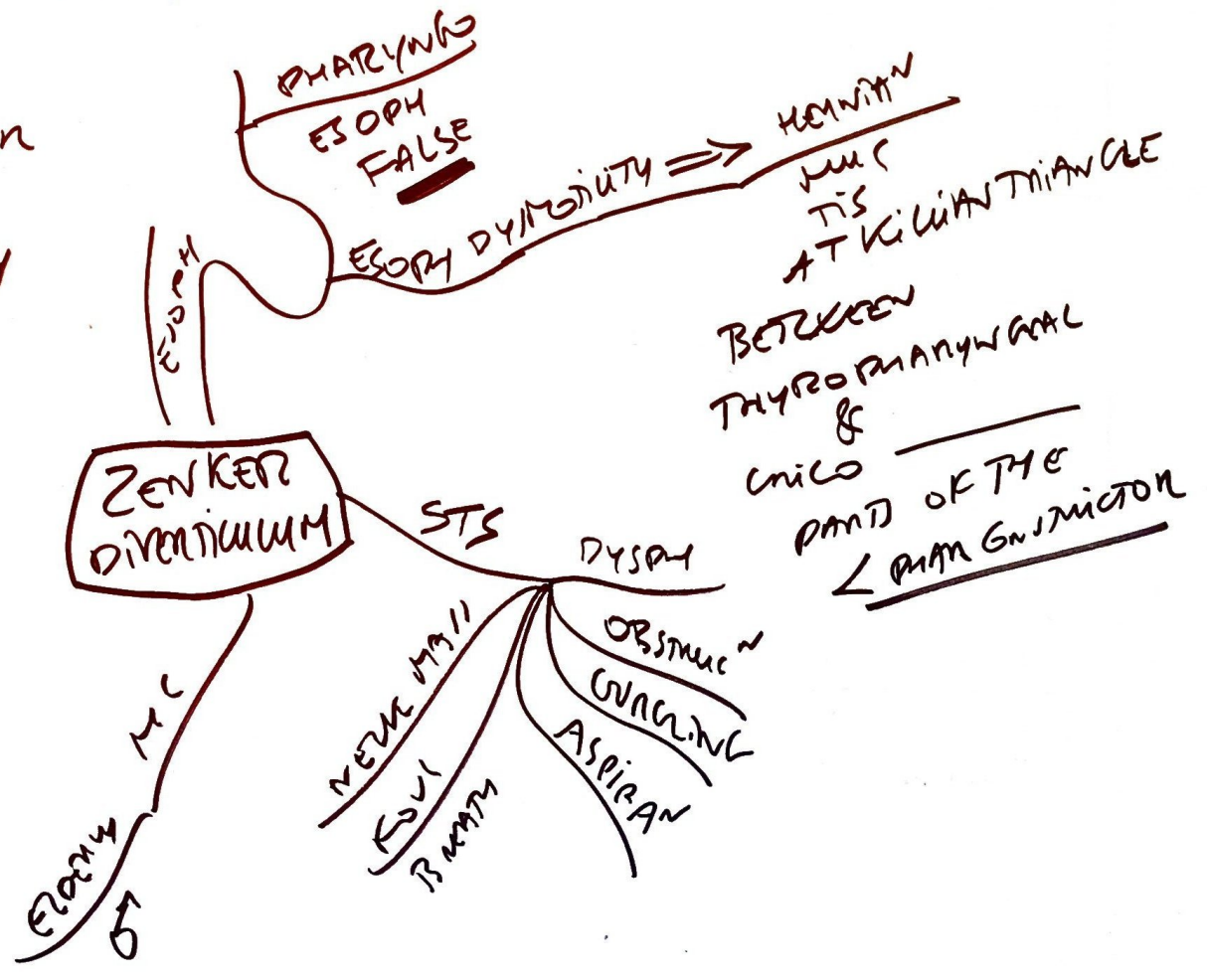






ELDERLY MALE HAS BAD BACATH

- ELDER
- MALES
- INFERIOR PHARYNGEAL OBSTRUCTION
- KILIAN TRIANGLE
- ESOPHAGEAL DYSMOTILITY
- HAIUTOSIS



**RULE 2**

- 2 TYPES AS VARIATION OF
- 2 INCHES LONG
- 2 FEET FROM IC VALVE
- 2% POPULATION

COMPLETELY 2 Y OF LIFE

MAY 2 TYPES EPIT GAS  
PANC

UMBILICAL

MEGACOLON

DIVERTICULUM

TRUE DIV

PERSISTENCE VITELLINE DUCT

MAY 2 ECTOPIC  
A SECONDING  
GAS MUC  
AND/OR PANC TIS

MC CONTRA GI

CAN HEMATOMA /  
MELIOMA (LESS COM)

RLC9 ID

INTUSSUSCEPTION

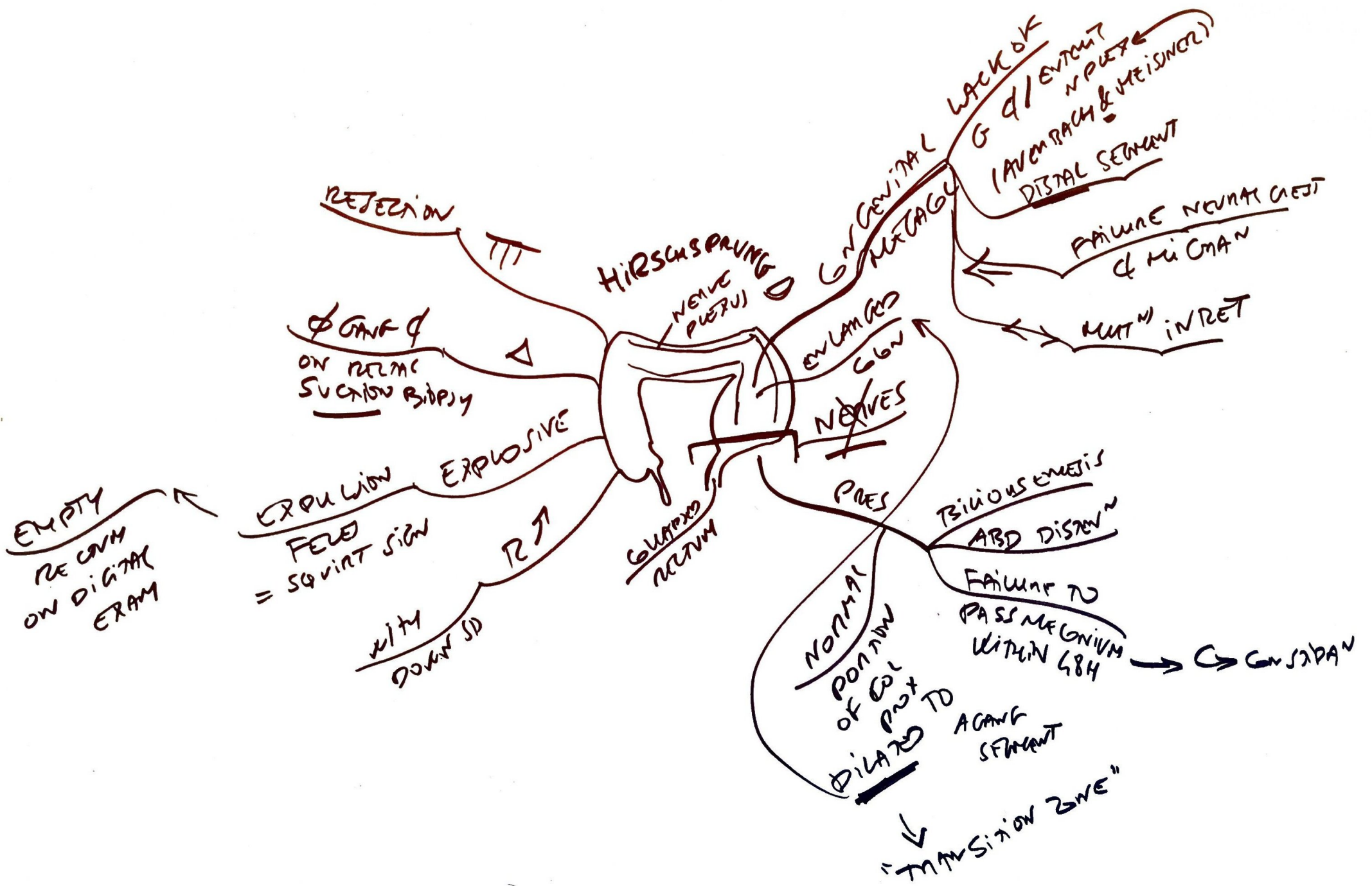
OBSTRUCTION NEAR ILEUM

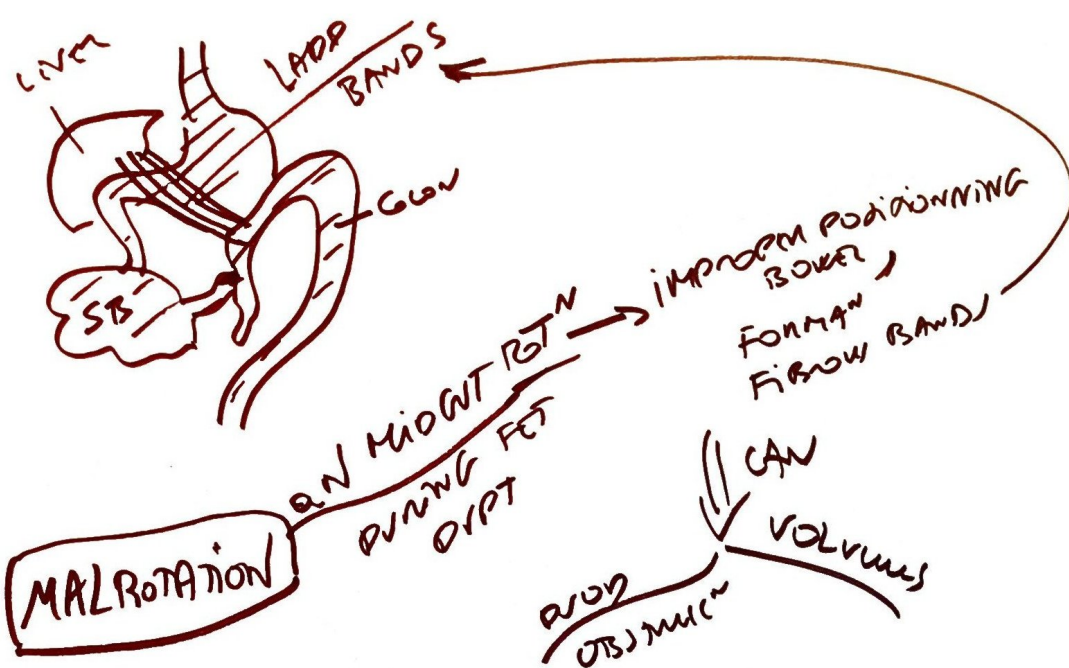
CONTRAST WITH

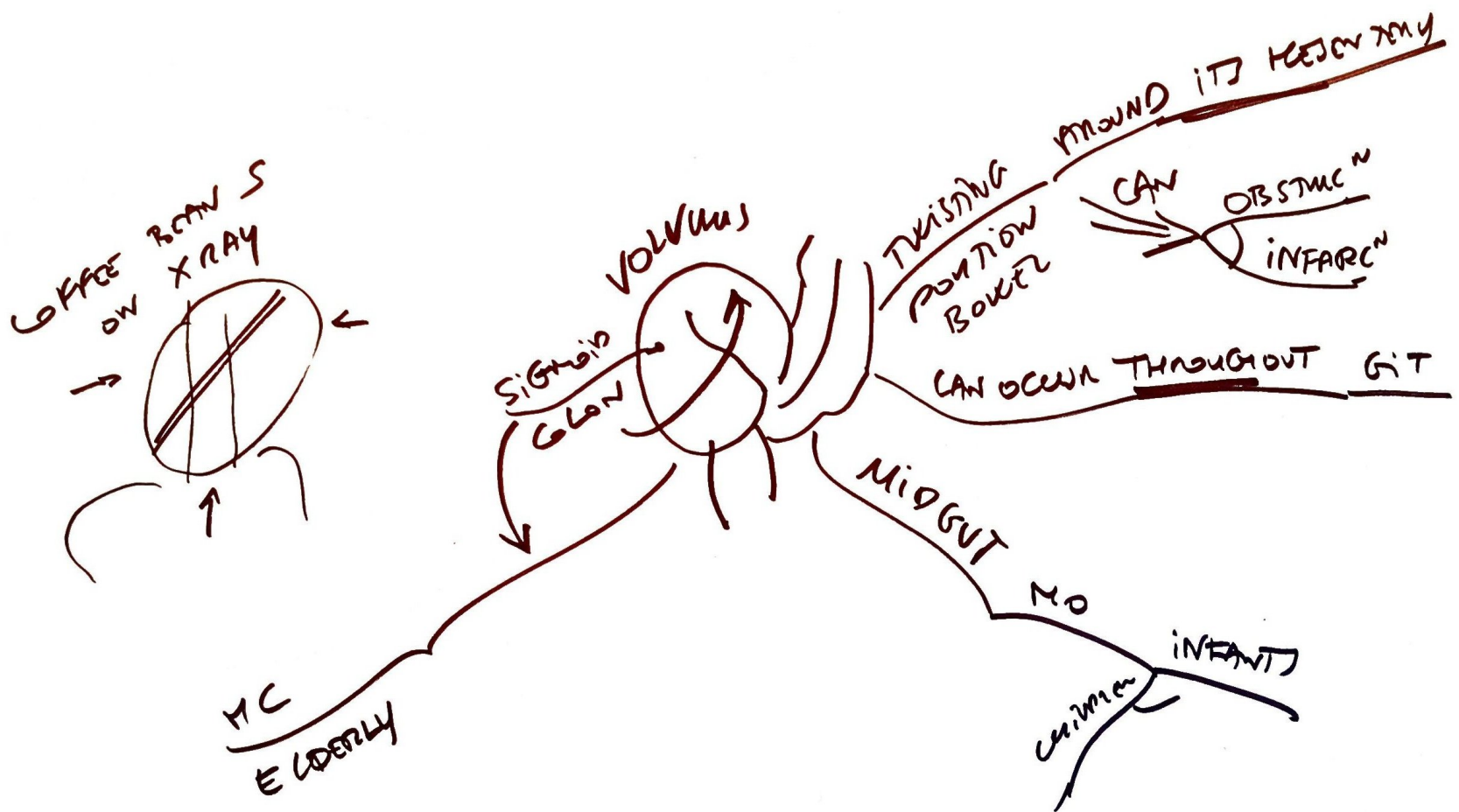
OMPHALOMESENTRIC CYST  
= CYSTIC DILATION  
OR WD

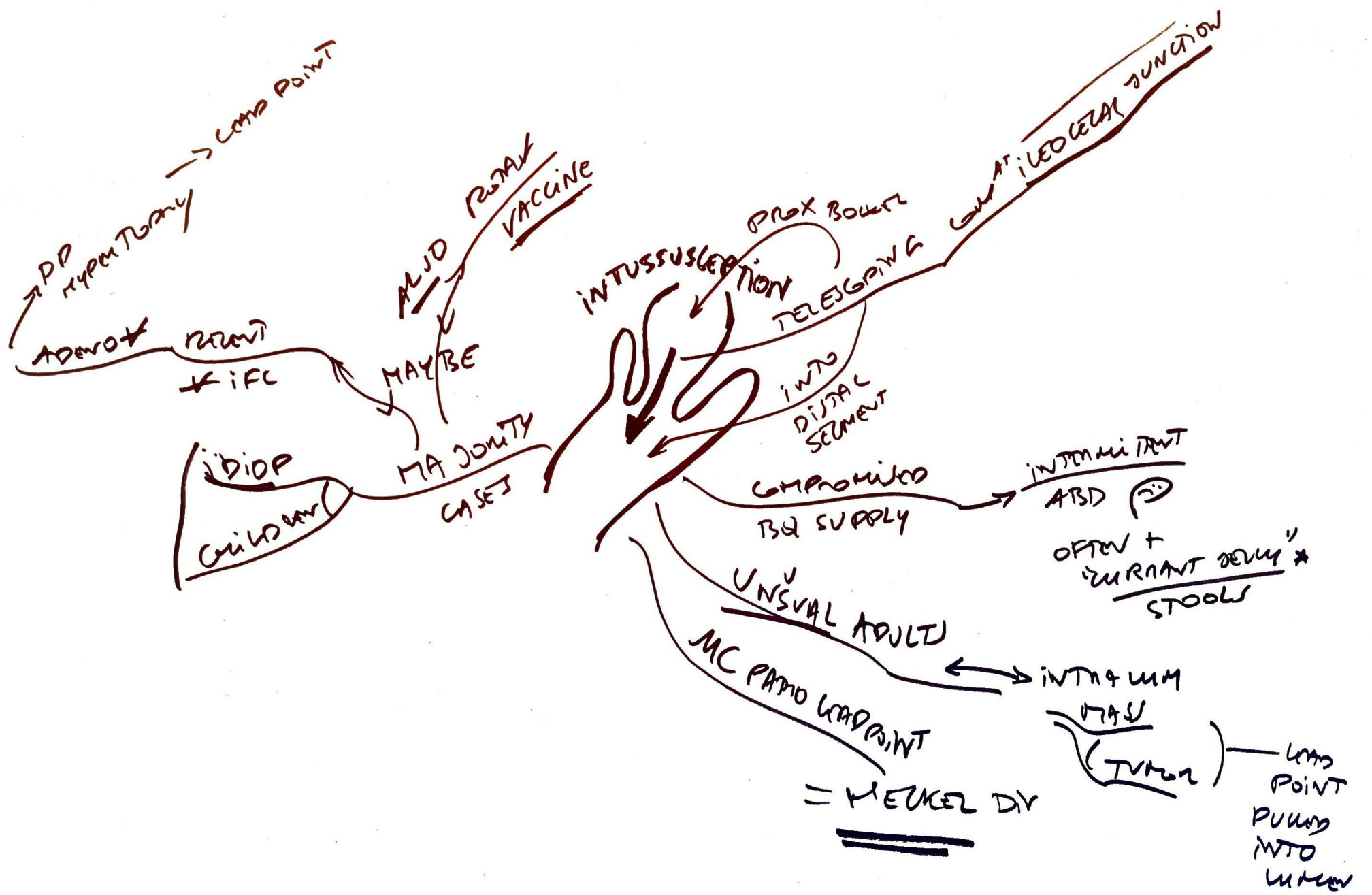
PERTEUNEATE  
STUDY FOR  
UPTAKE  
BY  
ECTOPIC GAS MUC

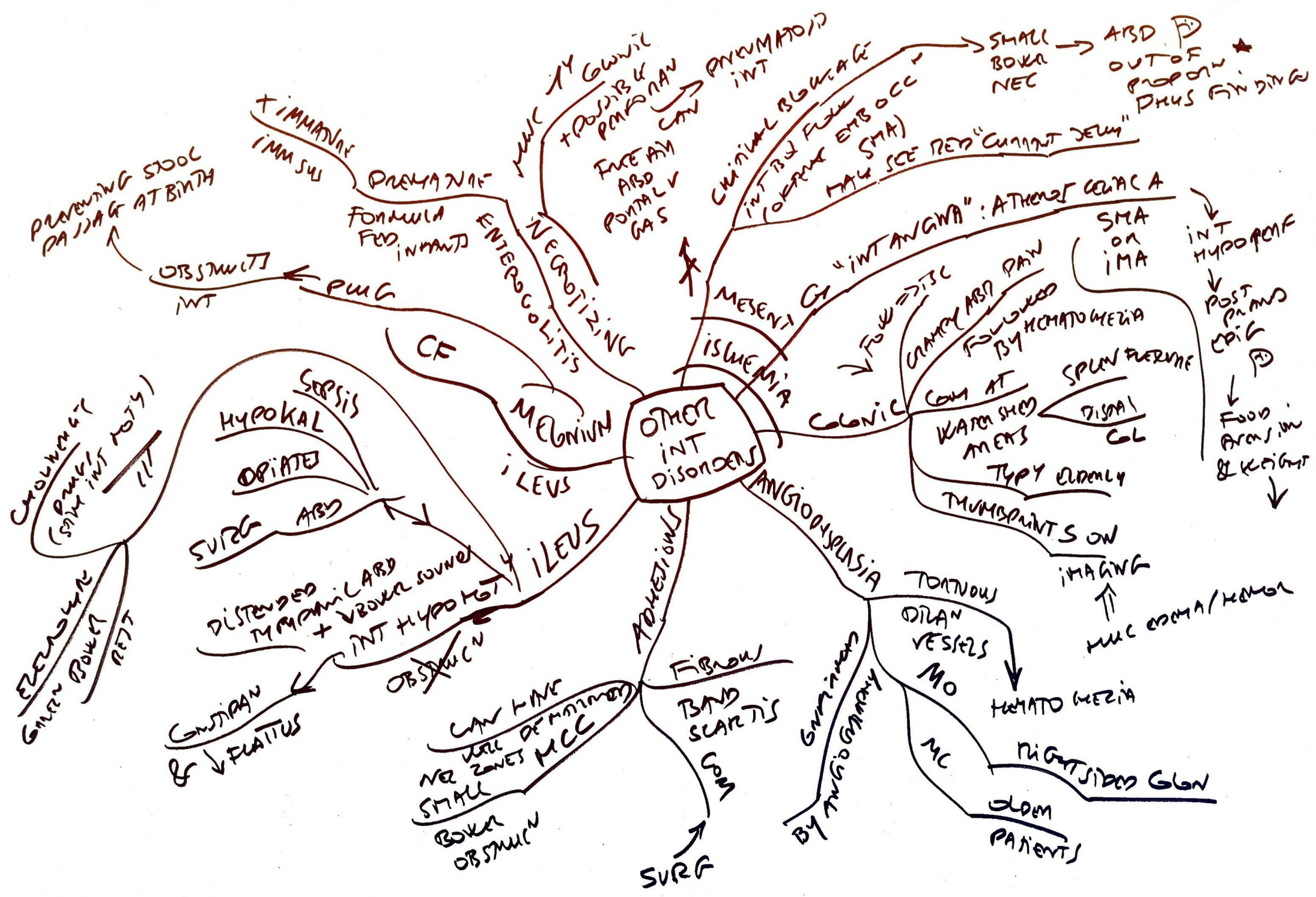


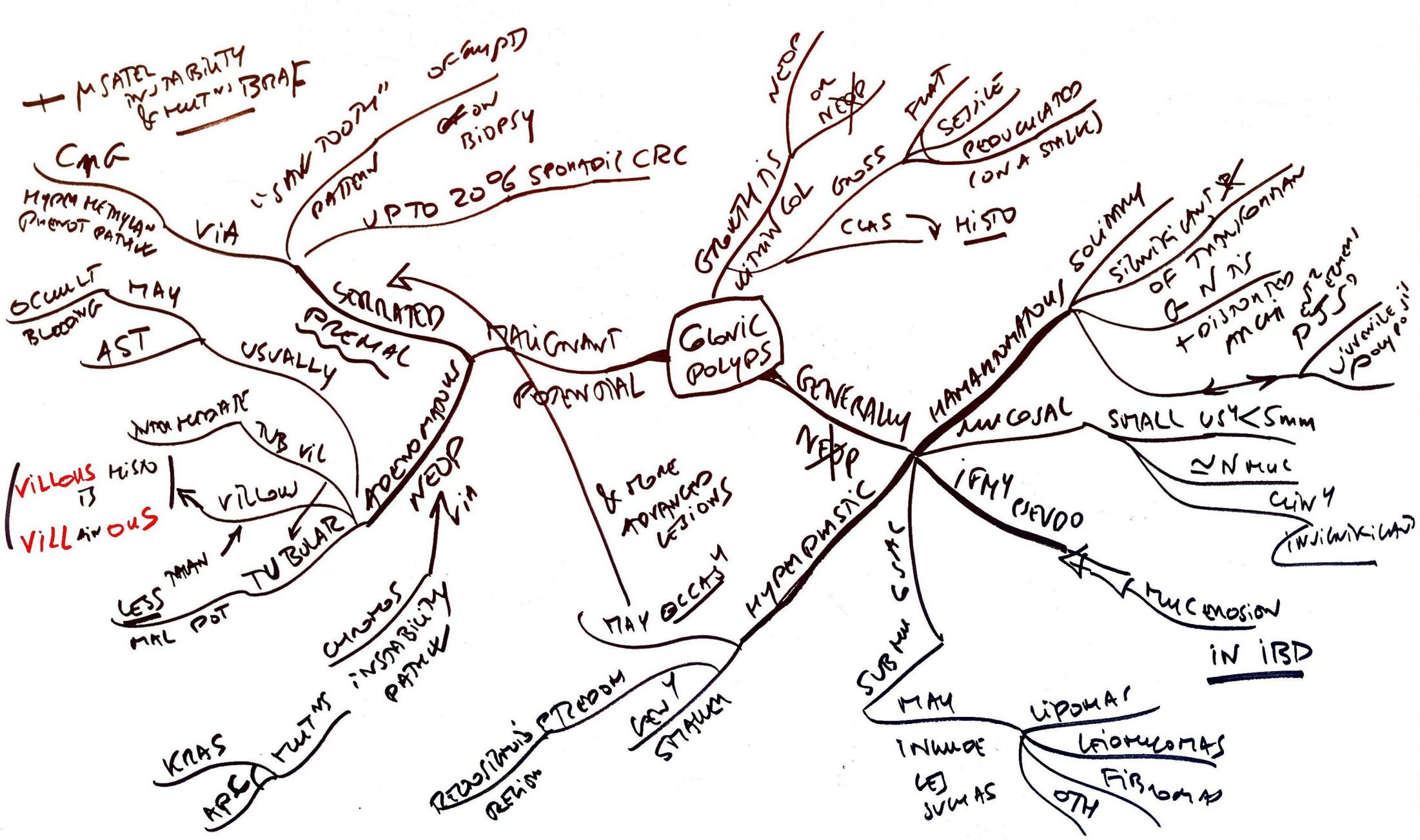




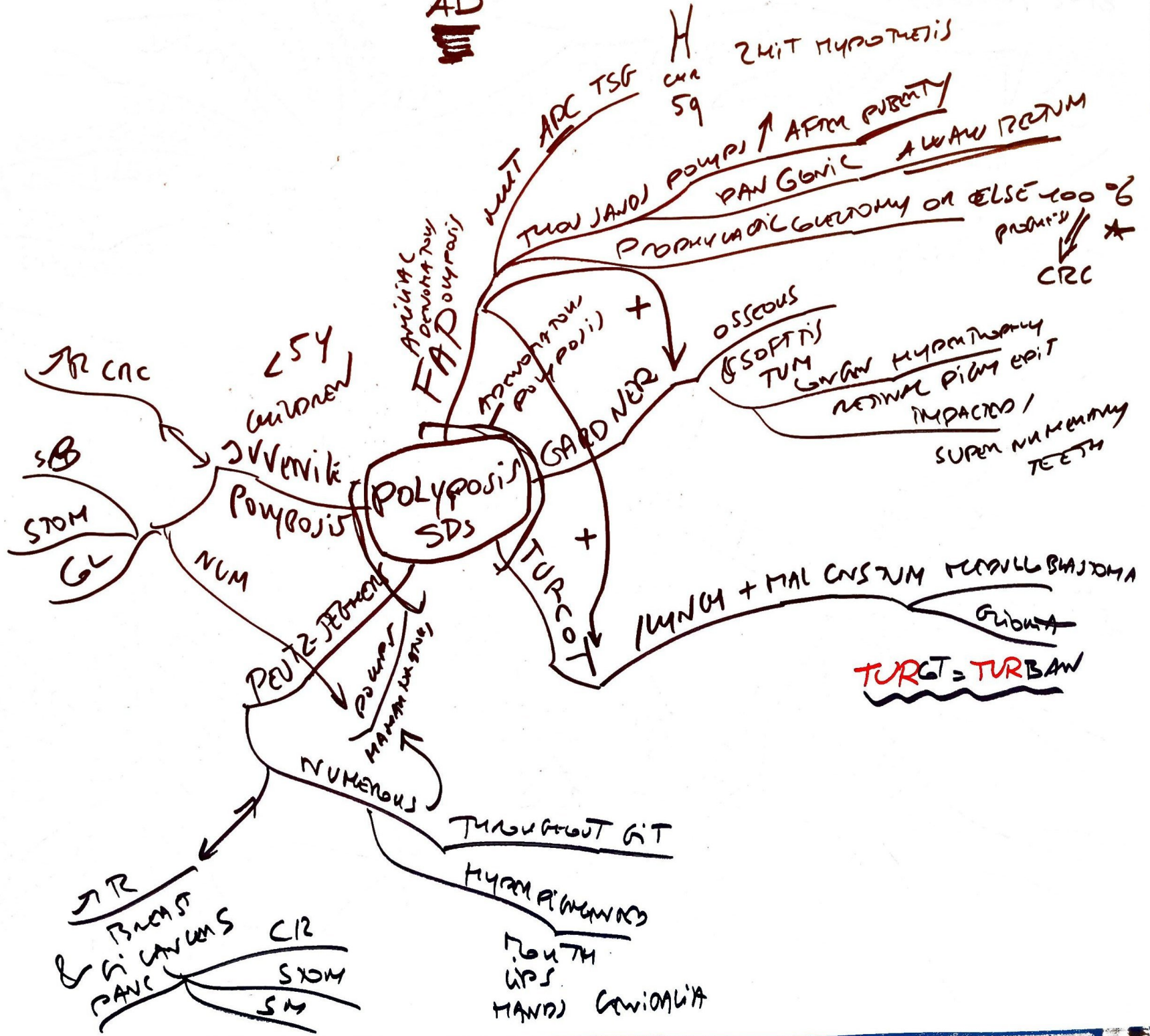








AD







Chromosomal instability pathway ← firing once events is AK-S3

