ANAL
RECTAL PROLAPSE
HAEMORRHOIDS
FISSURE IN ANO
FISTULA IN ANO
MANAGEMENT
CONSERVATIVE
MED
BULK LAXATIVES
ANOID
SMARTING
SPASM
ANAL SPHINCTER
PAIN ON DEFECATION
PASSAGE OF SLIPPERY STOOL
TRAUMA
TEAR CA
IF FAILS
LAT SUBCUT SPHINCTEROTOMY
INCISION TO DIVIDE & DILATE EXT SPHINC
GLYCERYL TRINITRATE GEL
TOP TOP DILATORS
ANAST
SURG
= RECTOPEXY
IE RETURN STITCHED TO SACRUM + RESECT SIGMOID
COMPLETE
FULL THICKNESS
PARTIAL
ONLY MUCOSA
EXCISION SURG
GAMS
MUCOUS ANOPLASTY
RUBBER LIGAN
PHENOL INJECTN
RF
PELVIC FLOOR DYSFN
INTRA ABDP PRESSURE
CHRONIC COUGH
CONST
DIAR
ES
IS
TIS LINES RETURN TAILS THROUGH ANUS
ACUTE THROMBOSIS IN SUPERF VEIN
EXTERNAL PILE
CHRONIC COUGH
CONSTIPATION
PREGNANCY
OBESITY
HEAVY LIFTING
RF
MAY BE AST
PAIN
BLEEDING
ITCHING
ENLARGED VASC CUSHIONS AROUND ANUS
4 DEGREES
INTERNAL 2&3
PROLAPSED
REDUCIBLE
ULCERATED
BLEEDING
PAINFUL
OCCASIONAL BRIGHT RED BLEEDING
LEAKAGE
PRURITIS
2 SPONT REDUCE
3 MANUAL
1 PROLAPSE BUT RETURN SPONT
2 PROL ON DEFECAN ON STRAINING
3 PROL CAN BE RED MANU
4 PERM PROL CANNOT BE RED
HAEMORRHOID ECTOMY
HARMONY LIGATION
MANAGEMENT
FIBRE
TOP UNGUENTS
RUBBER BAND LIGAN
SCLERO THERAPY
AN GANGRENOUS
BETWEEN AC & SKIN
GANGRENOUS PERIANAL ABS
PAIN
DISCHARGE
DEEP PERIANAL ABSCESS
SURGING
DEEP ANAL GLAND
INSERT GAD THROUGH FISTULA TRACK & THEY GRADUALLY TIGHTEN IT. THIS BRINGS GAD TO SFE & CUTS THROUGH TISSUES AS IT
CLASSIFIED
HIGH
LOW
OR
SETON STICH
DO THIS LATER IF SCAN
BEHIND IT KEEP SMALL SHUT TRACK
MANAGEMENT
SURG
INCISE FISTULA IE LAY IT OPEN
CROSS INTERNAL SPHINCTER OCCAS
CA
OR
CD
TIGHT ANUS → PAINFUL SEXUAL SKIN TAG
SPINE TEAR

NL

MOSIMAPS

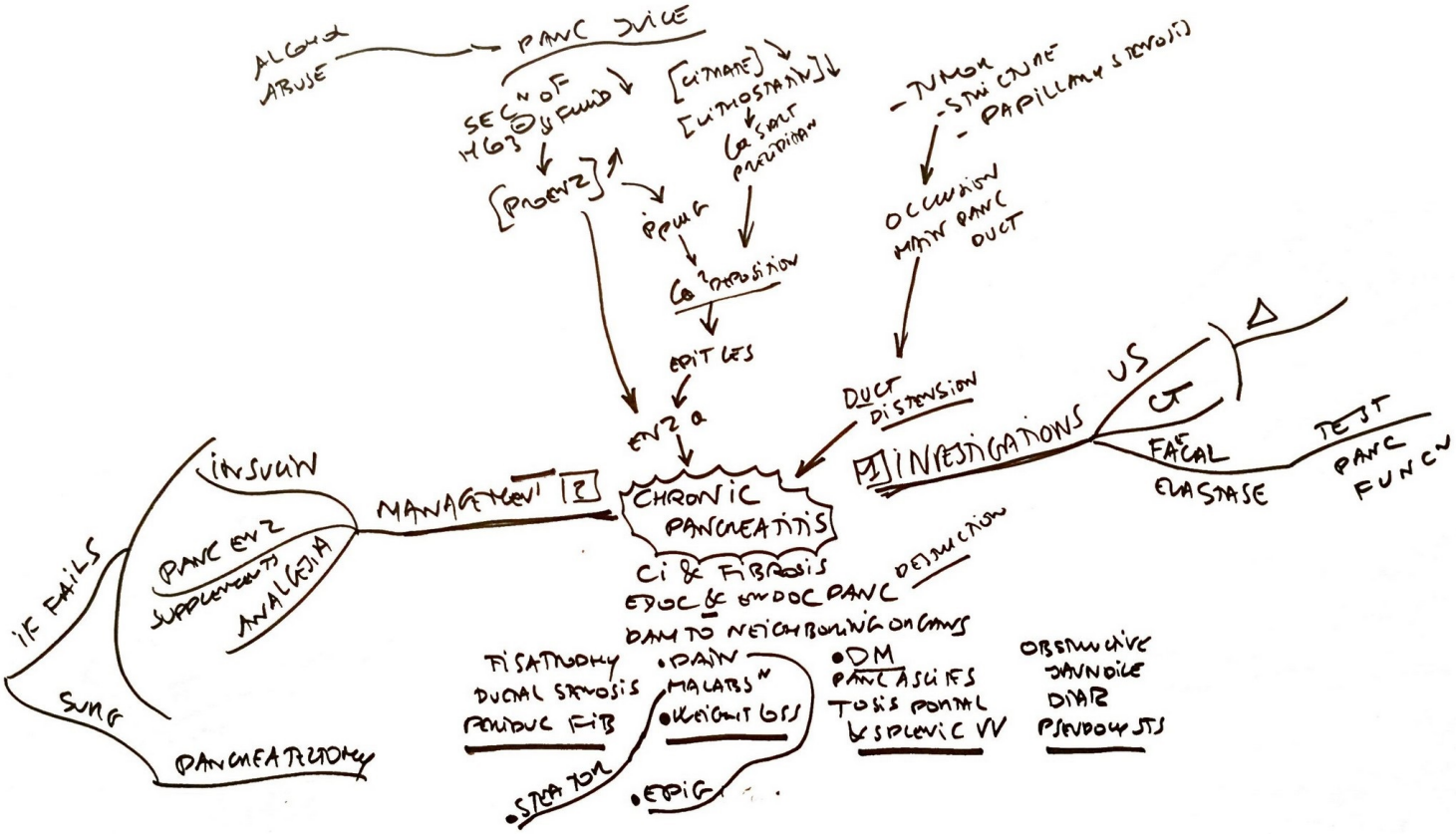
ALCOHOL ABUSE
PANC JUICE
SECN OF HCO3 & FLUID
[PROENZ]
[CITRATE]
[LITHOSTATIN]
Ca SALT PRECIPITATION
- TUMOR
- STRICTURE
- PAPILLARY STENOSIS
OCCLUSION MAIN PANC DUCT
PPUG
Ca PRECIPITATION
EPITHES
ENZ a
DUCT DISTENSION
CHRONIC PANCREATITIS
Ci & FIBROSIS
EXOC & ENDOC PANC
DAM TO NEIGHBOURING ORGANS
DESTRUCTION
MANAGEMENT
INSULIN
PANC ENZ
SUPPLEMENTS
ANALGESIA
IF FAILS
SURG
PANCREATECTOMY
INVESTIGATIONS
US
CT
FAECAL ELASTASE
TEST PANC FUNCN
FISTULOUS
DUCTAL STENOSIS
PERIDUC FIB
• PAIN
MALABSN
• WEIGHT LOSS
• STEATOR
• EPIG
• DM
PANC ASCITES
TOSIS PORTAL & SPLENIC VV
OBSTRUCTIVE JAUNDICE
DIAR
PSEUDOCYSTS

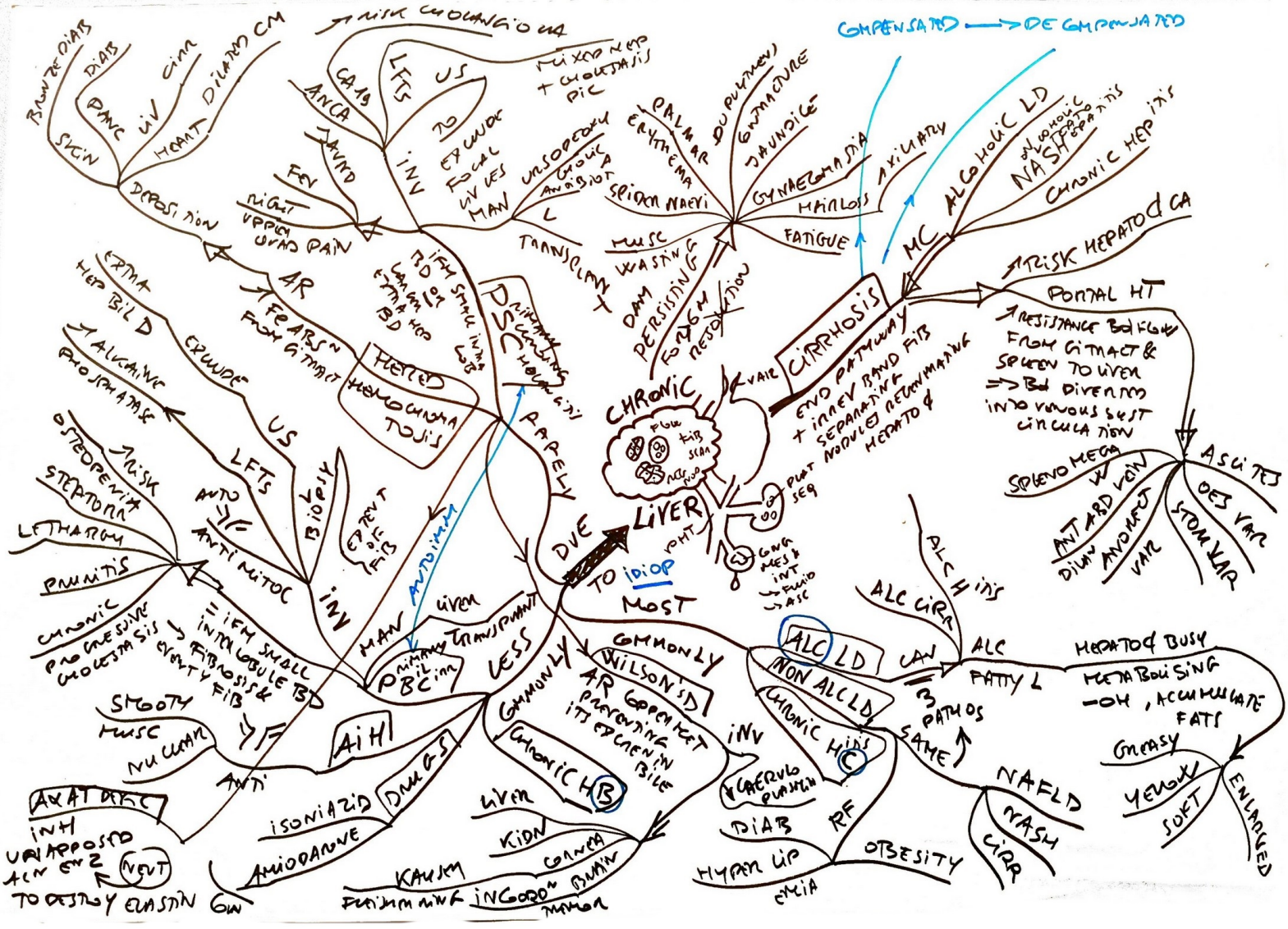
COMPENSATED → DECOMPENSATED
LIVER
CHRONIC
CIRRHOSIS
MC
ALCOHOLIC LD
NASH
CHRONIC HEP INJ
↑RISK HEPATOCA
PORTAL HT
↑RESISTANCE BLOOD FLOW FROM GI TRACT & SPLEEN TO LIVER
=> BLOOD DIVERTS INTO VENOUS SYST CIRCULATION
ASCITES
SPLENOMEGA
ANT ABD VEIN
DILAT
ANORECT VAR
VAR
STOM VAR
OES VAR
ALC HINJ
ALC CIRR
ALC
FATTY L
HEPATOCY BUSY
METABOLISING -OH, ACCUMULATE FATS
GREASY
YELLOW
SOFT
ENLARGED
NAFLD
NASH
CIRR
OBESITY
RF
DIAB
HYPERLIPIDAEMIA
CAERULOPLASMIN
CHRONIC HCV
SAME
3 PATHOS
ALC LD
NON ALC LD
CAN
MOST COMMONLY
DUE TO IDIOP
PRIMARY
SECONDARY
PRIMARY SCLEROSING CHOLANGITIS
↑RISK CHOLANGIOCA
MIXED HEP + CHOLESTASIS PIC
LFTS
US
ANCA
ANA
TO EXCLUDE FOCAL LIVER LES
MAN
INV
JAUNDICE
FEV
RIGHT UPPER QUAD PAIN
DEPOSITION
SKIN
DIAB
DMC
LIV CIRR
HEART
DILATED CM
BRONZE DIAB
PALMAR ERYTHEMA
DUPUYTREN'S CONTRACTURE
JAUNDICE
GYNAECOMASTIA
HAIRLOSS
AXILLARY
FATIGUE
SPIDER NAEVI
MUSC WASTING
DIAM PERSISTING
FORTUITOUS RESOLUTION
TRANSPLANT
CHRONIC ANALGESIC
↑RISK HEPATOCA
↑FEARS IN FROM GI TRACT
HEPATO BILD
ERYTHA
ALKALINE PHOSPHATASE
EXCLUDE
US
LFTS
OSTEOPENIA
↑RISK STEATORRH
LETHARGY
PRURITIS
CHRONIC PROGRESSIVE CHOLESTASIS
ANTI MITOC
ANTI
BIOPSY
INV
MAN
LIVER
TRANSPLANT
PBC
VESS
COMMONLY
WILSON'S D
AR COPPER PARENCHYMA ITS EXCRETION BILE
CHRONIC HB
LIVER
KIDN
CORNEA
BRAIN
KAUSM
FRIEDMANN
INGORDON
MARROW
SMOOTH MUSC
NUCLEAR
AIH
DRUGS
ISONIAZID
AMIODARONE
ANTI
AXAT DEFIC
INH
UNAPPOSED ACTIVE ENZ
TO DESTROY ELASTIN
GW
ALC HEPATITIS
ALC CIRR
CAN
SAME
PRIMARY BILIARY CIRR
IFM SMALL INTRAHEPATIC BD
FIBROSIS & CONTY FIB
EPTENT OF FIB
ANTIBIOTICS
IFM SMALL INTRAHEPATIC BD
CANCER HEP
EXTRA HEP BD
RIGHT UPPER QUAD PAIN
HEPATO CHOLANGIO
HEPATO CHOLANGIO
HEPATO CHOLANGIO
FIBRO
CT
MRI
PET
PLUS
FIB SCAN
NEC FUNC
PLAT SEQ
GENE MES & INT → FUNCTIONAL ASC
VARIC
ENDO PATHWAY
+ INNER BAND FIB
SEPARATING NODULES RETURNING HEPATO ↑

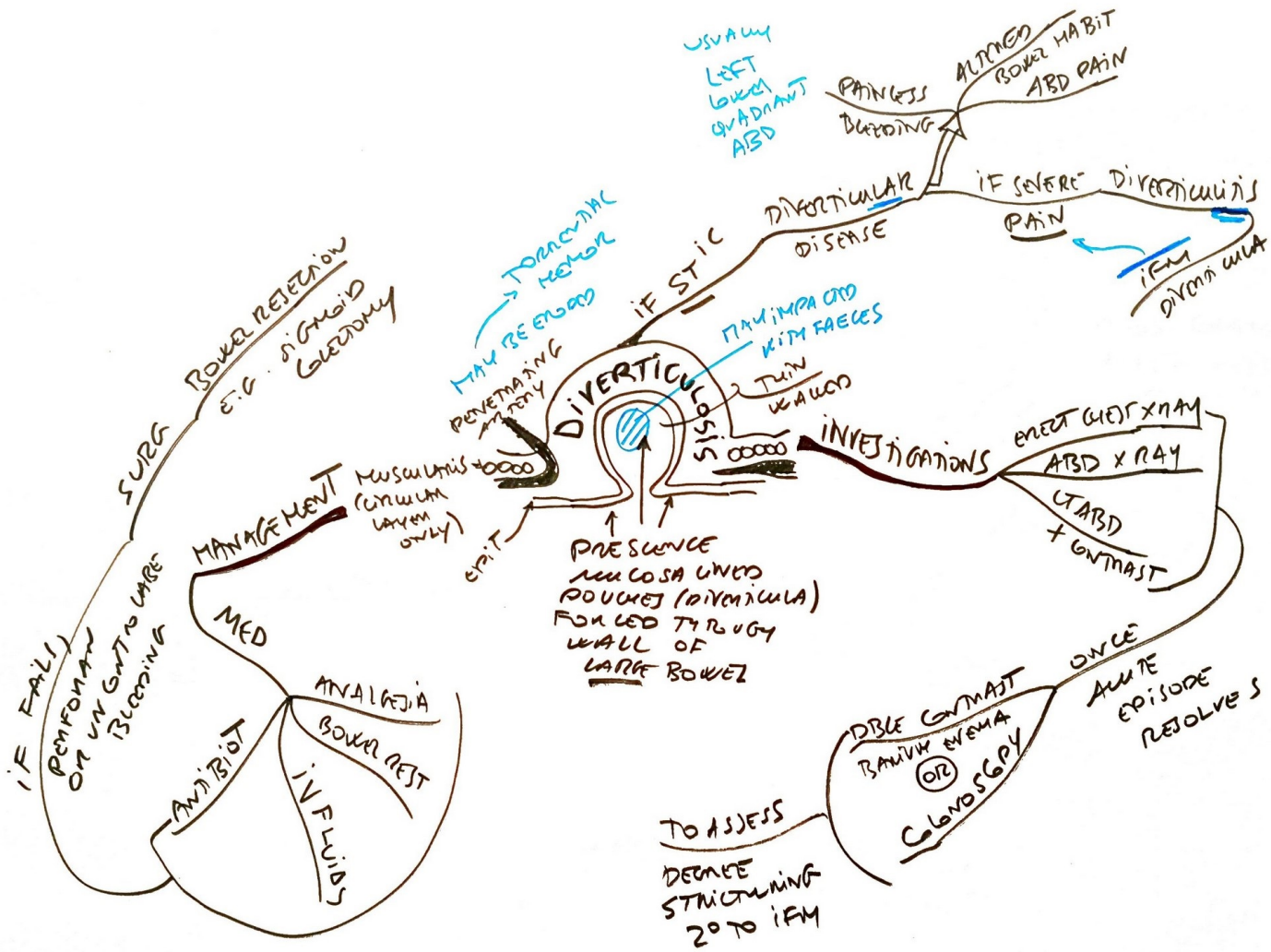
DIVERTICULOSIS
PRESENCE MUCOSA LINED POUCHES (DIVERTICULA) FORCED THROUGH WALL OF LARGE BOWEL
EPIT
MUSCULARIS (CIRCULAR LAYER ONLY)
PENETRATING ARTERY
MAY BE ENLARGED
TORRENTIAL HEMOR
MAY IMPACTED WITH FAECES
THIN WEAKED
IF STIC
DIVERTICULAR DISEASE
PAINLESS BLEEDING
ALTERED BOWEL HABIT
ABD PAIN
IF SEVERE PAIN
DIVERTICULITIS
IFM
DIVERTICULA
USUALLY LEFT LOWER QUADRANT ABD
INVESTIGATIONS
ERECT CHEST XRAY
ABD X RAY
CT ABD + CONTRAST
ONCE ACUTE EPISODE RESOLVES
DBLE CONTRAST BARIUM ENEMA
OR
COLONOSCOPY
TO ASSESS DEGREE STRICTURING 2° TO IFM
MANAGEMENT
MED
ANALGESIA
BOWEL REST
IV FLUIDS
ANTIBIOT
SURG
BOWEL RESECTION
E.G. SIGMOID COLECTOMY
IF FAILS
PERFORATION OR UNCONTROLLABLE BLEEDING

NL

MEDIMAPS

STARTS MID ABD THEN LOCALISES TO RE ILIAC FOSSA WITHIN A FEW HRS
NAUSEA
VOMITING
FEVER
PAIN
MAY EXHIBIT SIGNS
PAIN ON FLEXION OR ROTATION AT HIP INTERNAL
OBTURATOR (GOPE)
PSOAS
ON FLEXING HIP OR EXTENDING
ROVSING
IN RT ILIAC FOSSA ON DEEP PALPATION OF LEFT
MC BURNEY AT 1/3 DISTANCE FROM RT ASIS TO UMBILICUS
INFLAMMATION ILIOPSOAS MUSC
INFLAMMATION OBTURATOR INTERNUS MUSC
MOST COMMON SURG EMERG
OBSTRUCTION
FAECALITH
ACUTE APPENDICITIS
PERFORATED
GENERALIZED PERITONITIS
ABSCESS
COMPLICATIONS 3
RUPTURE
SEVERE PERITONITIS
1 INVESTIGATIONS
FBC
CRP
PREGNANCY TEST
URINE DIPSTICK
ABD CT
US
2 MANAGEMENT
INITIALLY
NBM
0.9% SALINE IV
MORPHINE IV
ANTIBIOT
THEN
SURG
LAPAROSCOPICALLY
OR
LAPAROTOMY
SEE
APPENDICECTOMY PERFORMED
1 INCISION JUST BELOW MC BURNY'S POINT
2 CUT OPEN ABD MUSCS
3 OPEN PERIT
4 APP & CAEC THROUGH
5 BOTH VES & MES
DIVIDED
APP LIGATED, REMOVED AT BASE & RETURNED
NL
MEDIMAPS

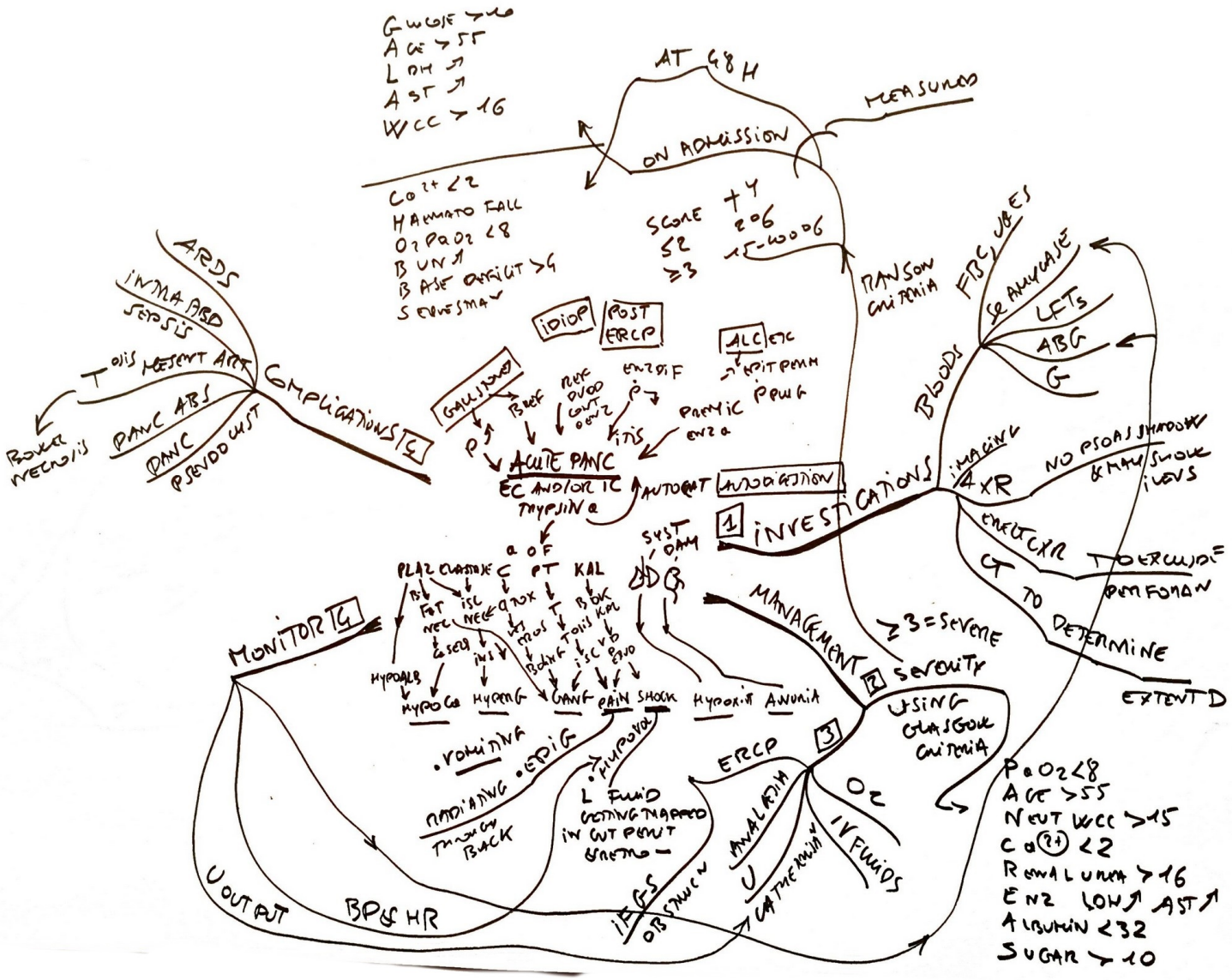
Glucose >10
Age >55
LDH ↗
AST ↗
WCC >16
AT 48 H
MEASURES
ON ADMISSION
Ca 2+ <2
HAEMATOCRIT FALL
O2 PaO2 <8
BUN ↗
BASE DEFICIT >4
SERUM Na ↘
SCORE +4
52
≥3
TRANSON CRITERIA
IDIOP
POST ERCP
ALC etc
GALLSTONES
ENZYME
ACUTE PANC
EC AND/OR IC
TRYPSIN
AUTOINJ
AUTODIGESTION
ARDS
INTRA ABD SEPSIS
T OIS
MESENT ART
PANC ABS
PANC PSEUDOCYST
COMPLICATIONS 4
BOWEL NECROSIS
BLOODS
FBC, U&Es
Ca ALBUMASE
LFTs
ABG
G
INVESTIGATIONS 1
IMAGING
CXR
NO PSOAS SHADOW
CHEST CXR
TOERCUDIS
PERFORAN
CT TO DETERMINE
EXTENT D
MANAGEMENT 2
≥3 = SEVERE
SEVERITY
USING GLASGOW CRITERIA
MONITOR 4
HYPOALB
HYPOCa
HYPOMG
GANG
PAIN
SHOCK
HYPOXIA
ANUREA
ROUTINE
EPIG
RADIATING THROUGH BACK
L FLUID GETTING TRAPPED IN OUT PENUT GASTRO
HYPOTENS
ERCP 3
ANALGESIA
O2
IV FLUIDS
CATHETERIZE
OBSTRUCTN
U OUTPUT
BP & HR
PaO2<8
Age >55
Neut WCC >15
Ca 2+ <2
Renal urea >16
Enz LDH ↗ AST ↗
Albumin <32
Sugar >10

NL

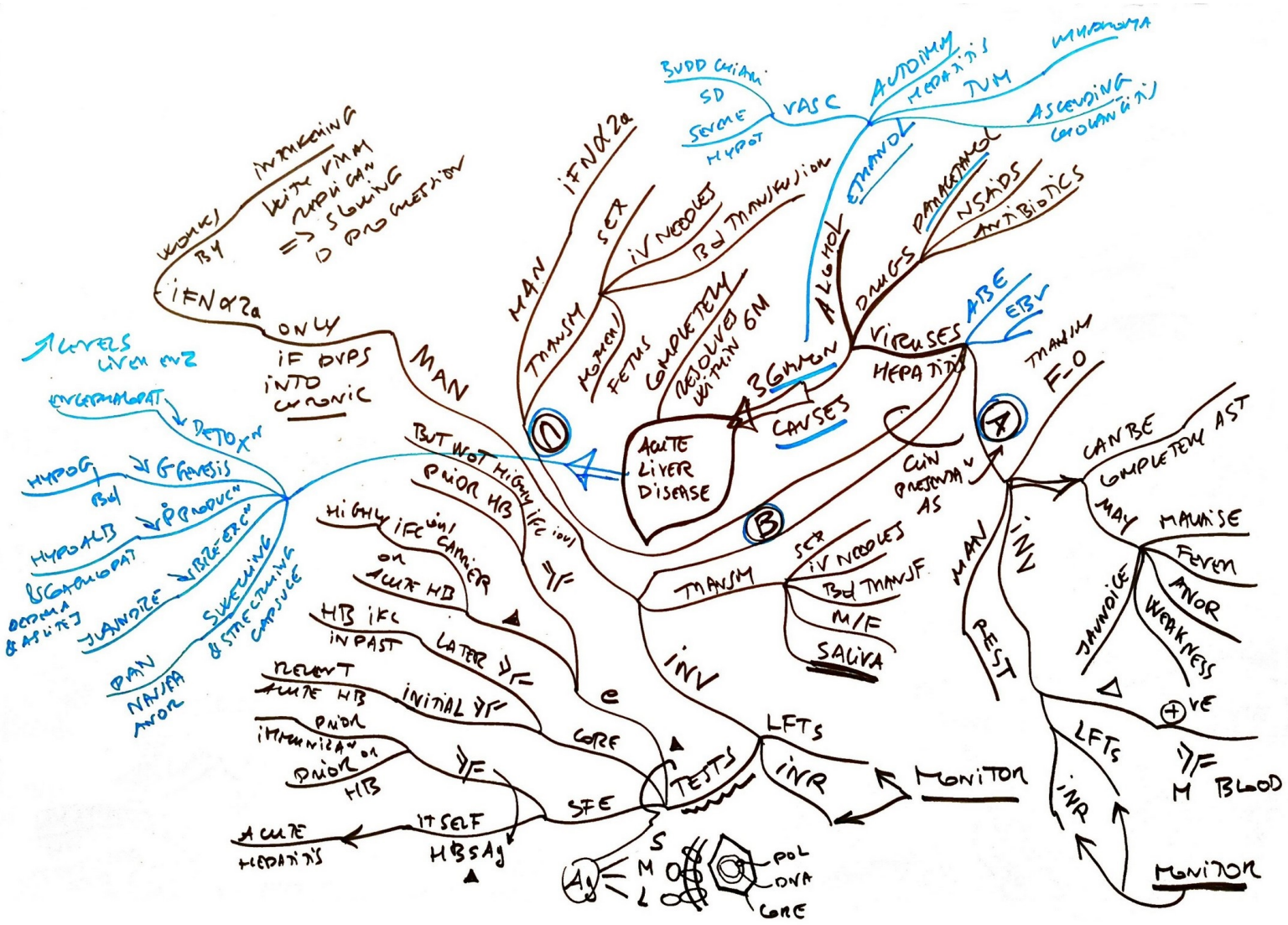
ACUTE LIVER DISEASE
CAUSES
ALCOHOL
DRUGS
PARACETAMOL
NSAIDS
ANTIBIOTICS
VIRUSES
HEPATITIS
A
B
C
D
E
ABE
EBV
TRANSM
F-O
CAN BE COMPLETELY ASYMPTOMATIC
CAN PRESENT W AS
MAY MIMISE
FEVER
ANOR
WEAKNESS
JAUNDICE
+ve
M BLOOD
MONITOR
LFTs
INR
INV
MAN
PREST
TRANSM
SEX
IV NEEDLES
BLD TRANSFUSION
M/F
SALIVA
HIGHLY IFC (in) CARRIER
BUT NOT HIGHLY IFC (in)
PRIOR HB
ON ACUTE HB
HB IFC IN PAST
LATER YF
INITIAL YF
RELEVANT ACUTE HB
PRIOR IMMUNIZATN OR PRIOR HB
YF
CORE
SFE
TESTS
ITSELF
HBSAg
ACUTE HEPATITIS
S
M
L
POL
DNA
CORE
MAN
IFNα2a
SEX
IV NEEDLES
BLD TRANSFUSION
TRANSM
MOTHER
FETUS
COMPLETELY RESOLVED WITHIN 6M
SEVERE HYPOT
BUDD CHIARI
SD
VASC
AUTOIMM HEPATITIS
LYMPHOMA
ASCENDING CHOLANGITIS
ETHANOL
WORKED BY
INTERFERING WITH VIRAL REPLICATN
SLOWING DOWN PROGRESSION
IFNα2a ONLY IF DVPS INTO CHRONIC
MAN
LEVELS OVER OVZ
ENCEPHALOPAT
DETOXN
HYPOG
BLD
GLUCOGENESIS
PRODUCTN
HYPOALB
GLUCOLIPOPAT
EDEMA & ASCITES
JAUNDICE
BILE EXCN
SKETCHING & STRETCHING CAPSULE
PAN
NAVIFA
ANOR

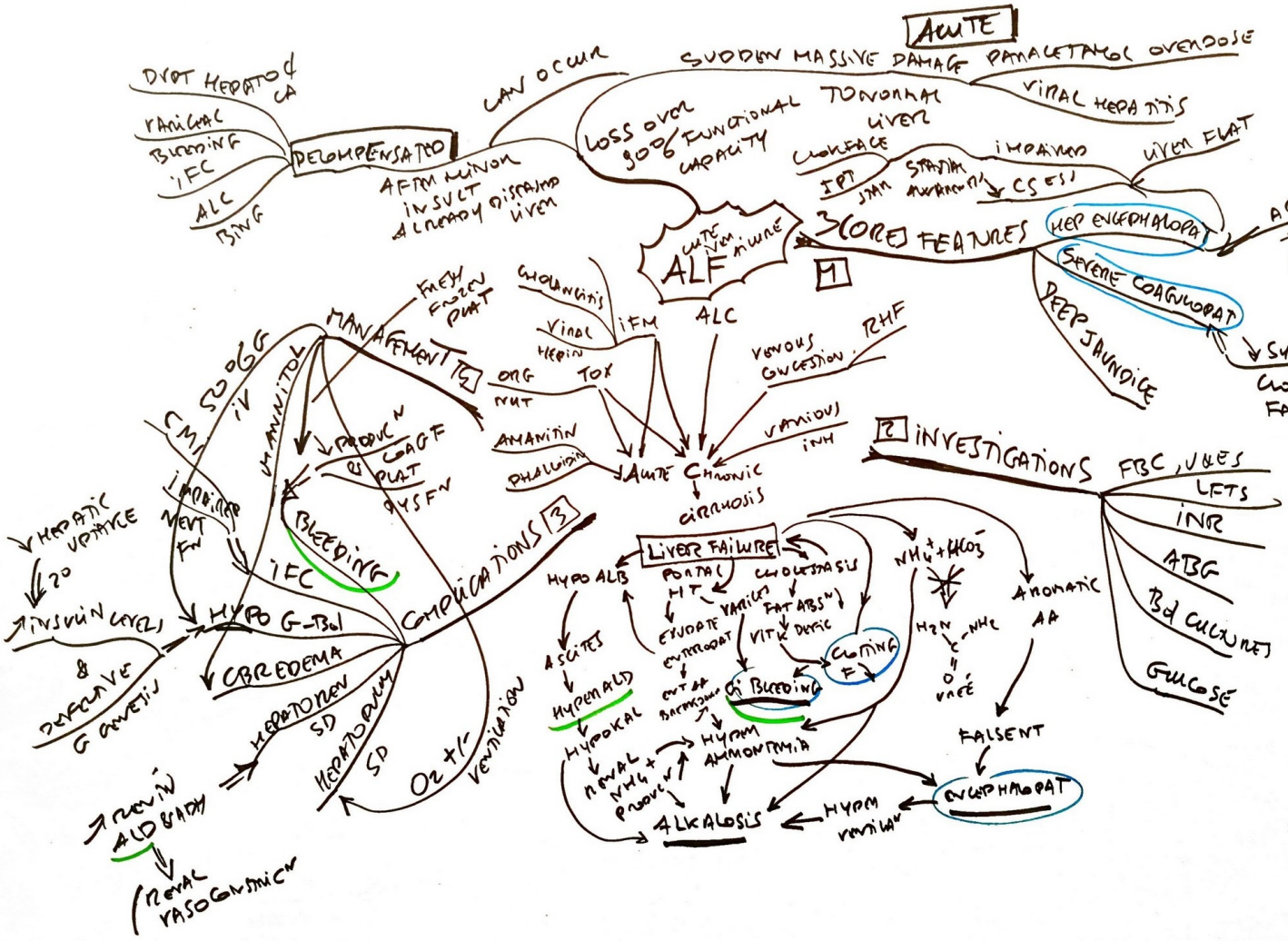
ACUTE
SUDDEN MASSIVE DAMAGE
PARACETAMOL OVERDOSE
VIRAL HEPATITIS
CAN OCCUR
LOSS OVER 90% FUNCTIONAL CAPACITY
NORMAL LIVER
DVT HEPATO CA
VARICEAL BLEEDING
iFC
ALC
BING
DECOMPENSATED
AFTER MINOR INSULT ALREADY DISEASED LIVER
JAUNDICE
IPT
JAN
STANDARD MANAGEMENT
IMPAIRED
CS ESI
LIVER FLAT
ACCUMULATION TOXINS IN BRAIN
3 CORE FEATURES
HEP ENCEPHALOPATHY
SEVERE COAGULOPATHY
DEEP JAUNDICE
SYNTHESIS CLOTTING FACTORS
ALF
ACUTE LIVER FAILURE
ALC
CHOLANGITIS
VIRAL HEPATITIS
iFM
ORG NUT
TOX
VENOUS CONGESTION
RHF
AMANITIN
PHALLOIDIN
VARIOUS
iNH
ACUTE
CHRONIC
CIRRHOSIS
MANAGEMENT
FREEZE FROZEN PLAT
CMV
SUPPORT
iV
MANNITOL
PRODUCTION
CLOTTING FACTORS
PLAT
DYSFN
BLEEDING
iFC
COMPLICATIONS
HEPATIC UPTAKE
20
↑INSULIN LEVELS
&
DEFICIENCY
GLUCAGON
HYPO G-Bol
CBR EDEMA
HEPATORENAL SD
HEPATOPULM SD
O2 +/- VENTILATION
↑RENIN ALDOSTERONE
RENAL VASOCONSTRICTION
LIVER FAILURE
HYPO ALB
ASCITES
HYPERALD
HYPOKAL
RENAL NH4+ PROBLEM
ALKALOSIS
PORTAL HT
ENDOTOXIN ENTEROCOLIT
CHOLESTASIS
VARICES
FAT ABSN
VIT K DEFIC
CLOTTING F
GI BLEEDING
HYPER AMMONAEMIA
NH4+ + HCO3-
H2N-C-NH2
O
UREA
ENCEPHALOPATHY
HYPER VENTILATION
AROMATIC AA
FALSE NT
2 INVESTIGATIONS
FBC, U&Es
LFTs
INR
ABG
Bld CULTURES
GLUCOSE

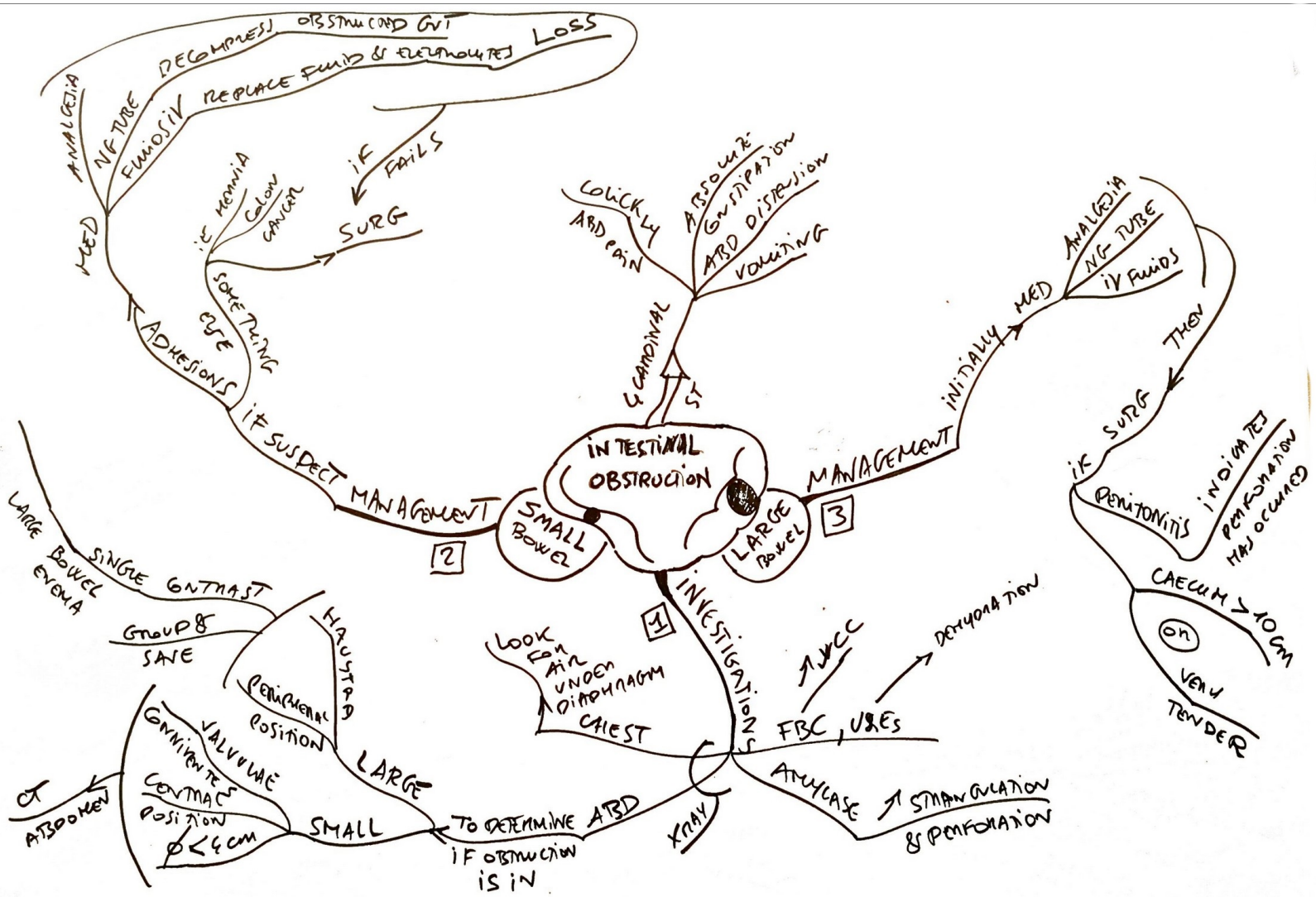
INTESTINAL OBSTRUCTION
SMALL BOWEL
LARGE BOWEL
2
3
1
MANAGEMENT
IF SUSPECT ADHESIONS
MED
ANALGESIA
NG TUBE
DECOMPRESS OBSTRUCTED GUT
FLUIDS & ELECTROLYTES
REPLACE FLUID & ELECTROLYTES
LOSS
IF FAILS
SURG
IE HERNIA
COLON CANCER
SOMETHING ELSE
4 CARDINAL
ST
QUICKLY
ABD PAIN
ABSOLUTE CONSTIPATION
ABD DISTENSION
VOMITING
INITIALLY
MED
ANALGESIA
NG TUBE
IV FLUIDS
THEN
IF SURG
PERITONITIS
INDICATES PERFORATION HAS OCCURRED
CAECUM > 10CM
ON
VERY TENDER
INVESTIGATIONS
FBC, U&Es
↑ WCC
DEHYDRATION
AMYLASE
↑ STRANGULATION & PERFORATION
XRAY
LOOK FOR AIR UNDER DIAPHRAGM
CHEST
TO DETERMINE ABD
IF OBSTRUCTION IS IN
SMALL
LARGE
HAUSTRA
PERIPHERAL POSITION
VALVULAE CONNIVENTES
CENTRAL POSITION
Ø < 4CM
CT ABDOMEN
LARGE BOWEL ENEMA
SINGLE CONTRAST
GROUP & SAVE

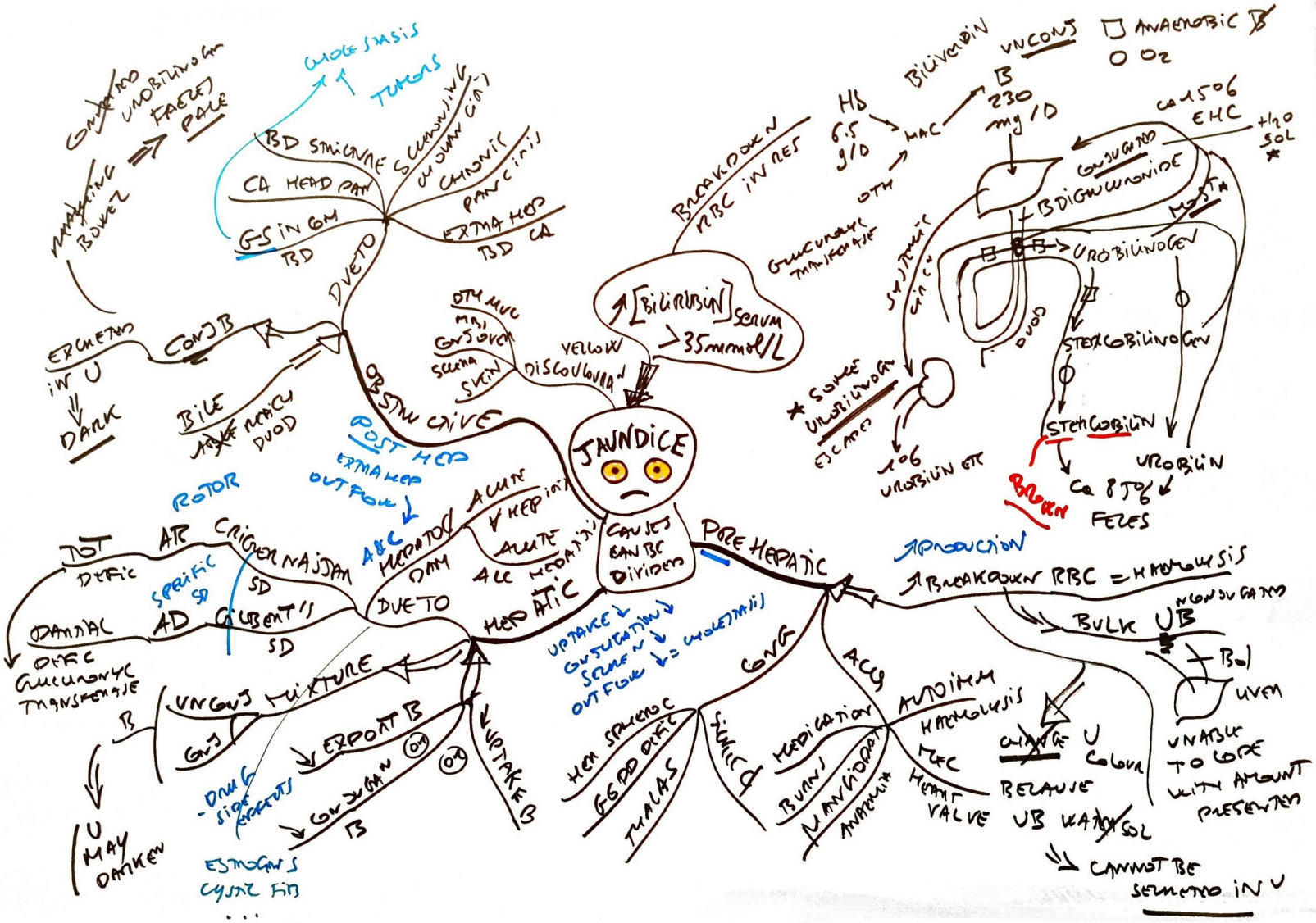
JAUNDICE
↑[BILIRUBIN] SERUM >35 mmol/L
YELLOW DISCOLOURED
OTH MUC MRI GUSOVER SCLERA SKIN
OBSTRUCTIVE
POST HEP
EXTRA HEP OUTFLOW
ROTOR
DUBIN JOHNSON
ATR
CRIGLER NAJJAR
SPECIFIC SD
SD
ADAMIAL DEFC GLUCURONYL TRANSFERASE
AD GILBERT'S
SD
ACUTE HEPATITIS
ACUTE HEPATITIS
HEPATOCELLULAR DAM
DUE TO
HEPATIC
CAUSES CAN BE DIVIDED
PRE HEPATIC
↑ PRODUCTION
↑ BREAKDOWN RBC = HAEMOLYSIS
BULK UB
NON CONJUGATED
UVEM
UNABLE TO GORE WITH AMOUNT PRESENTED
CANNOT BE SECRETED IN U
CHANGE U COLOUR
BECAUSE UB WATER SOL
HEMATURIA
MEC
AUTOIMM HAEMOLYSIS
ACQ
MEDICATION
BUNJ
NAVIGATOR
ANEMIA
CONG
SICKLE CELL
HEM SPHEROC
G6PD DEFIC
THALAS
UPTAKE ↓ CONJUGATION ↓ SECRETION ↓ OUTFLOW ↓ = HYPERBILIRUBINEMIA
UNCONJ MIXTURE
GJ
EXPORT B
GUNN
B
DRUG SIDE EFFECTS
ESTROGENS CYSTIC FIB
...
U MAY DARKEN
B
DUE TO
BD STRICTURE
SCLEROSING CHOLANGITIS
CHRONIC PANCREATITIS
CA HEAD PAN
GS IN GM BD
EXTRA HEP BD CA
CHOLESTASIS
TUMORS
CONJ B
ERGMENTS IN U
DARK
BILE
ACUTE MERCY DUOD
BREAKDOWN RBC IN RES
HB 6.5 g/D
HAC
BILIVERDIN
UNCONJ
B 230 mg/D
ANAEROBIC B
O O2
CA 1506 EHC
+H2O SOL
GUSUGATED
BDIGLUCURONIDE
MOSTLY
GLUCURONYL TRANSFERASE
OTH
SULFATASE IN GI
B
UROBILINOGEN
DUOD
STERCOBILINOGEN
STERCOBILIN
BROWN
UROBILIN
CA 8 % FECES
SOME UROBILINOGEN ESCAPES
1-6 UROBILIN ETC

MECKEL'S DIVERTICULUM
ILEO-CAECAL VALVE
2.5 m
2 FEET
2 INCHES
MAY CONTAIN ECTOPIC GAS MUCOSA & OVP PU
REMNANT VITELLO INT DUCT (WHICH USUALLY DISAPPEARS)
MOST COMMON MALFORMATION SMALL INT
OCCASIONALLY
BLEEDING
VOLVULUS
IF TETHERED TO ABD WALL
INTUSSUSCEPTION
IF IT CONTAINS ECTOPIC GASTRIC
APPENDICITIS LIKE ST
USUALLY
AST
CLASSICALY OCCURS
2 INCHES LENGTH 2 FEET FROM ICV
2-6 POP
PAIN
BOLING
INVESTIGATIONS
LAPAROSCOPY
TECHNETIUM SCAN
MANAGEMENT
SURG
IF EXCISION

NL

MEDIMADS

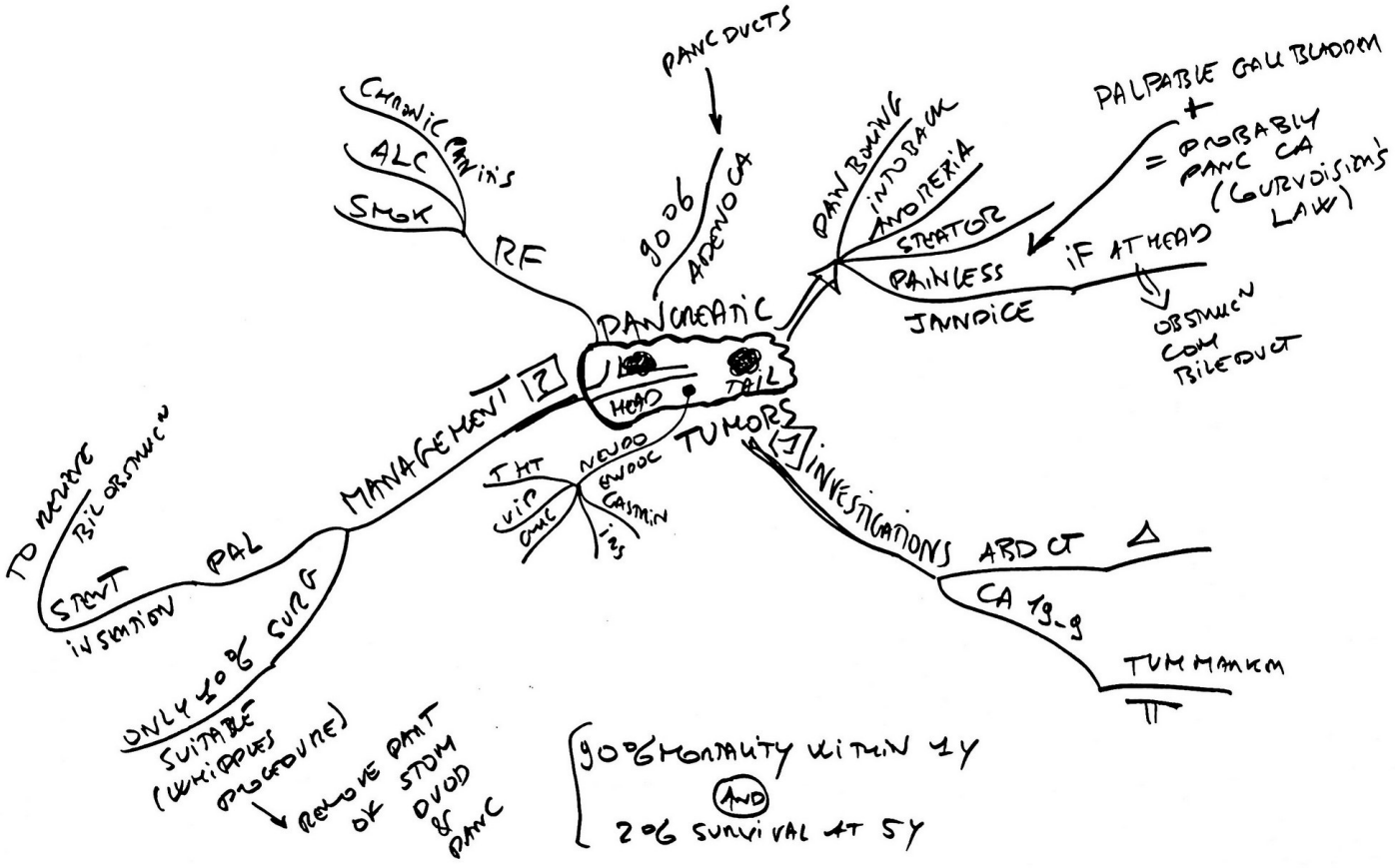
PANCREATIC
HEAD
TAIL
TUMORS
RF
CHRONIC PANX'S
ALC
SMOK
PANC DUCTS
90 % ADENO CA
PAIN BOWING
INTO BACK
ANOREXIA
STEATOR
PAINLESS JAUNDICE
IF AT HEAD
OBSTRUCN COM BILE DUCT
PALPABLE GALL BLADDER
+
= PROBABLY PANC CA (COURVOISIER'S LAW)
INVESTIGATIONS
ABD CT
CA 19-9
TUMMARKER
MANAGEMENT
TO RELIEVE BIL OBSTRUCN
STENT
INSERTION
PAL
ONLY 10% SURG
SUITABLE (WHIPPLES PROCEDURE)
REMOVE PART OF STOM DUOD & PANC
THT
VIP
GNC
NEURO
ENDOC
GASTRIN
INS
90% MORTALITY WITHIN 1Y
AND
2% SURVIVAL AT 5Y

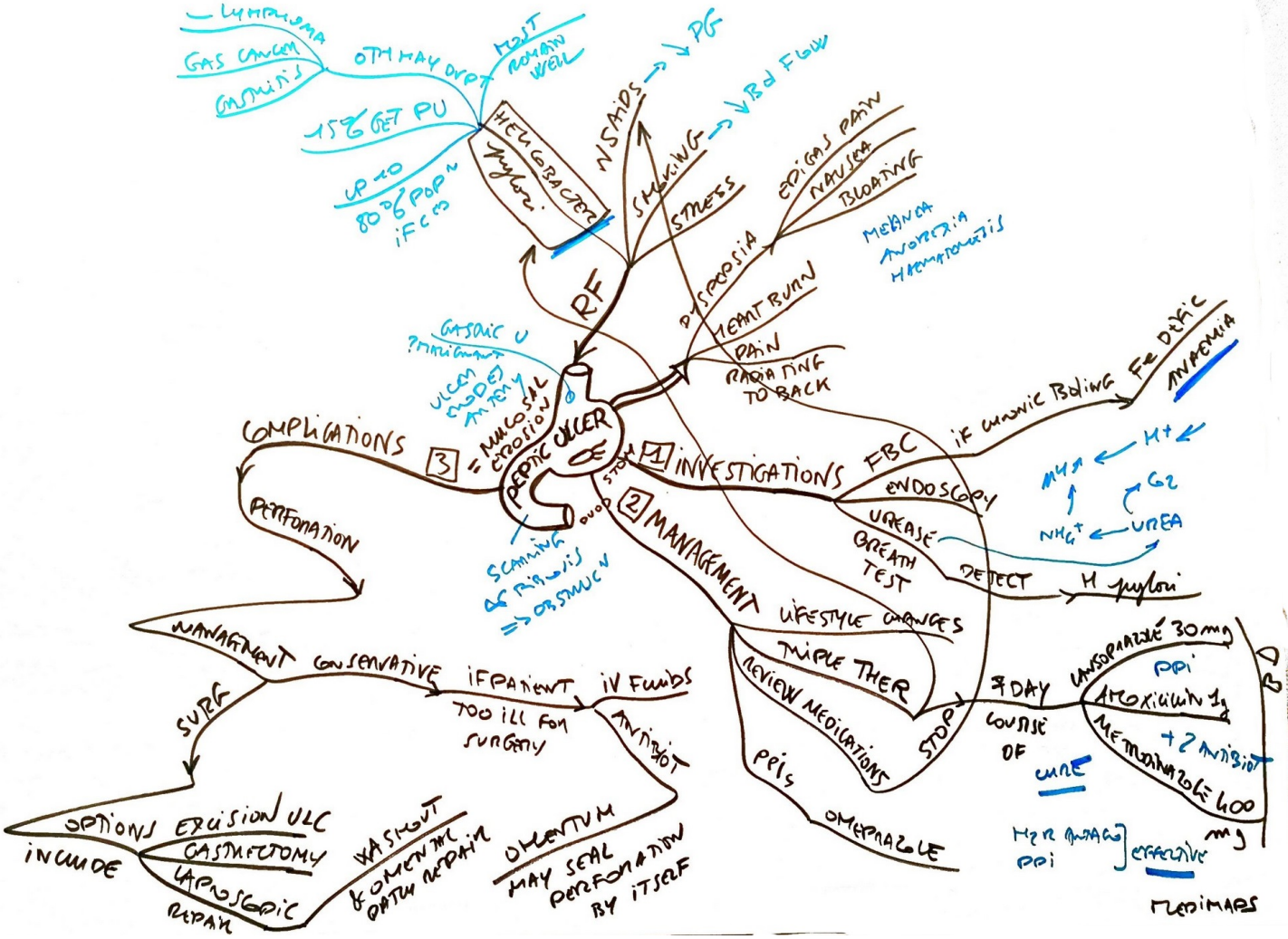
PEPTIC ULCER
RF
H. pylori
NSAIDS → ↓ PG
SMOKING → ↓ Blood Flow
STRESS
DYSPEPSIA
EPIGAS PAIN
NAUSEA
BLOATING
HEART BURN
PAIN RADIATING TO BACK
MELENA
ANOREXIA
HAEMATEMESIS
GASTRIC U
?MALIGNANT
ULCER ENDED ANTERIOR
MUCOSAL EROSION
SCARRING OF PYLORUS => OBSTRUCTN
DUOD
STOMACH
1 INVESTIGATIONS
FBC
IF CHRONIC BLEING
Fe DEFIC ANAEMIA
ENDOSCOPY
UREASE BREATH TEST
DETECT
H pylori
NH3
H+
CO2
NH4+
UREA
2 MANAGEMENT
LIFESTYLE CHANGES
TRIPLE THER
REVIEW MEDICATIONS
PPIs
OMEPRAZOLE
STOP
7 DAY COURSE OF CURE
LANSOPRAZOLE 30 mg
PPI
AMOXICILLIN 1g
METRONIDAZOLE 400 mg
+ 2 ANTIBIOT
H2R ANTAGO
PPI
EFFECTIVE
MEDIMARS
3 = MUCOSAL EROSION
COMPLICATIONS
PERFORATION
MANAGEMENT CONSERVATIVE
IF PATIENT TOO ILL FOR SURGERY
IV FLUIDS
ANTIBIOT
SURG
OPTIONS EXCISION ULC
INCLUDE
GASTRECTOMY
LAPROSCOPIC REPAIR
WASHOUT & OMENTAL PATCH REPAIR
OMENTUM MAY SEAL PERFORATION BY ITSELF
LYMPHOMA
GAS CANCER
GASTRITIS
OTHER MAY OCCUR
MOST ROMAN WELL
15% GET PU
UP TO 80% POPN IFCTD

UPPER GI BLEEDING
HEAMATEMESIS
MELENA
DUE TO
PU
GASTRITIS
MALLORY-WEISS TEAR
IN OESOPH WALL
FORCEFUL VOMITING
OESOPH VARICES
PORTAL HT
OESOPHAGITIS
GORD
GM
1 INVESTIGATIONS
FBC, U&Es
LFTs
CLOTTING SCREEN
CROSS MATCH 2 UNITS
CHEST XRAY
ARAB XRAY
OGD
PERFORATED OES OR VISCUS
2 ROCKALL SCORE
ALLOWS CALCULATION RISK
REBLEEDS
MORTALITY
SPLIT INTO
PRE-ENDOSCOPY
AGE
SHOCK
COMORBIDITIES
POST-ENDOSCOPY
DIAGNOSIS
SIGNS OF RECENT HAEMOR
PROGNOSIS
≥8 POOR
<3 GOOD
3 MANAGEMENT
A, B, C
O2
IV ACCESS
O.S & SAVE IV
CALL SENIOR HELP
ANTIBIOT
BLEEDING VARICES
ADM ANALOGUE TERLIPRESSIN
OR
OCTREOTIDE
TI SST ANALOGUE
THEN BANDING
OR
SCLERO-THER
IF FAILS
BALLOON TAMPONADE
USING SENGSTAKEN-BLAKEMORE TUBE
IF FAILS
TIPS
TRANSJUGULAR INTRAHEPATIC PORTOSYSTEMIC SHUNT
4 MONITOR
STOOL CHART
FLUID BALANCE
BP, PULSE
IF ULCER
GASTRECTOMY
EXCISION ULC
UNDERRUNNING THE ULC
NL
MEDIMAPS

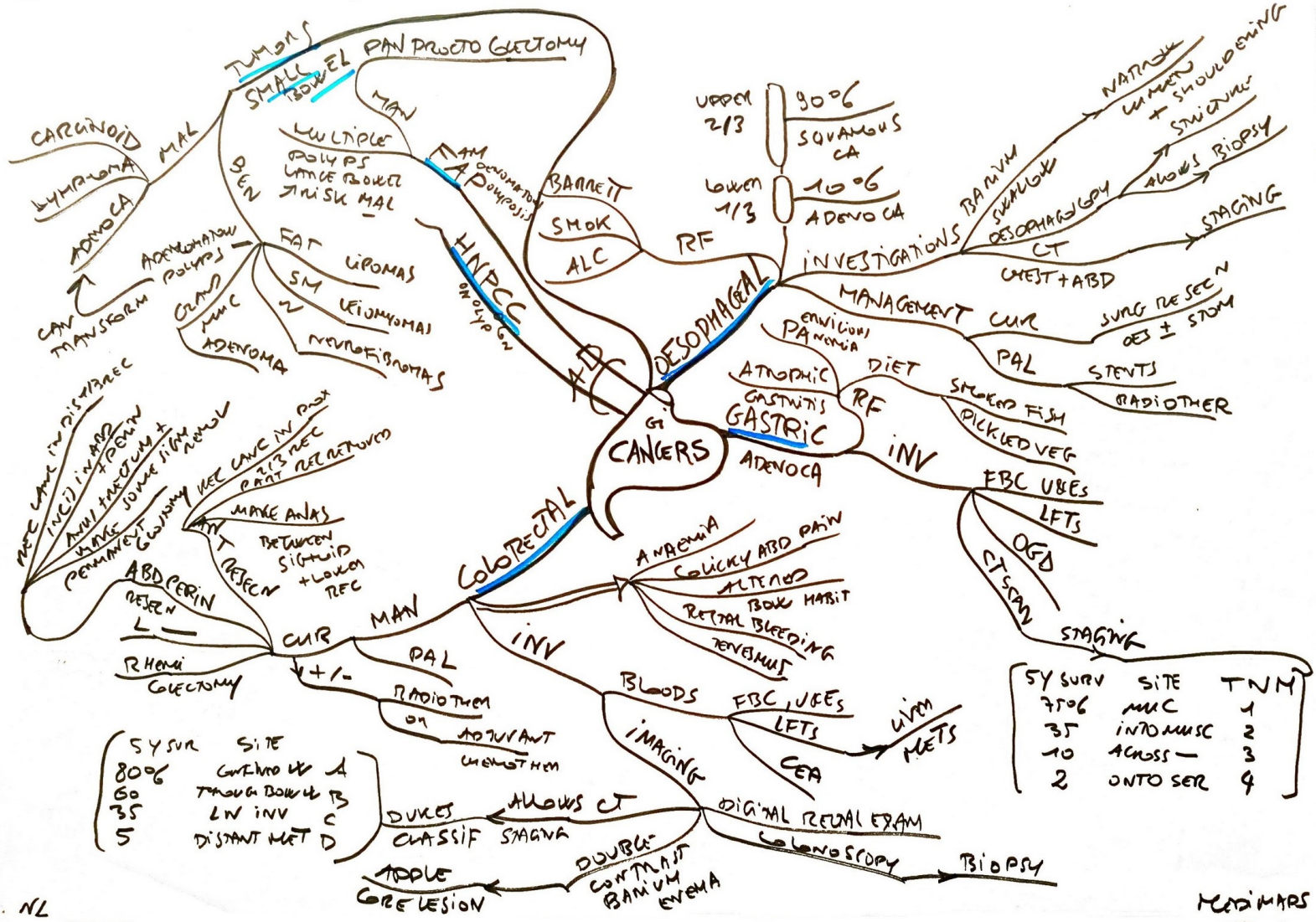
GI CANCERS
OESOPHAGAL
UPPER 2/3
90%
SQUAMOUS CA
LOWER 1/3
10%
ADENO CA
BARRETT
SMOK
ALC
RF
INVESTIGATIONS
BARIUM
SWALLOW
OESOPHAGOGRAM
ALLOWS BIOPSY
CT
CHEST + ABD
STAGING
MANAGEMENT
CUR
SURG RESECN
OES ± STOM
PAL
STENTS
RADIOTHER
DIET
SMOKED FISH
PICKLED VEG
INV
FBC, UCEs
LFTs
OGD
CT SCAN
STAGING
GASTRIC
ADENOCA
ATROPHIC GASTRITIS
RF
ENVIRONM PANEMIA
HNPCC
ON POLYPGN
FAM ADENOMATOUS POLYPOSIS
MAN
SMALL BOWEL
TUMOURS
PAN PROCTO COLECTOMY
MULTIPLE POLYPS LARGE BOWEL
↑ RISK MAL
SEN
FAT
LIPOMAS
SM
LEIOMYOMAS
N
NEUROFIBROMAS
ADENOMATOUS POLYPS
GRAND MUC
ADENOMA
CAN TRANSFORM
CARCINOID
LYMPHOMA
ADENO CA
MAL
COLORECTAL
ANAEMIA
COLICKY ABD PAIN
ALTERED BOWEL HABIT
RECTAL BLEEDING
TENESMUS
INV
BLOODS
FBC, UCEs
LFTs
CEA
LIVER METS
IMAGING
DIGITAL RECTAL EXAM
COLONOSCOPY
BIOPSY
ALLOWS CT
DUKES CLASSIF
STAGING
DOUBLE CONTRAST BARIUM ENEMA
APPLE CORE LESION
MAN
CUR
ABD PERIN RESECN
L —
R Hemi COLECTOMY
+/-
PAL
RADIOTHER
ADJUVANT CHEMOTHER
ANT RESECN
BETWEEN SIGMOID + LOWER REC
MARKE ANAS
REC CANC INV POST 2/3 REC
PART REC REMOVED
REC CANC INV DISTAL REC
INCIS INVAD + PERIN
ANUL TARCTUM + SPHINCTER
PERMANENT COLOSTOMY
NEMOV
SYSURV SITE
80% GUT WALL A
60 THROUGH BOWEL B
35 LN INV C
5 DISTANT MET D
SY SURV SITE TNM
75% MUC 1
35 INTO MUSC 2
10 ACROSS — 3
2 ONTO SER 4
NL
MARIMARS

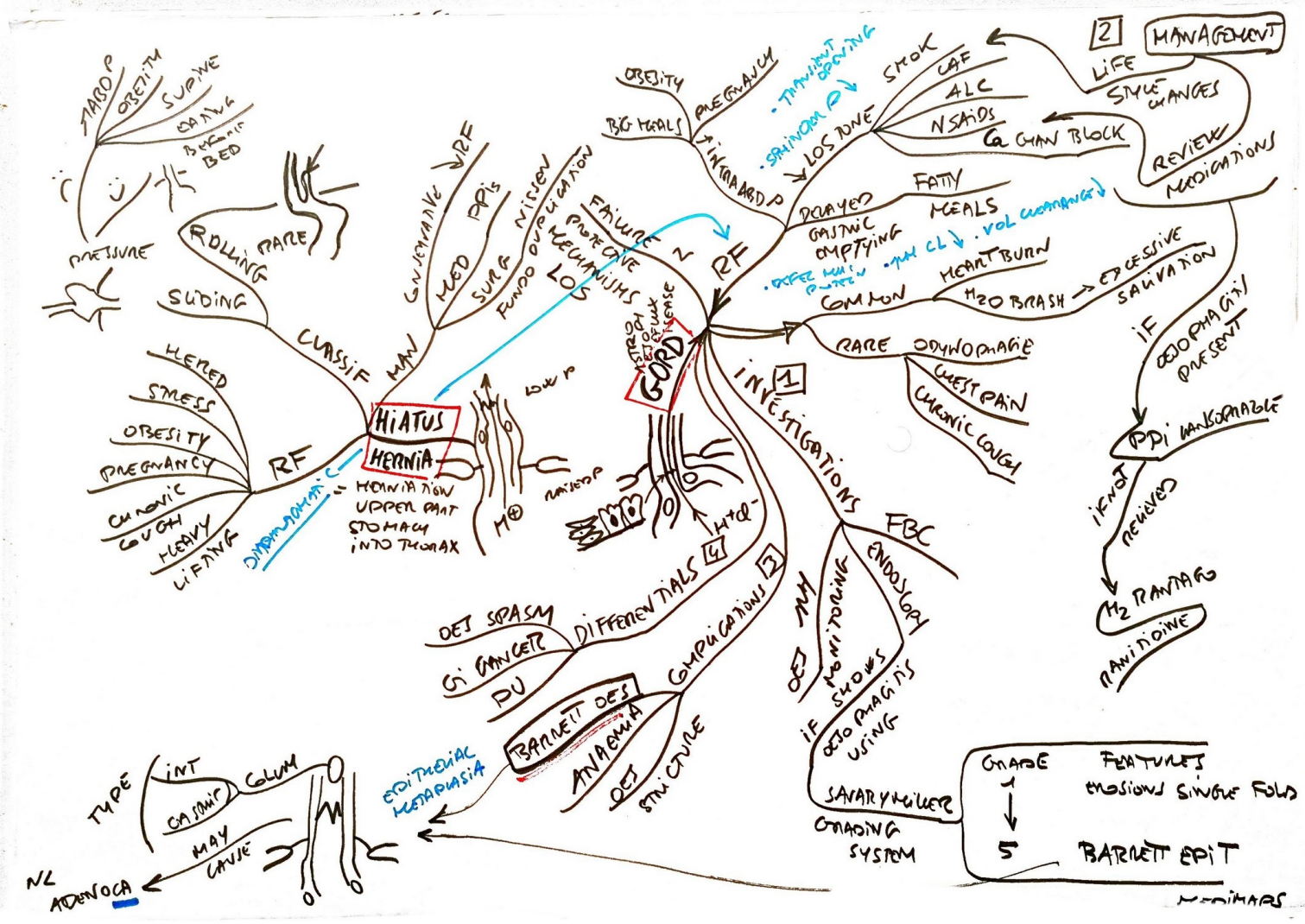
HIATUS HERNIA
HERNIATION UPPER PART STOMACH INTO THORAX
CLASSIF MAN
ROLLING
SLIDING
RF
HEARTBURN
STRESS
OBESITY
PREGNANCY
CHRONIC COUGH
HEAVY LIFTING
DIAPHRAGMATIC
GORD
RF
OBESITY
PREGNANCY
BIG MEALS
SMOK
CAF
ALC
NSAIDS
Ca CHAN BLOCK
LOS TONE
FATTY MEALS
DELAYED GASTRIC EMPTYING
COMMON
HEART BURN
H2O BRASH
EXCESSIVE SALIVATION
RARE
ODYNOPHAGIE
CHEST PAIN
CHRONIC COUGH
INVESTIGATIONS
FBC
ENDOSCOPY
BARRETT DES
ANAEMIA
DIFFERENTIALS
GI CANCER
PU
DET SPASM
COMPLICATIONS
DET STRICTURE
EPITHELIAL METAPLASIA
TYPE
INT
COLUM
GASTRIC
MAY CAUSE
NL ADENOCA
MANAGEMENT
LIFE STYLE CHANGES
REVIEW MEDICATIONS
IF DYSPHAGIA PRESENT
PPI MANDATORY
IF NOT RELIEVED
H2 BLOCKER
RANITIDINE
GRADE
FEATURES
EROSIONS SINGLE FOLD
BARRETT EPIT
SAVARY MILLER GRADING SYSTEM

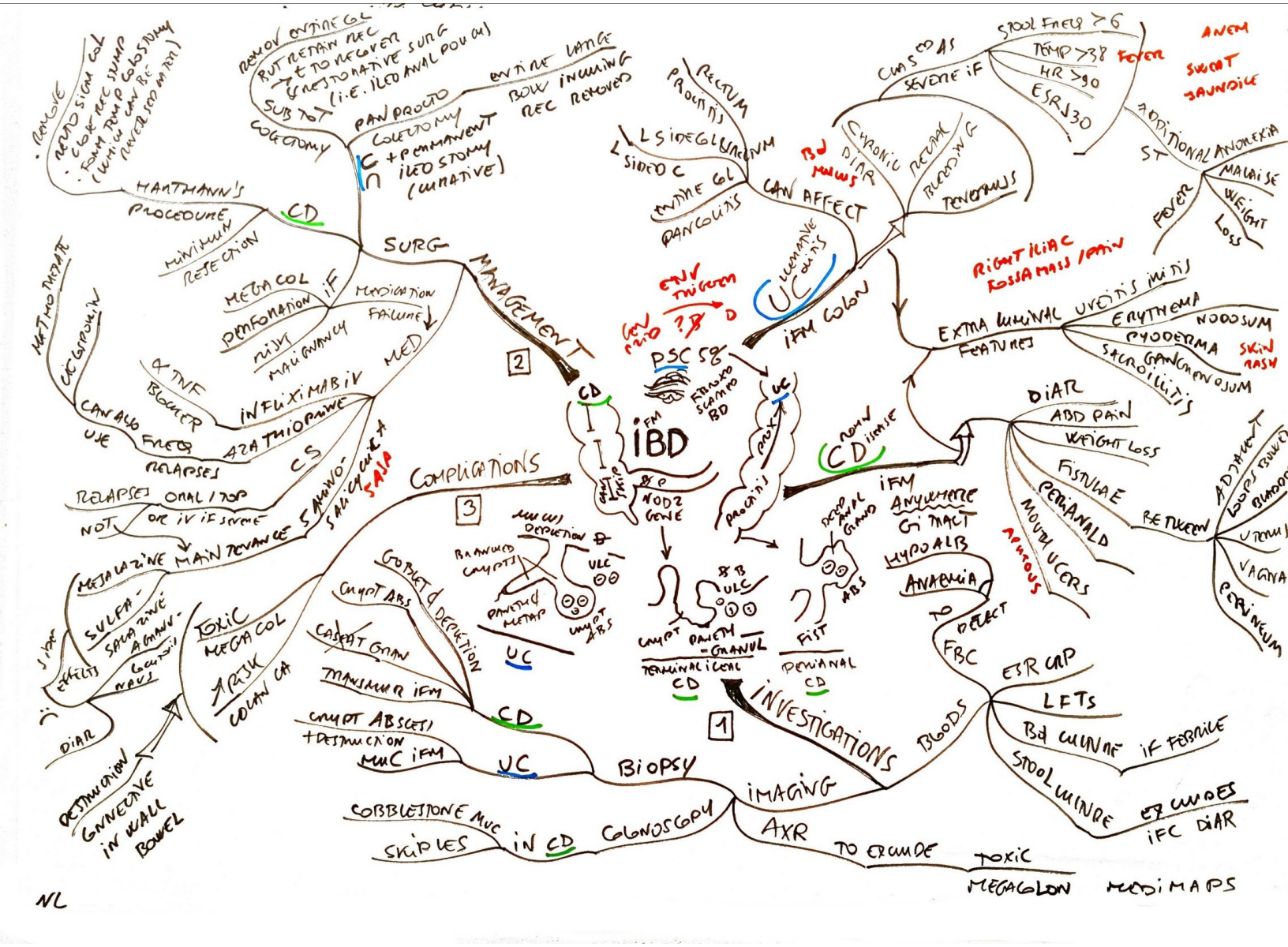
IBD
MANAGEMENT
SURG
MEDICAL
COMPLICATIONS
INVESTIGATIONS
BIOPSY
IMAGING
BLOODS
CD
UC
PSC
IFM COLON
EXTRA INTESTINAL FEATURES
DIAR
ABD PAIN
WEIGHT LOSS
FISTULAE
PERIANAL
MOUTH ULCERS
APHTHOUS
ANAEMIA
HYPOALB
FBC
ESR CRP
LFTS
STOOL MICROBE
IF FEBRILE
EXCLUDES IFC DIAR
TO EXCLUDE TOXIC MEGACOLON
COLONOSCOPY
SKIPPED
COBBLESTONE MUC
AXR
MRI
CAN AFFECT
CHRONIC DIAR
RECTAL BLEEDING
TENESMUS
SEVERE IF
STOOL FREQ >6
TEMP >38
HR >90
ESR >30
ANEM
SWEAT
JAUNDICE
ADDITIONAL ANOREXIA
MALAISE
WEIGHT LOSS
FEVER
RIGHT ILIAC FOSSA MASS / PAIN
ERYTHEMA NODOSUM
PYODERMA
SACROILIITIS
GANGRENOSUM
SKIN RASH
ADDITIONAL LOOKS BOWEL
BLADDER
URETHRA
VAGINA
PERINEUM
RETTKEEN
HARTMANN'S PROCEDURE
MINIMUM RESECTION
MEGACOL
PERFORATION
MALIGNANCY
MEDICATION FAILURE
INFLIXIMAB IV
AZATHIOPRINE
CS
SAMPS
SALICYLATE
MAIN TREATMENT
RELAPSES
ORAL / IV IF SEVERE
NOT
CAN ALSO USE
METHOTREXATE
CICLOSPORIN
ANTI TNF
BIOLOGICS
MESALAZINE
SULFA-SALAZINE
AMINO-SALICYLATES
SIDE EFFECTS
DIAR
TOXIC MEGACOL
RISK COLON CA
DESTRUCTION GRANULOMA IN WALL BOWEL
CASEATING GRAN
MAINSTAY IFM
CRYPT ABSCESS + DESTRUCTION
MUC IFM
GOBLET CELL DEPLETION
CRYPT ABS
BRANCHED CRYPTS
PANETH METAP
CRYPT ABS
ULC
CRYPT PANETH - GRANUL
TERMINAL ILEAL
FIST
PERIANAL
ENV TRIGGER
GEN PRED
NOD2 GENE
PSC 5q
FRANKS SCAMPO BD
PROCTITIS
PANCOLITIS
LEMANIC CHOLITIS
DEEP ANAL GLAND
ABS
GI TRACT
ANYWHERE
RECTUM PROCTITIS
L SIDED GL
SIDED C
ENTIRE GL
PANCOLITIS
PAN PROCTO COLECTOMY + PERMANENT ILEOSTOMY (MATURE)
ENTIRE LARGE BOWEL INCLUDING REC REMOVED
REMOV ENTIRE GL BUT RETAIN REC TO RECOVER GENUINE NATIVE SURG (i.e. ILEO ANAL POUCH)
SUB TOT COLECTOMY
MEGALOVE
MUCUS SIGN GL
CLOSE REC SUMP
FORM TEMP COLOSTOMY (WHICH CAN BE REVERSED IN FUTURE)

NL

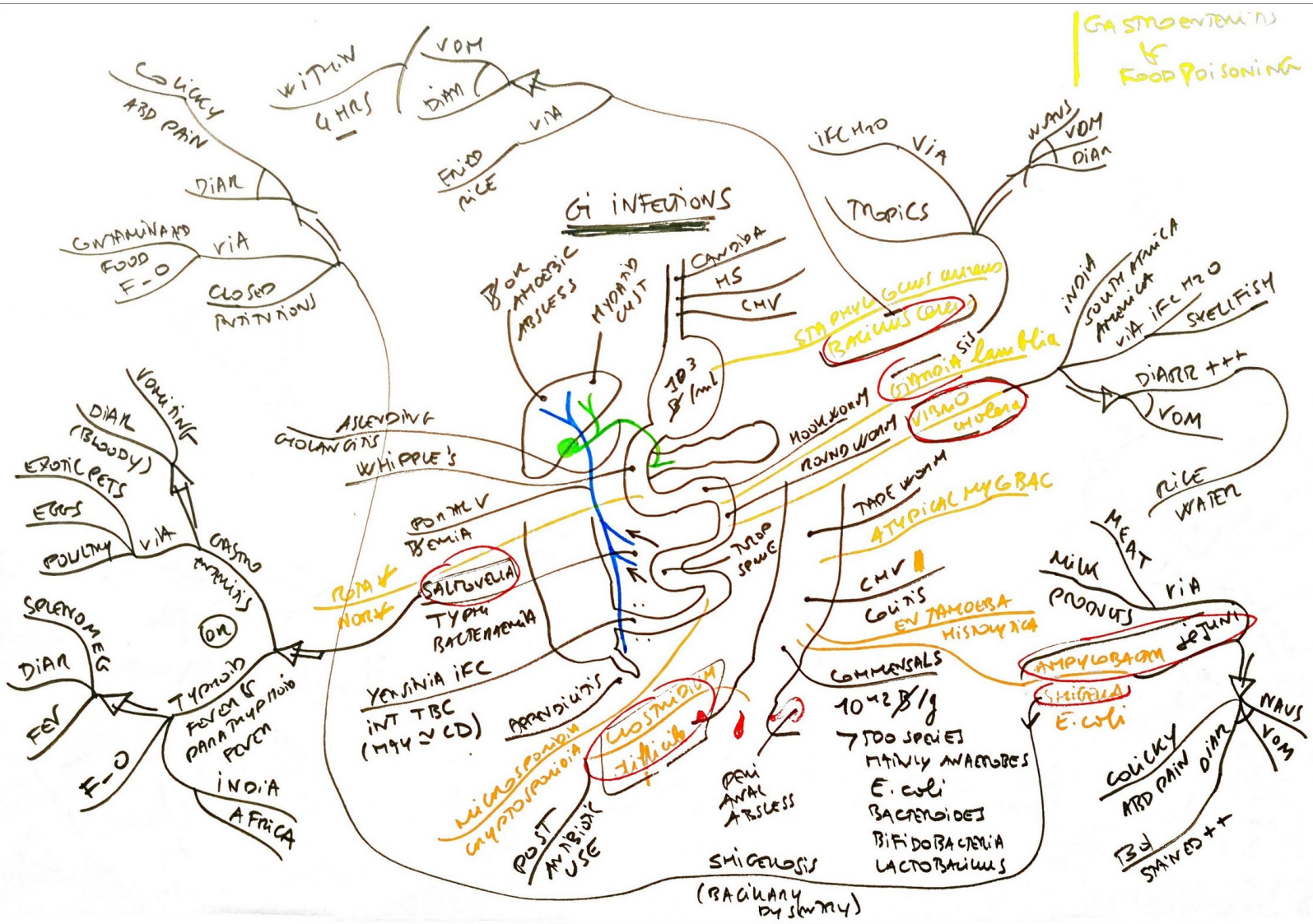
GI INFECTIONS
GASTROENTERITIS & FOOD POISONING
COLICKY ABD PAIN
DIAR
WITHIN 4 HRS
VOM
DIAR
FRIED RICE
VIA
GUANAMINAND FOOD F-O
VIA
CLOSED INSTITUTIONS
IFC H2O
VIA
TROPICS
NAUS
VOM
DIAR
BOIL AMOEBIC ABSCESS
HYDATID CYST
CANDIDA
HS
CMV
STAPHYLOCOCCUS AUREUS
BACILLUS CEREUS
INDIA
SOUTH AMERICA
VIA IFC H2O
SHELLFISH
GIARDIASIS lamblia
VIBRIO CHOLERA
DIARR +++
VOM
RICE WATER
ASCENDING CHOLANGITIS
WHIPPLE'S
HOOKWORM
ROUNDWORM
TAPEWORM
ATYPICAL MYCBAC
CMV
COLITIS
EN TAMOEBA HISTOLYTICA
TROP SPRUE
VOMITING
DIAR (BLOODY)
EXOTIC PETS
EGGS
POULTRY
VIA
GASTRO ENTERITIS
ROTA & NORO
FOOD BORNE V BEMIA
SALMONELLA
TYPHI BACTEREMIA
YERSINIA IFC
INT TBC (MAY ≃ CD)
APPENDICITIS
CLOSTRIDIUM difficile
MICROSPORIDIA
CRYPTOSPORIDIA
POST ANTIBIOTIC USE
PERI ANAL ABSCESS
SHIGELOSIS
(BACILLARY DYSENTERY)
COMMENSALS
$10^{12}$ B/g
700 SPECIES
MAINLY ANAEROBES
E. coli
BACTEROIDES
BIFIDOBACTERIA
LACTOBACILLUS
MILK
MEAT
PRODUCTS
VIA
AMPYLOBACTER jejuni
SHIGELLA
E. coli
NAUS
VOM
COLICKY ABD PAIN
DIAR
BLD STAINED ++
SPLENOMEG
DIAR
FEV
F-O
TYPHOID
FEVER & PARATYPHOID FEVER
INDIA
AFRICA
ON