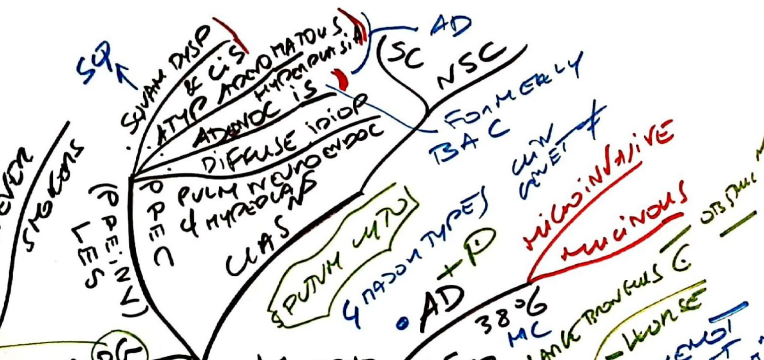
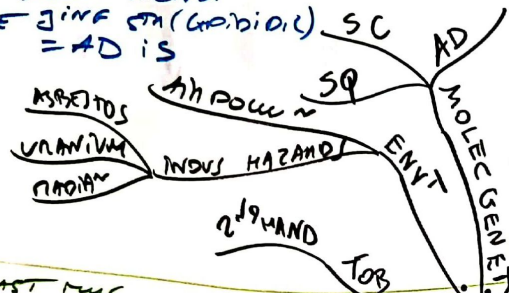
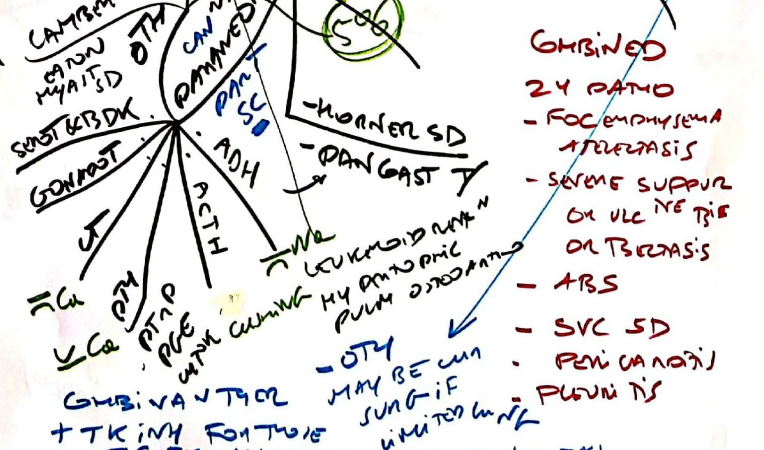
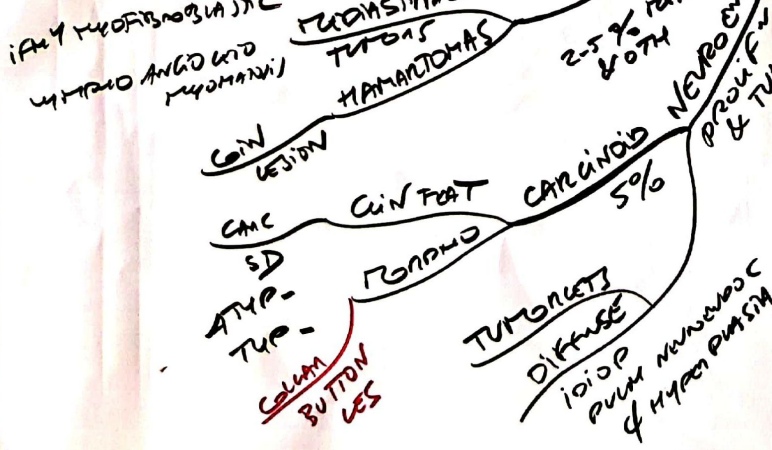
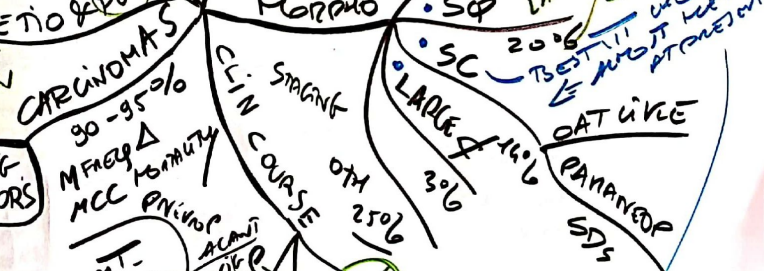
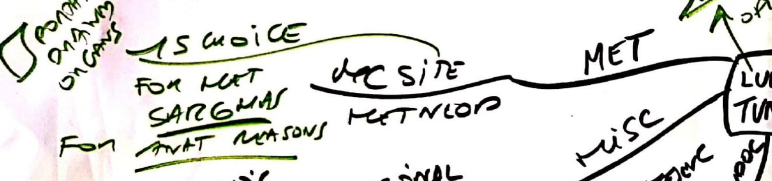


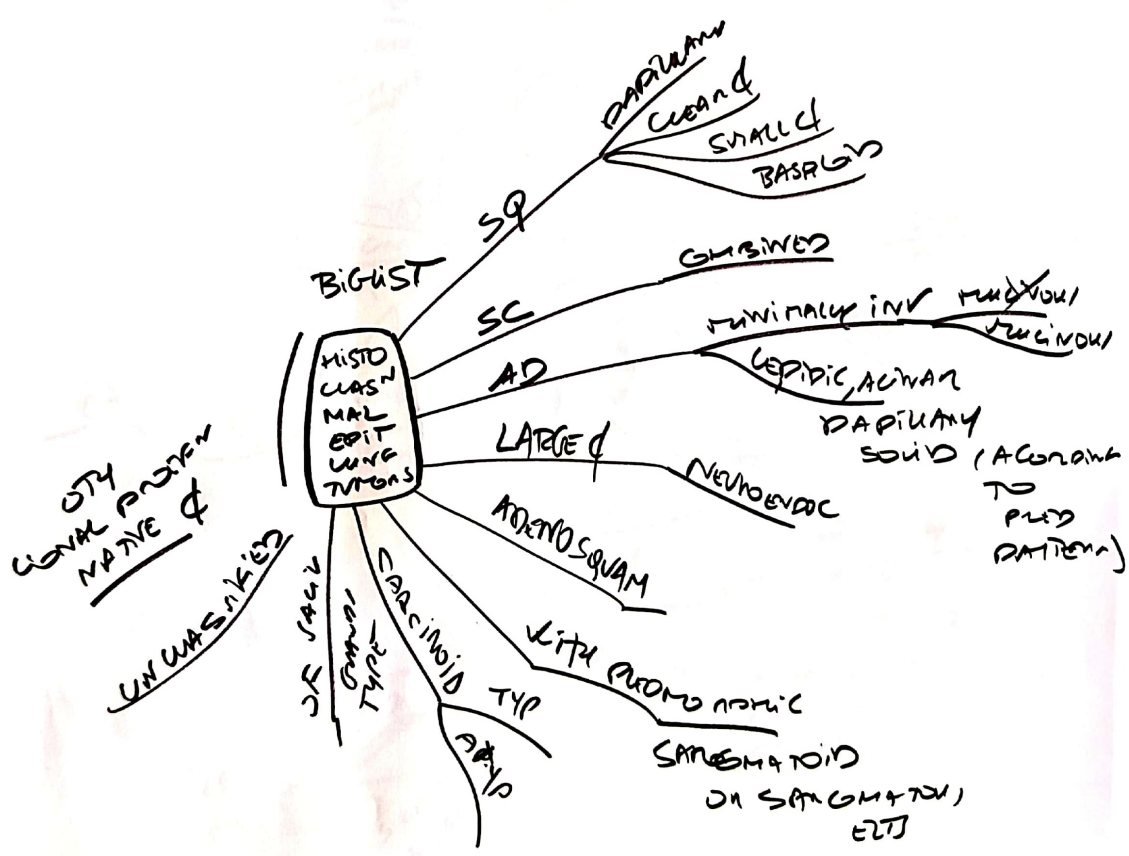
< 3cm or less in Ø
 pure growth among
 pre JINE (Gobiodi) SC
 = AD is

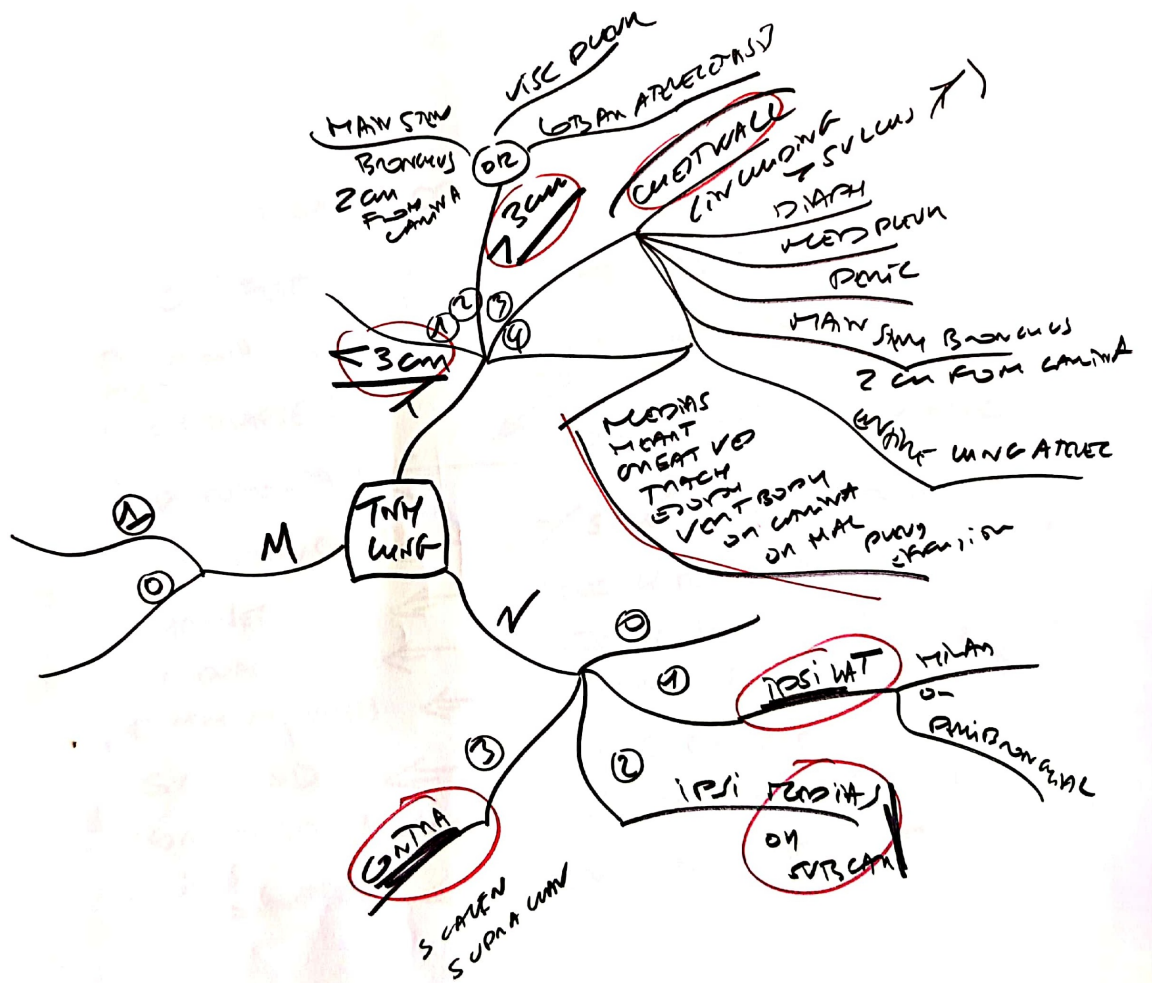


- METAPLAST/OISPLAST MUC
- CIS SQ AD
- INFILTRATING
- METAS may occur

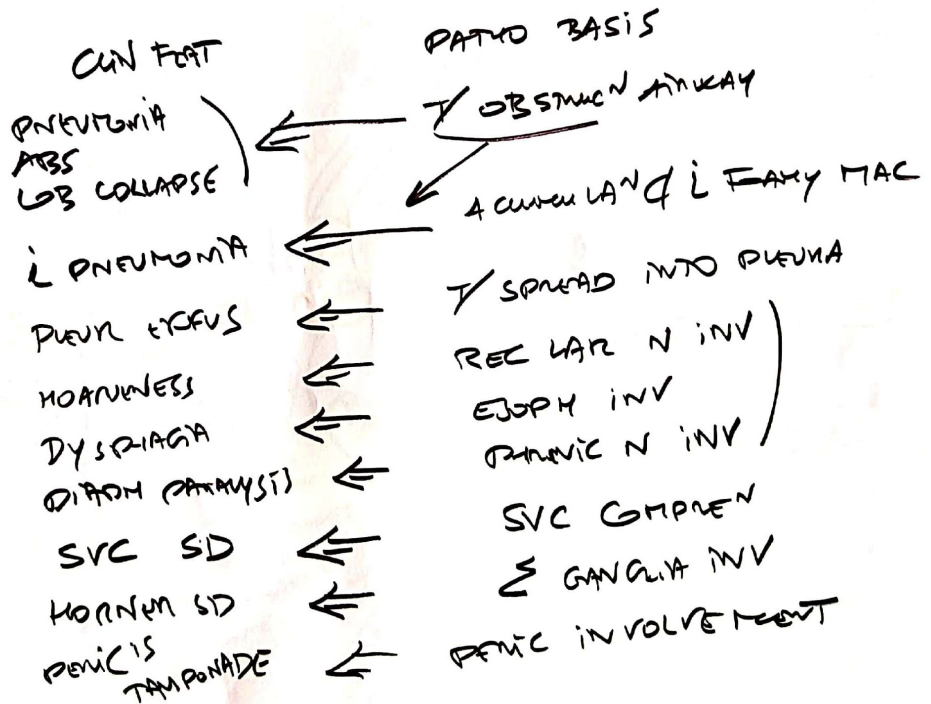


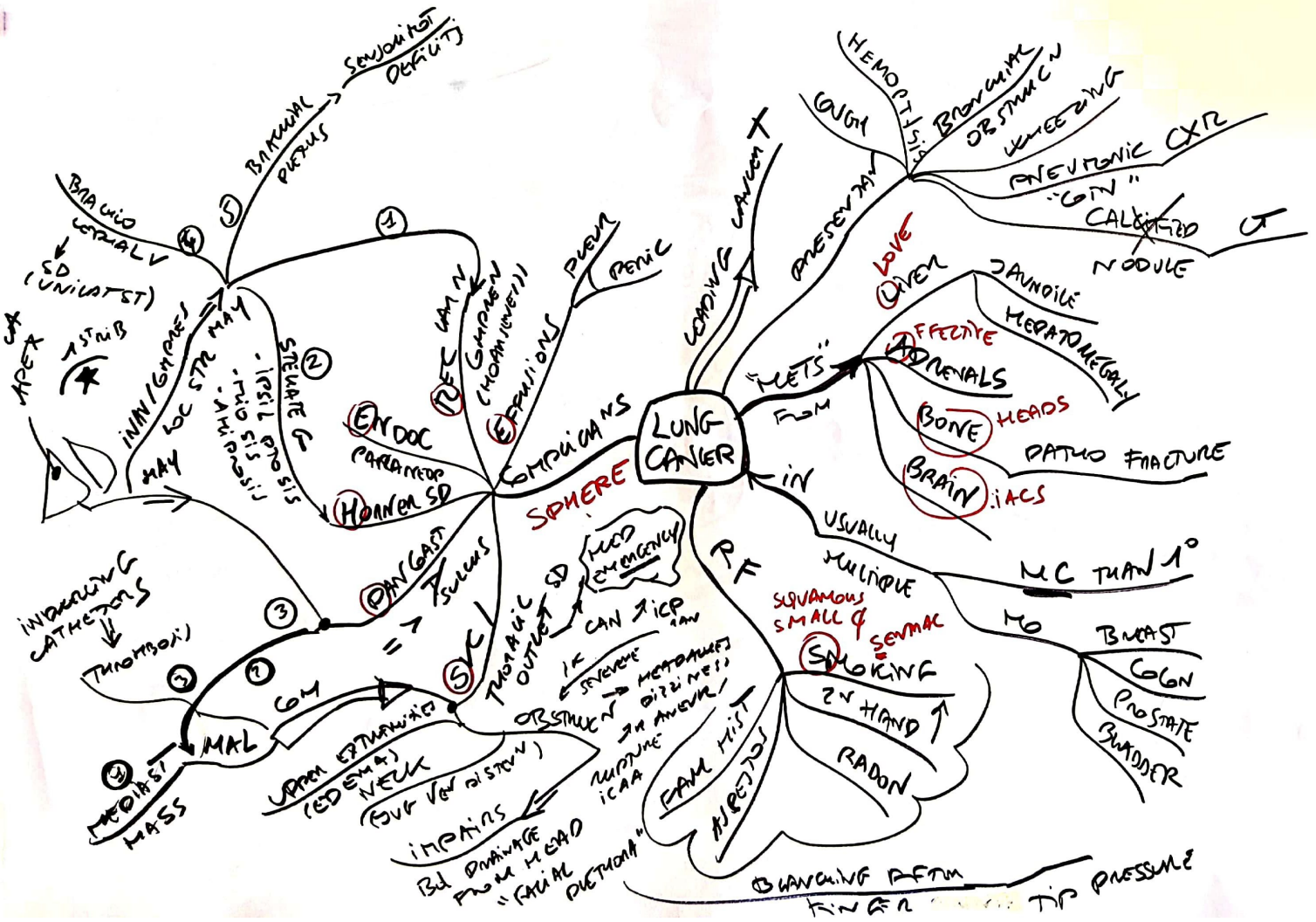
- COMBINED**
- 24 PATHO
 - FOC EMPHYSEMA
 - ATELECTASIS
 - SEVERE SUPPUR
 - OR ULC INE TRIE
 - OR T3EASIS
 - ABS
 - SVC SD
 - PERI CARINOTI
 - PLUM TIS

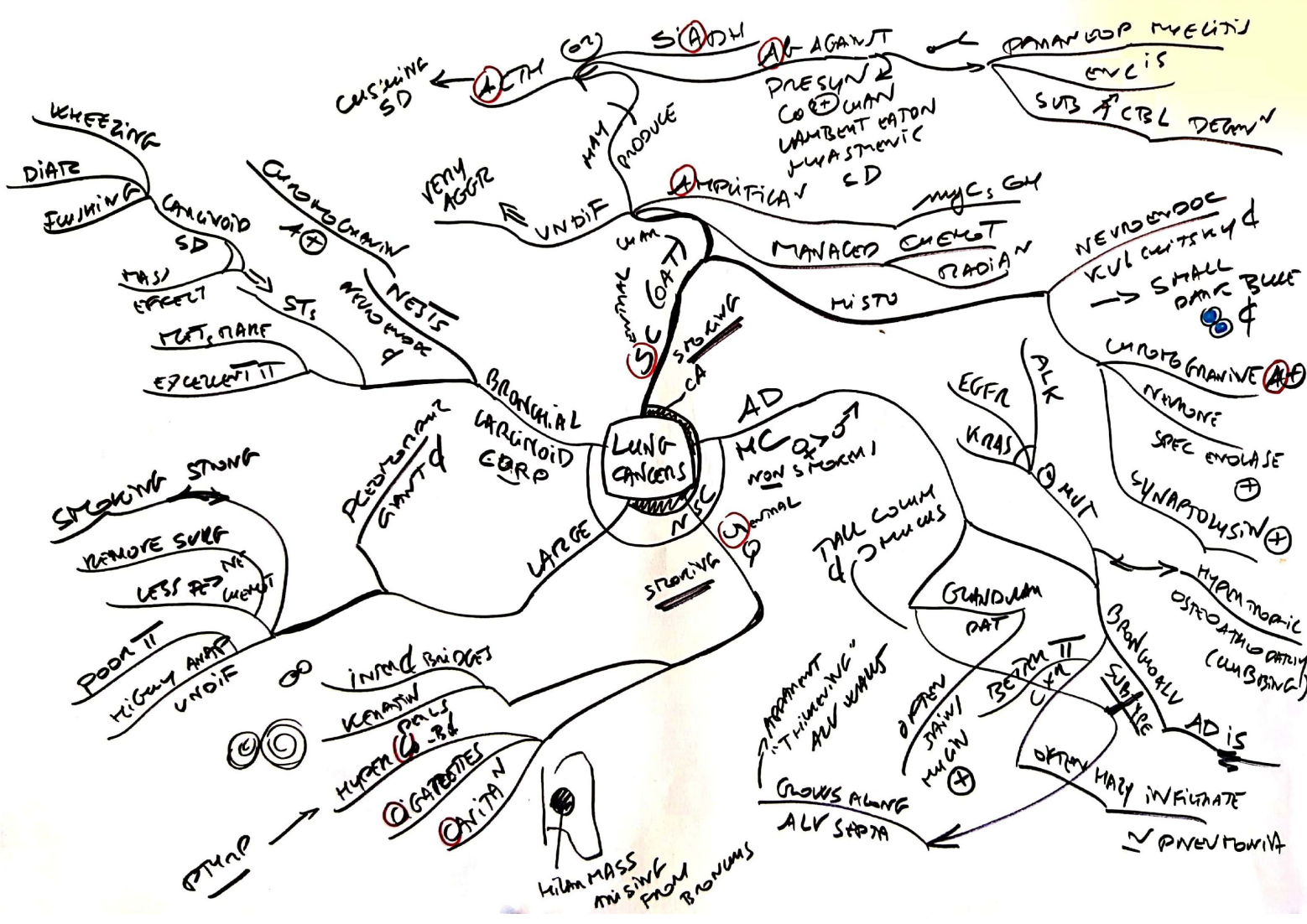



LOCAL EFFECTS







WHEEZING
DIATE
FUSHING
CALCIVOID SD
MASS EFFECT
MET. PAIN
EXCELLENT RT

CUSHING SD
A(TH)
S(ADH)
A(AGANT)
PRESYN & CO(+) UAN
LAMBERT EATON
HYASTHENIC ED
PAINFUL MYELITIS
EVLIS
SUB A CTBL DEGRN

BRONCHIAL CARCINOMA
SQUAMOUS CELL CARCINOMA
ADENOCARCINOMA
NEUROENDOCRINE TUMORS

SMOKING STUNG
REMOVE SURF
LESS RES NET
POOR RT
HIGHLY ANAP
UNDIF
INTRA BRIGETS
KERATIN PALS
HYPER (R)
GAPTES
ONITAN
HILUM MASS MISSING FROM BRONCHUS

VERY AGGR
UNDIF
MAM
PRODUCE
S(ADH)
A(AGANT)
PRESYN & CO(+) UAN
LAMBERT EATON
HYASTHENIC ED
PAINFUL MYELITIS
EVLIS
SUB A CTBL DEGRN

BRONCHIOALVEOLAR CARCINOMA
LUNG CARCINOMA
LARGE
STRONG
TALL COLUMN & MUCUS
AD
MC Q(+) NON SMOKE
EGFR
ALK
KRAS
MIT
GRANULOMAT
BETTER RT
OFTEN STAIN/ MUCIN (+)
GROWS ALONG ALV SEPTA

NEUROENDOCRINE TUMORS
NEUROENDOC
KUL CUTTING & SMALL DARK BLUE
CHROMO GRANINE (+)
NEURONE
SPEC ENOLASE (+)
SYNAPTOSIN (+)
HYPERMORPHIC OSTEOBLASTIC DRUM (UNUSUAL)
BRONCHOVASCULAR AD IS
OFTEN HAY INFILTRATE
PNEUMONIA

MYC5 G4
MANAGED CHEST RADIATION
HISTO
NEUROENDOC
KUL CUTTING & SMALL DARK BLUE
CHROMO GRANINE (+)
NEURONE
SPEC ENOLASE (+)
SYNAPTOSIN (+)
HYPERMORPHIC OSTEOBLASTIC DRUM (UNUSUAL)
BRONCHOVASCULAR AD IS
OFTEN HAY INFILTRATE
PNEUMONIA

NEUROENDOCRINE TUMORS
NEUROENDOC
KUL CUTTING & SMALL DARK BLUE
CHROMO GRANINE (+)
NEURONE
SPEC ENOLASE (+)
SYNAPTOSIN (+)
HYPERMORPHIC OSTEOBLASTIC DRUM (UNUSUAL)
BRONCHOVASCULAR AD IS
OFTEN HAY INFILTRATE
PNEUMONIA

NEUROENDOCRINE TUMORS
NEUROENDOC
KUL CUTTING & SMALL DARK BLUE
CHROMO GRANINE (+)
NEURONE
SPEC ENOLASE (+)
SYNAPTOSIN (+)
HYPERMORPHIC OSTEOBLASTIC DRUM (UNUSUAL)
BRONCHOVASCULAR AD IS
OFTEN HAY INFILTRATE
PNEUMONIA