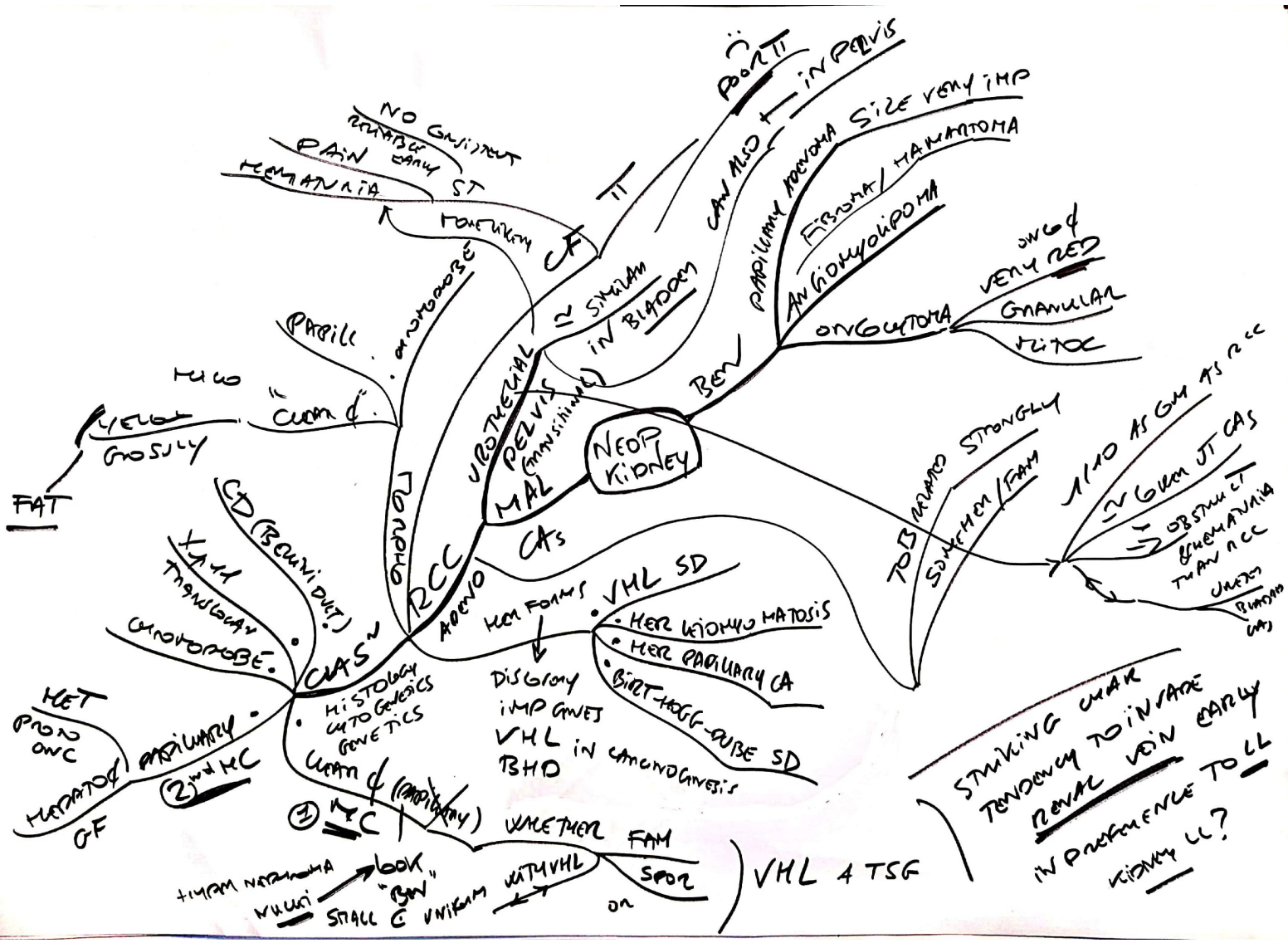
NEOP KIDNEY
BEN
ONCOCYTOMA
VERY RED
GRANULAR
VITOC
ANGIOMYOLIPOMA
FIBROMA / HAMARTOMA
PAPILLARY ADENOMA
SIZE VERY IMP
CAN ALSO ← IN PELVIS
PORTI
MAL
UROTHELIAL
PELVIS (TRANSITIONAL)
≃ SIMILAR IN BLADDER
CAs
RCC
ADENO
ONCOCYTOMA
PAPILL
CHROMOPHOBE
CLEAR ¢
MUCO
CLEAR ¢
GLOSSY
FAT
CD (BENIGN DUCT)
XP11 TRANSLOCAT
CHROMOPHOBE
CAS
HISTOLOGY
CYTOGENETICS
GENETICS
CLEAR ¢ (PAPILLARY)
① MC
② 2nd MC
PAPILLARY
HEPATOC
MET
PROM ONC
GF
TT
CF
NO CONSISTENT
REMARKABLE EARLY ST
PAIN
HEMATURIA
HOMETRICS
TOB HEARD STRONGLY
SOMETIMES / FAM
1/10 AS COMMON AS RCC
≃ GREEN JT CAs
⇒ OBSTRUCT
HEMATURIA
THAN RCC
UNLESS
BIRDS
CAS
VHL SD
HER FORMS
• HER KIDNEY MATOSIS
• HER PAPILLARY CA
• BIRT-HOGG-DUBE SD
DISCOVERY
IMP GENES
VHL IN CARCINOGENESIS
BHD
STRIKING CHAR
TENDENCY TO INVADE
RENAL VEIN EARLY
IN PROGRESSION TO LL
KIDNEY LL?
VHL A TSG
WHETHER FAM
SPOR
OR
WITH VHL
+ HYPER NEPHROMA
WILMS
LOOK "BEN"
SMALL C VARIANT

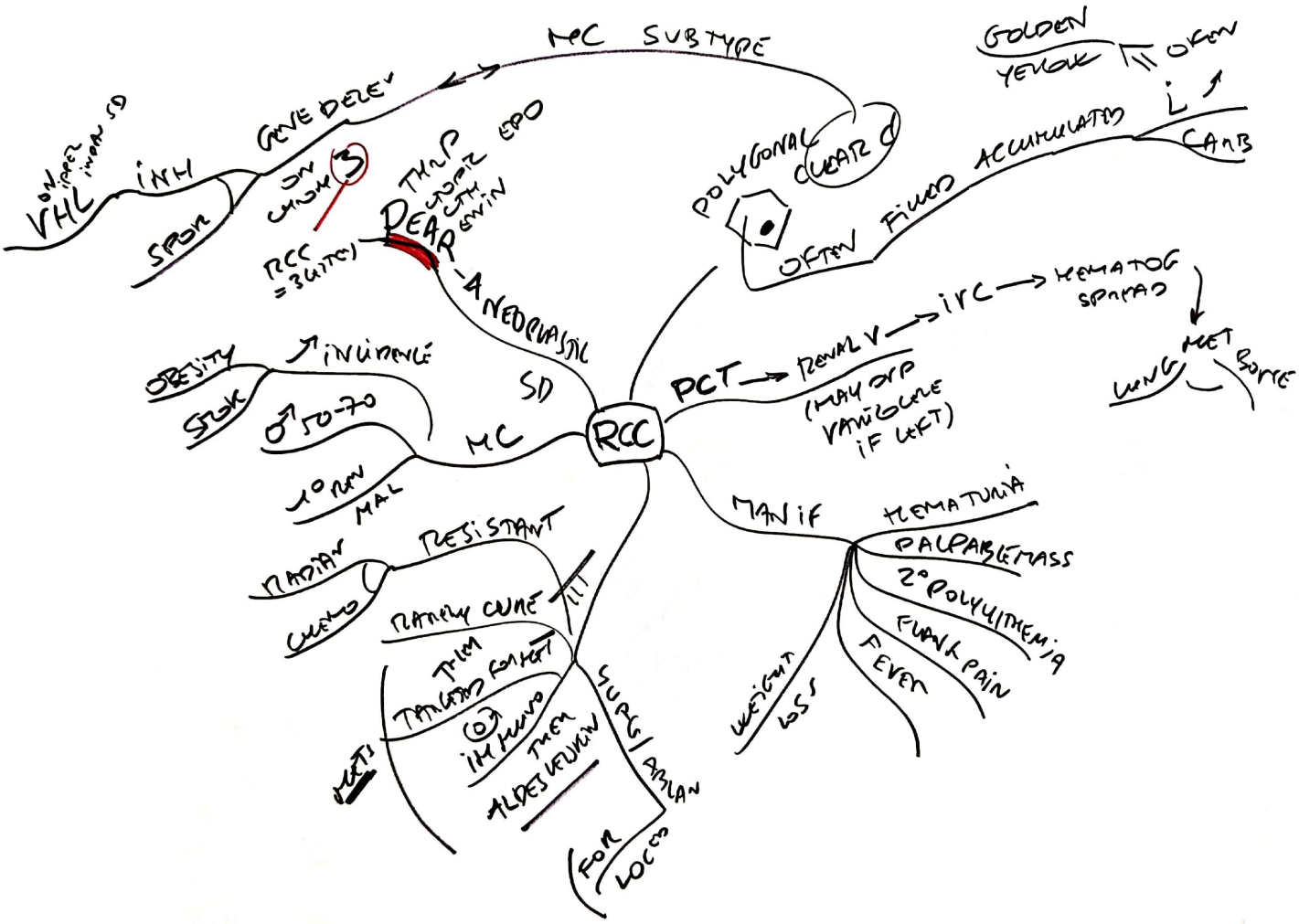
RCC
MC SUBTYPE
GOLDEN YELLOW
OFTEN
CLEAR CELL
POLYGONAL
OFTEN FILLED ACCUMULATED
CARB
VHL
ONCOGENE
INHERIT
INVOLVED
SD
INH
SPOR
GENE DELET
3
THAP
EPO
DEAR
-A NEPHRIASIC
SD
RCC = 3 HITS
PCT → RENAL V → IVC → HEMATOG SPREAD
(MAY OFP VARICOCELE IF LEFT)
LUNG
MET
BONE
OBESITY
SEEK
INCIDENCE
♂ 50-70
MC
10 NORM MAL
RADIAT
CHEMO
RESISTANT
RARELY CURE
THEN
TARGETED THERAPY
IM THERAPY
THEN
ALDESLEUKIN
HIT!
SURG / ABLAN
FOR LOCAL
MANIF
HEMATURIA
PALPABLE MASS
2° POLYCYTHEMIA
FLANK PAIN
FEVER
WEIGHT LOSS

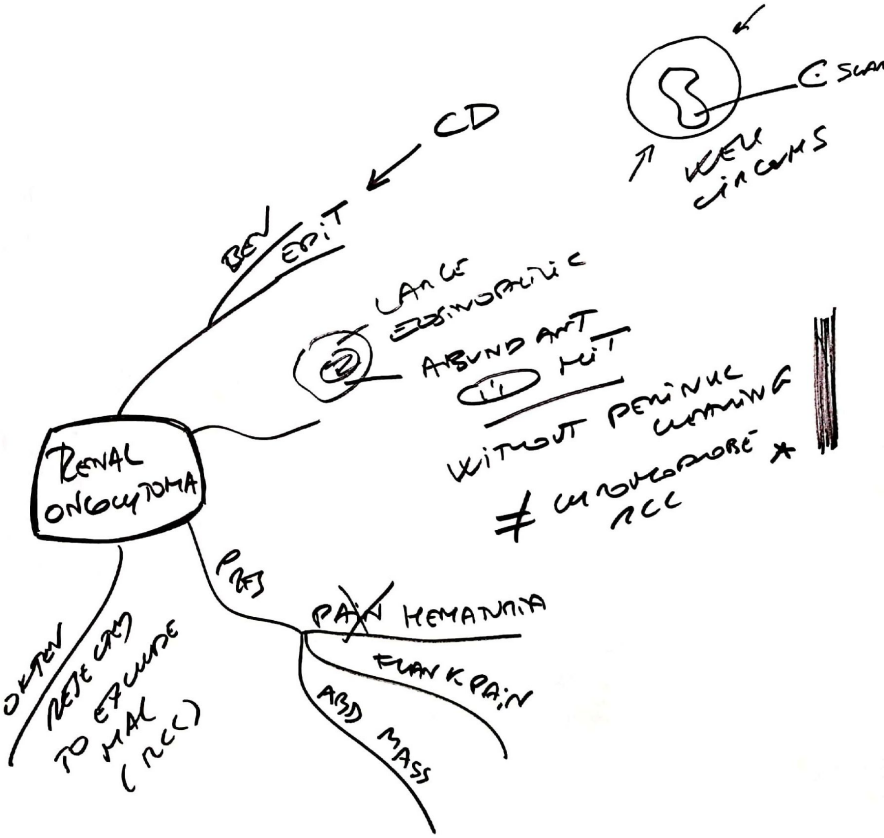
RENAL ONCOCYTOMA
BEN
EPIT
CD
LARGE
EOSINOPHILIC
ABUNDANT
PINK
WITHOUT PERINUCLEAR CLEARING
≠ CHROMOPHOBE RCC *
C SCAN
WELL CIRCUMS
PRES
PAIN
HEMATURIA
FLANK PAIN
ABD MASS
OKTEN
RETROGRD
TO EXTENDE
TO RAL
(RCC)

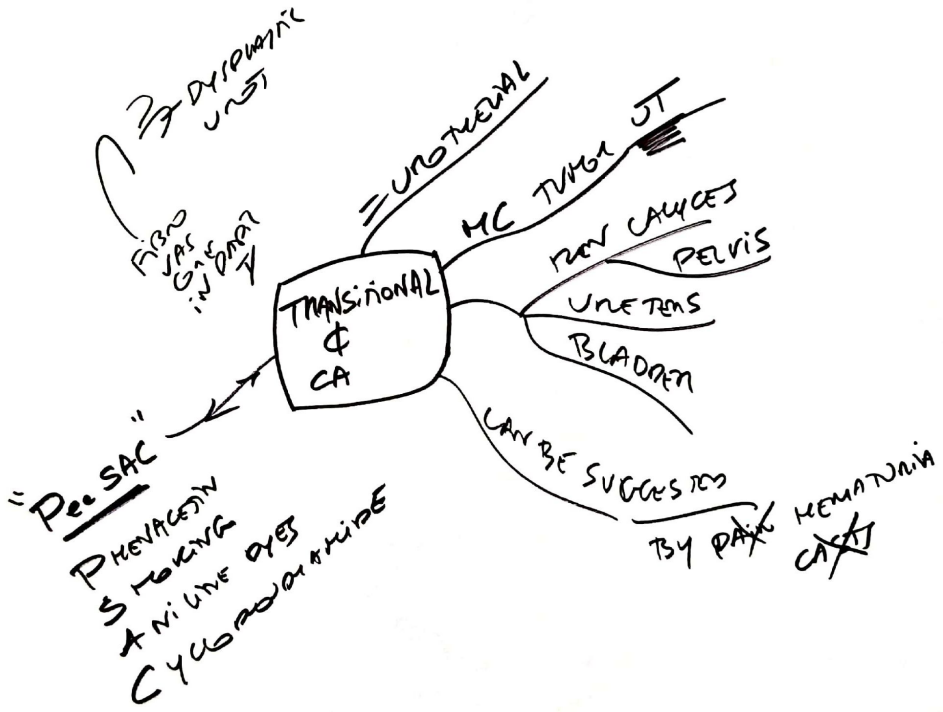
TRANSITIONAL
&
CA
= UROTHELIAL
MC TUMOR UT
RENAL CALYCES
PELVIS
URETERS
BLADDER
CAN BE SUCCESSIVE
BY PAIN
HEMATURIA
CA
Dysplastic urot
FIBRO VAS CONGENITAL
"Pee SAC"
P PHENACETIN
S SMOKING
A NITROSAMINES
C CYCLOPHOSPHAMIDE