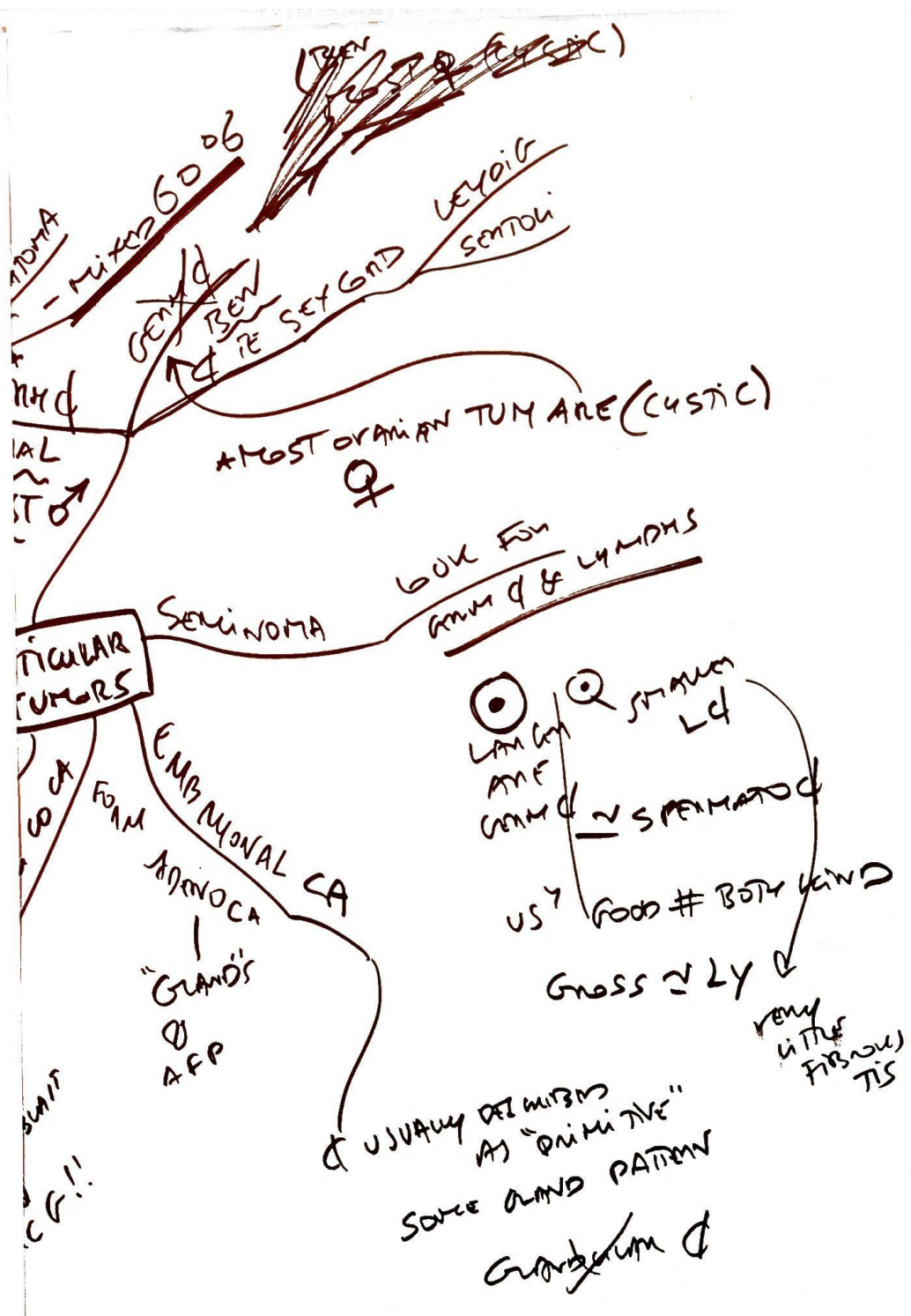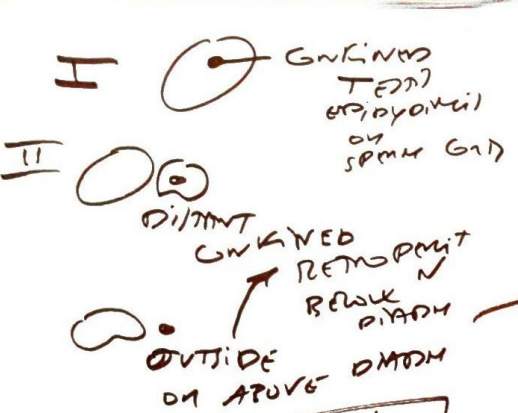


MALE



NOT MET IN MAJINAL BUT AMIADIC
RETROPERIT
PLACE
BUT BE

STAGING
CHORIOCARCINOMA
EMBRYONAL SEMINOMA
YOLK SAC
TERATOMA
- MIXED GONADOBLASTOMA

TESTICULAR TUMORS

SEMINOMA
MOST ORARIAN TUM ARE (CYSTIC)
♀
LOOK FOR
GROSS & LYMPHS

SEX GAD
SEMINOMA
LEYOIG
SENTOLI

MOST OF MAL & DEV (GONADIN CA)
GROSS & LY
US? GOOD # BOTH KIND
USUALLY DETECTED AS "PRIMITIVE"
SOURCE AND PATERN
GROSS & LY

TERATOMA
YOLK SAC
EMBRYONAL TUM
MIXED GONADOBLASTOMA
MIXED GONADOBLASTOMA
MIXED GONADOBLASTOMA

EMBRYONAL CA
"GRAND'S" APP
FORM

US? GOOD # BOTH KIND
GROSS & LY
USUALLY DETECTED AS "PRIMITIVE"
SOURCE AND PATERN
GROSS & LY
VERY LITTLE FIBROUS TISSUE

TESTIS
OVARY
SCROTUM
OVARY
BODY

TRIPROBARI & HCG!!

II

DIFFERENT GERM CELL
RETROPERIT
BEHIND
OUTSIDE OR ABOVE DTDH

CHORIOCARCINOMA
EMBRYONAL SEMINOMA
YOLK SAC
TERATOMA
- MIXED GONADOBLASTOMA

MAL
MOST ♂

SEMINOMA

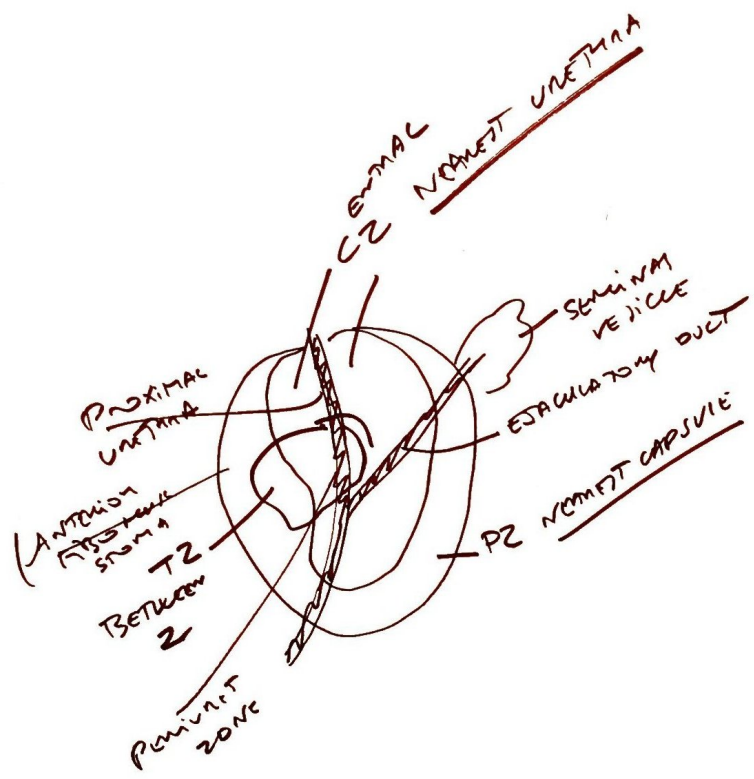
EMBRYONAL CA

US? GOOD # BOTH KIND
GROSS & LY

USUALLY DETECTED AS "PRIMITIVE"
SOURCE AND PATERN
GROSS & LY

TESTIS
OVARY
SCROTUM
OVARY
BODY

TRIPROBARI & HCG!!



CZ
T2
PZ

