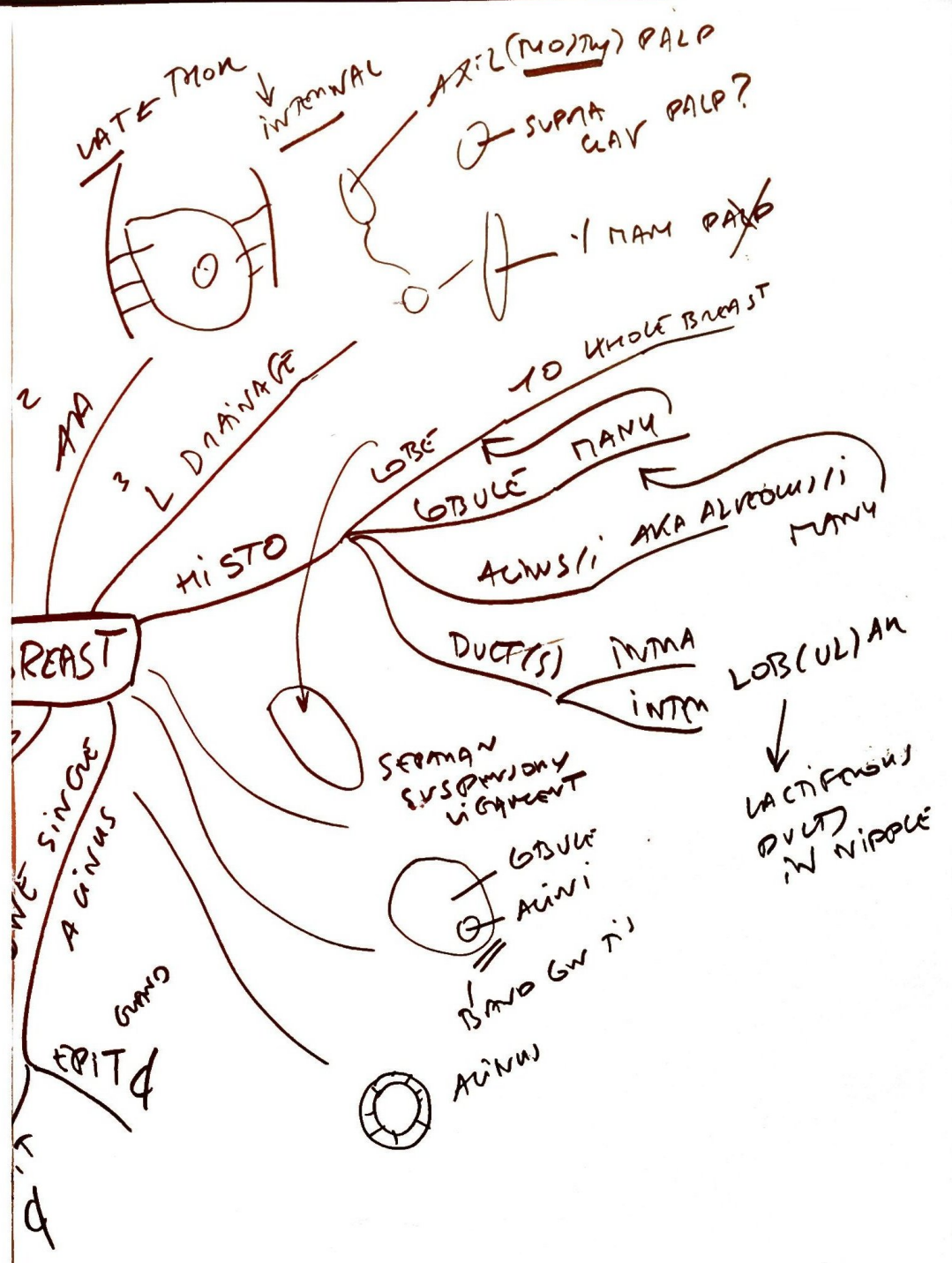
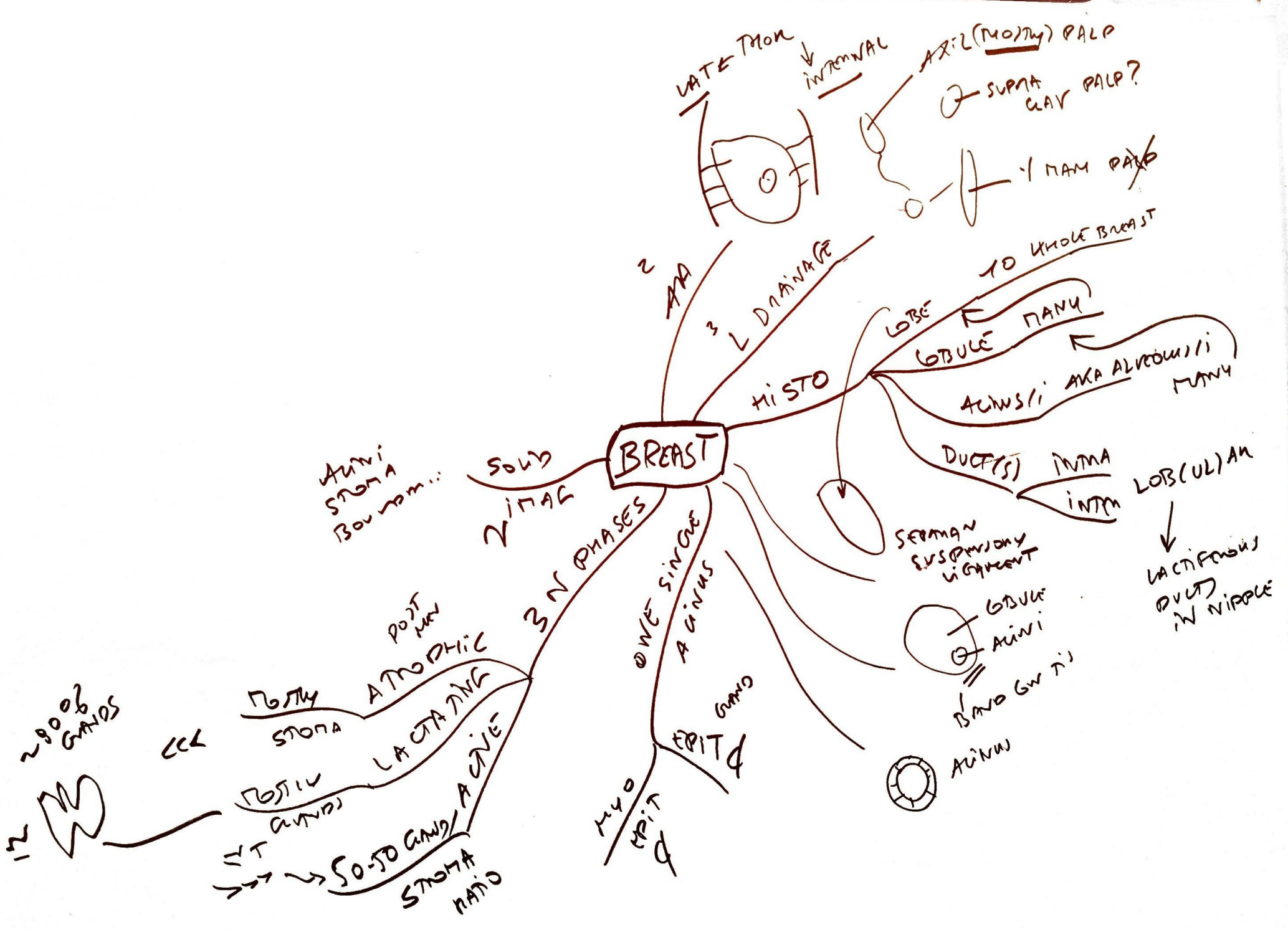


BREAST



BREAST



~90% GRAIDS

CC

POST MEN STOMA

ATROPHIC

LACTATING

POST MEN STOMA

LACTATING

STOMA

3 N PHASES

ONE SINGLE ACINUS

EPIT

MYO EPIT

LATE MEN

INTERNAL

AXIL (MOUTH) PALP

SUPRA CLAV PALP?

2 AA

3 L DRAINAGE

HISTO

LOBULE

TO WHOLE BREAST

LOBULE PANU

ACINI AKA ALVEOLARI MANY

DUCTS

INTRA

INTM

LOB(UL)AN

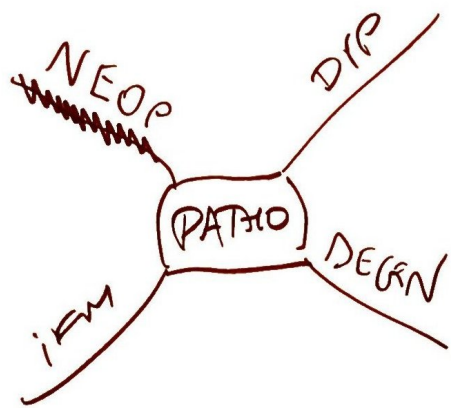
LACTIFEROUS DUCT IN NIPPLE

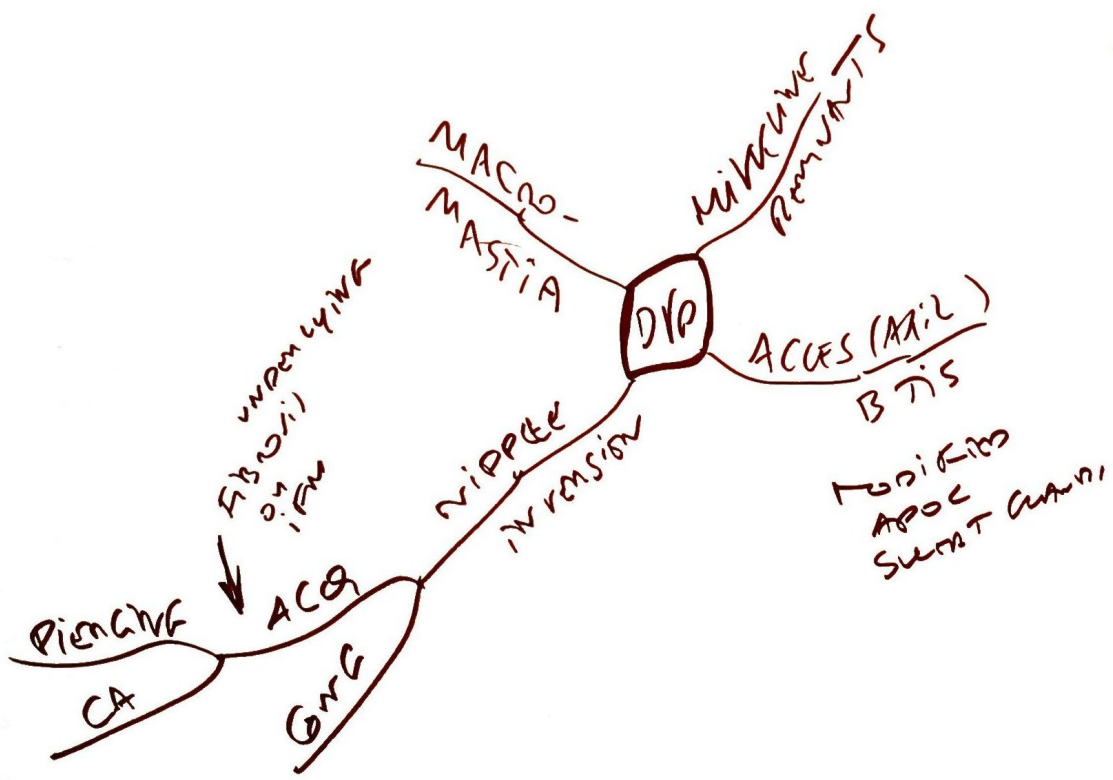
SERVAN SUSPENSORY LIGAMENT

LOBULE ACINI

DAVID GW TI

ACINI



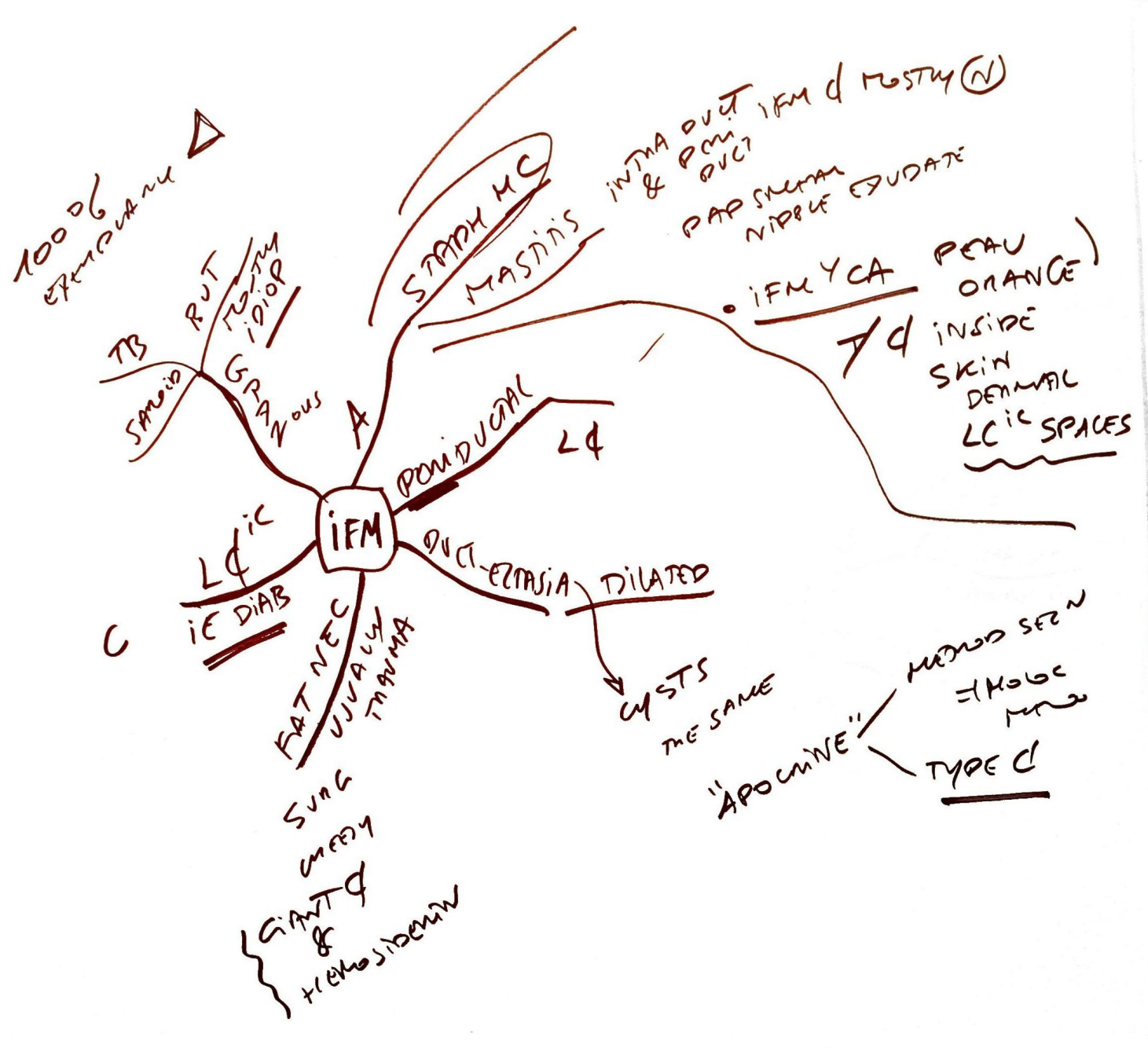


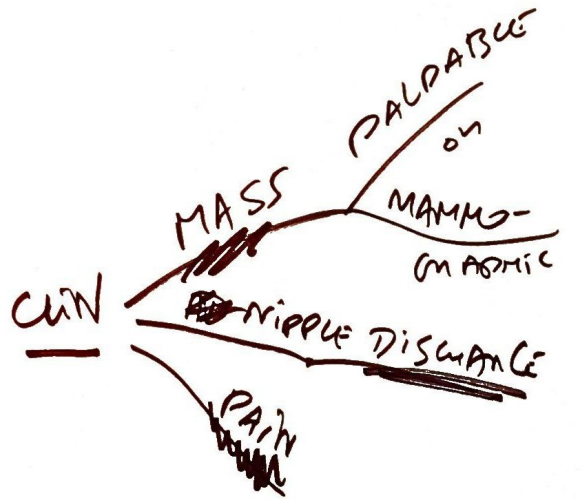
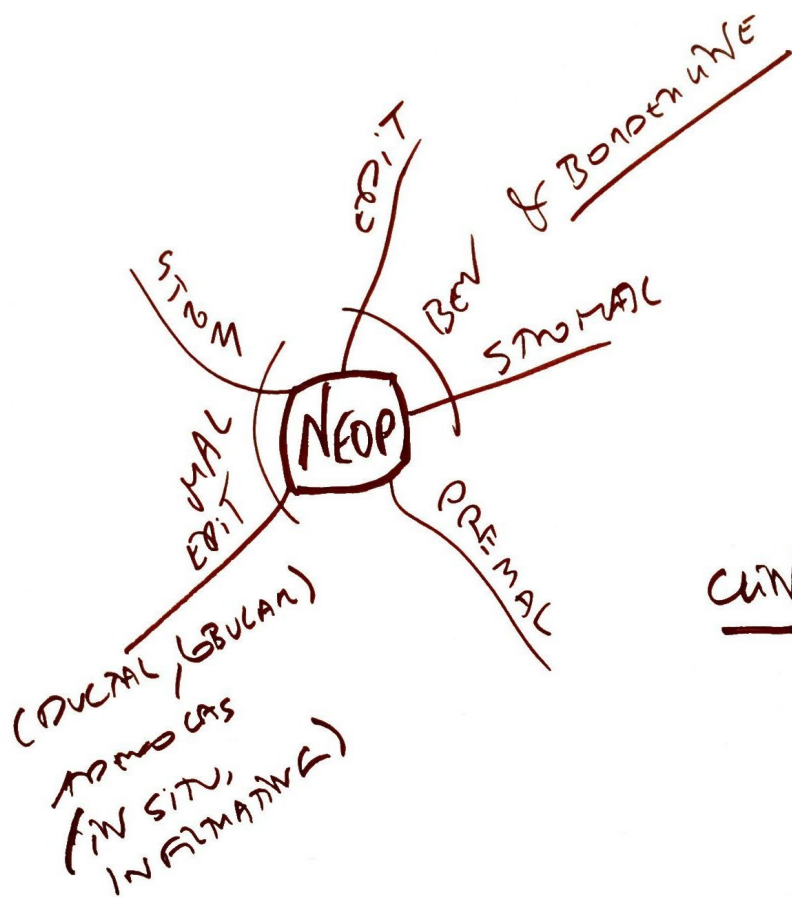
STOMA \rightarrow GLANDS
BUT GLANDS & ALVI
STILL PRESENT

ATROPHY
N
POSTMEN
E WITH NORMAL

* - MOST CAS OCCUR
IN ATROPHIC POSTMEN
X BURNIT


DEGEN





NEON Δ PAPILLOMA
MAL ON FOLICLE
BENIGN

- 1) WELL DIFF ++
- 2) YOUNG ON ♀
- 3) ALWAYS BEN
- 4) CAN FIBROSE ON CALCULI WITH AGE



PAPILLOMA

FIBROADENOMAS

⇒ MENINGEAL SUPRABALLS

★ BEN!

MYOEPIT

(RADIAL SCAR) COMPLEX

SCARY (100% BEN)

"SCISSORING" ADENOSIS

DUCTAL HYPERPLASIA

SUCROSI CAN BE FOUND FOR DUCTAL HYPERPLASIA

- NOT MYOEPIT
- ATYPIC

NEOP (BEN) EPIT

FIBROID + CYSTS

ANA FIBROCYTIC PROLIF

WALL BASKET

FIBROSIS

US

PROSE METAPL

CA

ACINI/LOBULE

ADENOSIS

CYST

FIBROSIS

US

PROSE METAPL

CA

ACINI/LOBULE

ADENOSIS

AMPHICAL

PROLIF

HYPERPLASIA

SCISSORING ADENOSIS

PAPILLOMA

① FIBROSIS ADENOSIS

② SCISSORING ADENOSIS

③ AMPHICAL

④ FIBROADENOMA

⑤ FIBROSIS

⑥ US

⑦ PROSE METAPL

⑧ CA

⑨ ACINI/LOBULE

⑩ ADENOSIS

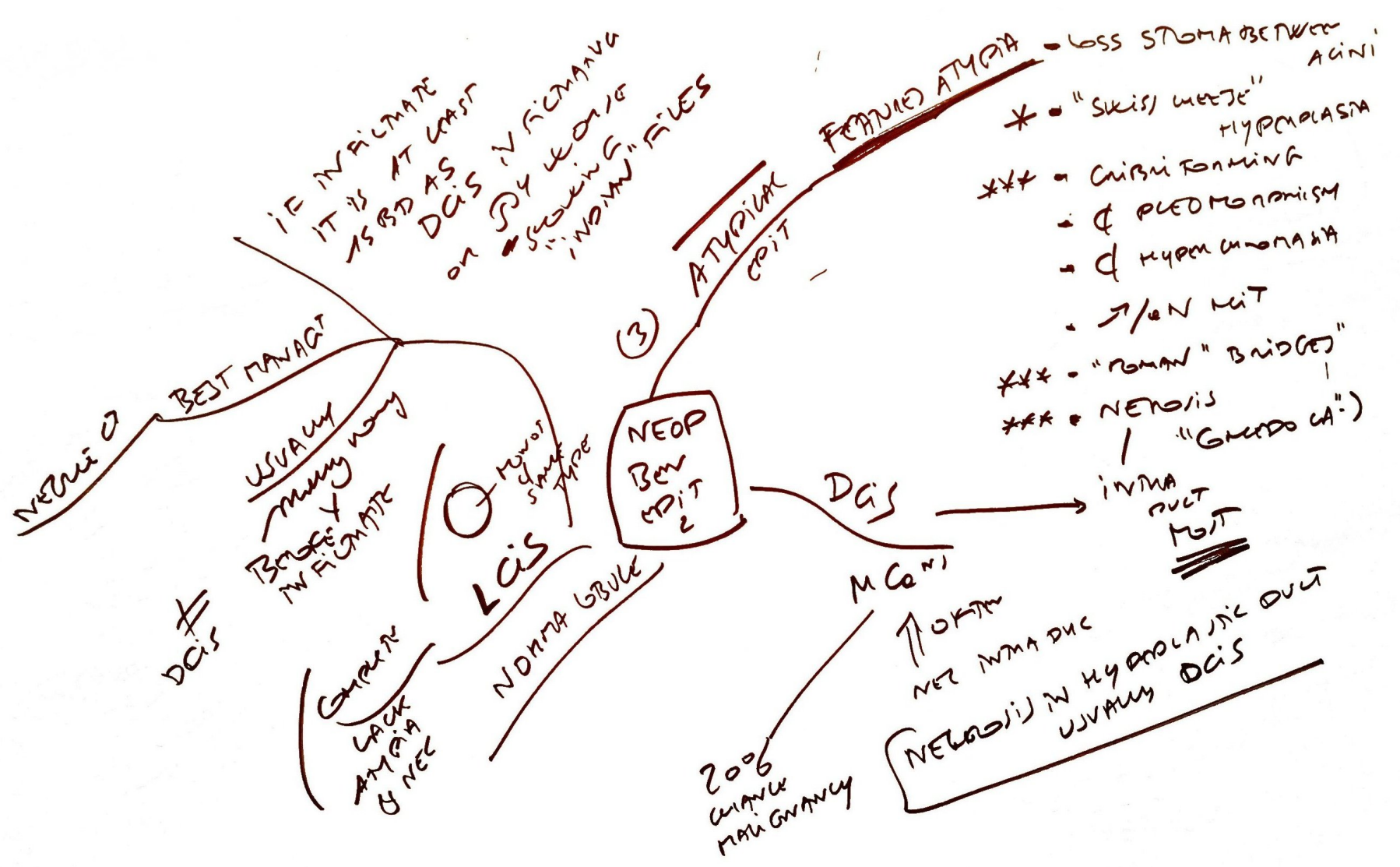
⑪ AMPHICAL

⑫ PROLIF

⑬ HYPERPLASIA

⑭ SCISSORING ADENOSIS

⑮ PAPILLOMA



- IN SITU
- EARLY DISRUPT TBL BM
- STROM INFILTRATION
- L4 VES
- SENTINAL LN MET
- FOCAL
- ABS JM IFM U
- DISTANT MET

DS OD S

(PREDICT RT TO TRASTUZUMAB MET IT)

OVER EXP R

OVER EXP PRODUCT ON AMPLIFICATION 25-300% B CANCER

of ov cancer
OVARY
STOM

STAGING

BREAST CANCER

TNM
Bio
OBENAV

Her2, AKA Her2 - Neu

ERA / (PRA)

17q11.2-12

HISTO DEFENSE OF GENOME OF GEN HEALTH OF IMM AGE

PROGNOSTIC

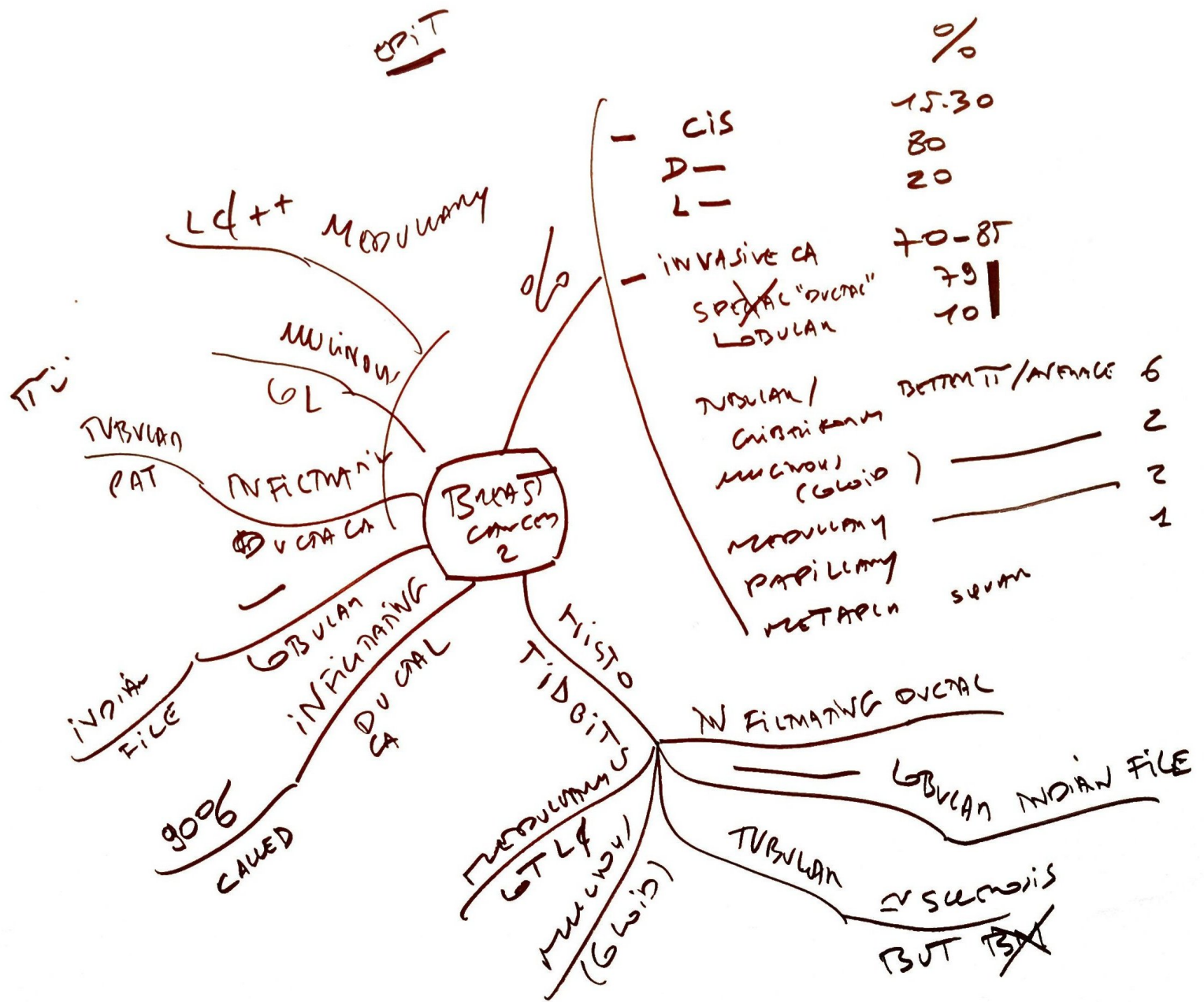STAGING

ESP POS ON NEG LN TNM etc...

RF

- AGE
- EARLY MENARCHE
- 1ST LIVE BIRTH
- 1ST BIRTH SPAN
- BIOPSIES
- RACE CAUCASIAN
- EXPOSURE, PREGNANT LATE MENOP
- RADIATION
- CA GENETICS LAT B or WIDOW
- COG
- DIET FAT
- OBESE
- EDM
- LAM BREASTING
- PRIOR PREGNANCY
- TOXINS
- TOB
- ABORTIONS?

EPIT



NEOP
STROMAL

U510 - "SARCOMA" PHYLLOID
= PHYLLOID T
= GIANT
FIBROBLASTOMA
SARCOMA
SAME NAME!

Concomitant Hydrone
CA 4 of 6 of ♀
~~LORDS~~
BLUNT DUCTS