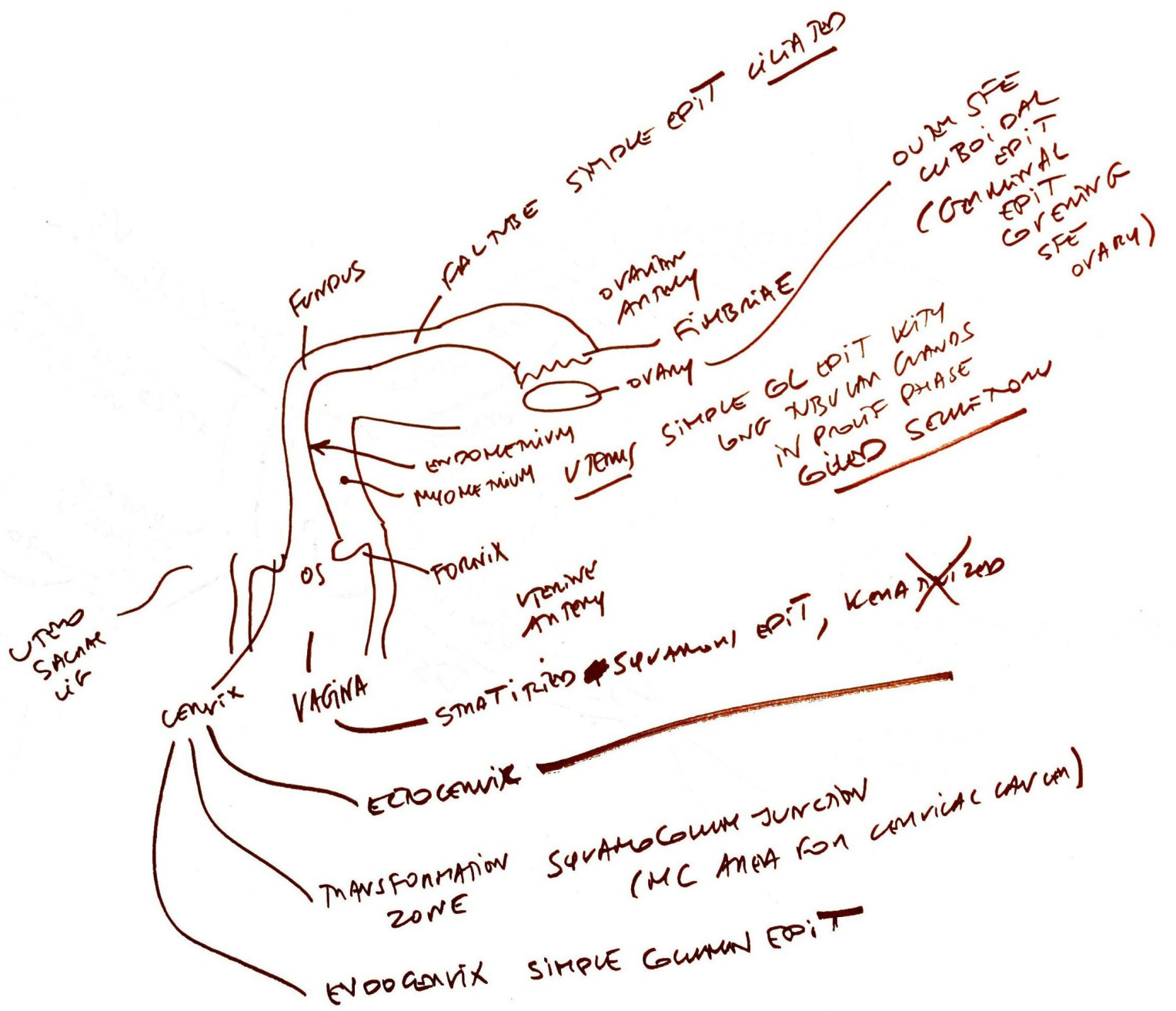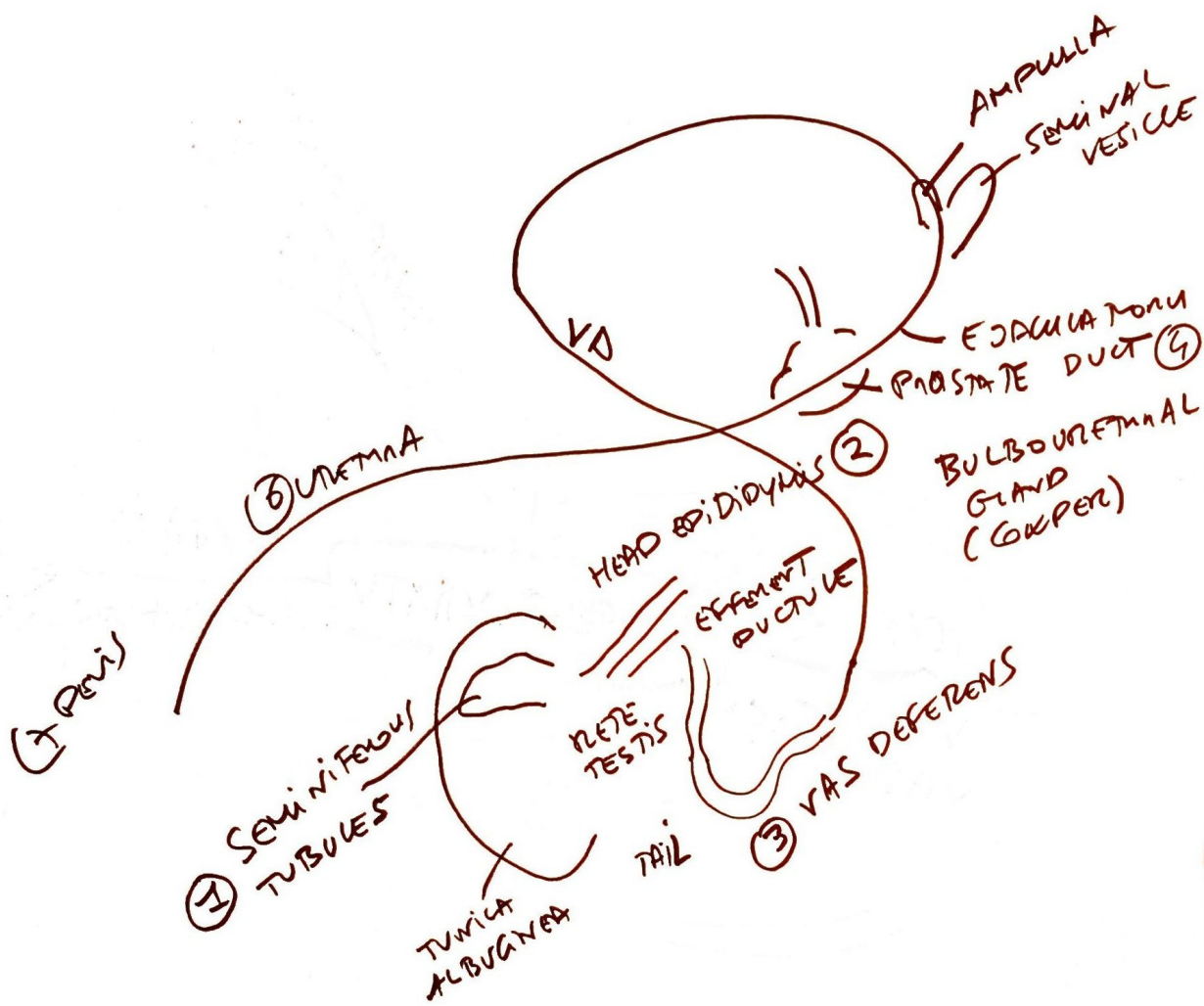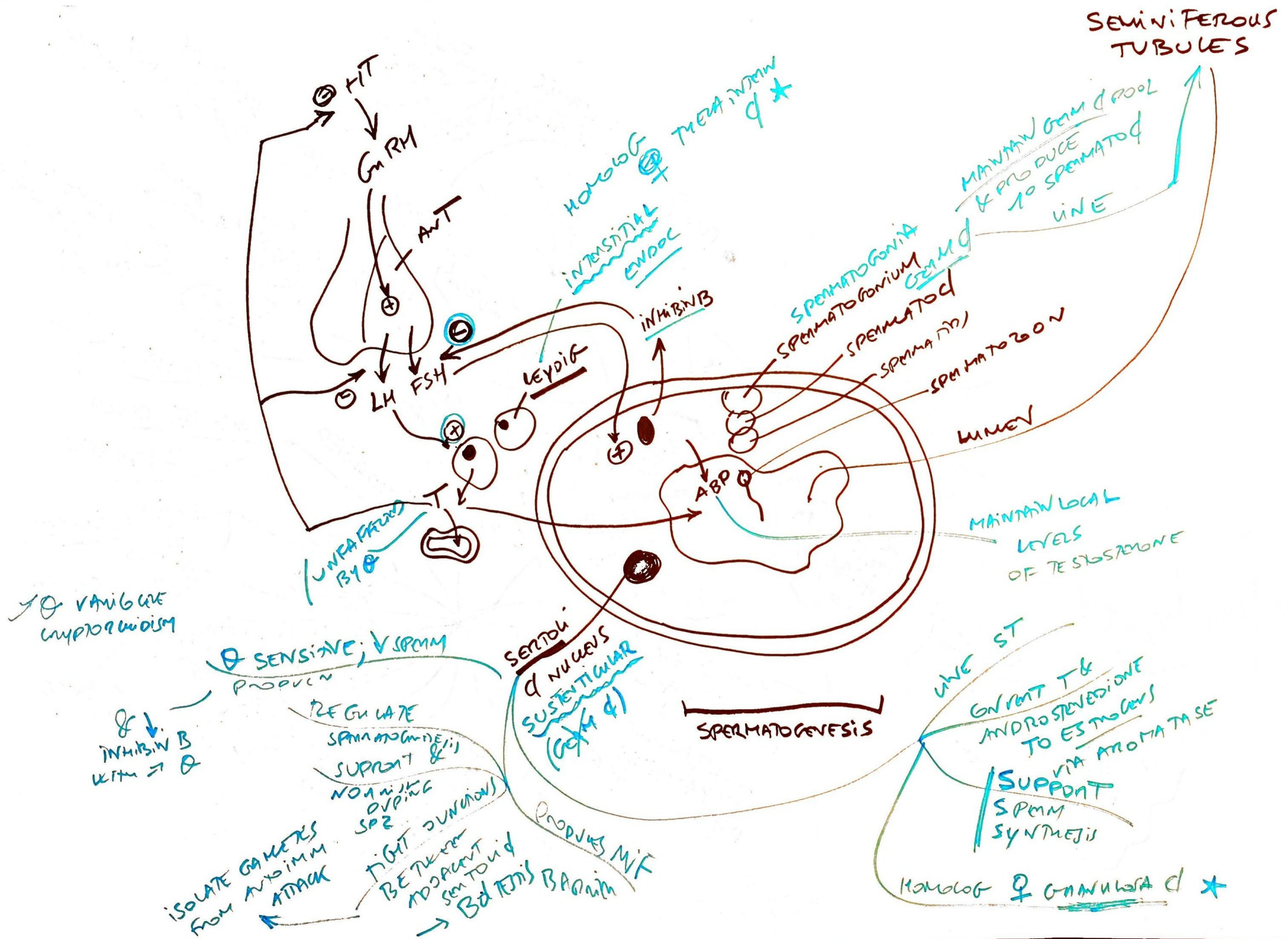


5 NOTHING
6 URETHRA
7 PENIS

SEM TUB
EPID
VAS DF
ED
V SEM
URETHRA
PENIS



SEMINIFEROUS TUBULES

MAINTAIN GERM CELL POOL & PRODUCE 10 SPERMATID

SPERMATOGONIA
SPERMATOGONIUM
SPERMATID
SPERMATOZOON

MAINTAIN LOCAL LEVELS OF TESTOSTERONE

SUPPORT SPERM SYNTHESIS VIA AROMATASE

HOMOLOGOUS TESTICULAR AND OVARIAN

→ & VARIATION UNPRODUCTION

SENSITIVE; ↓ SPERM PRODUCTION

↓ INHIBIN B WITH →

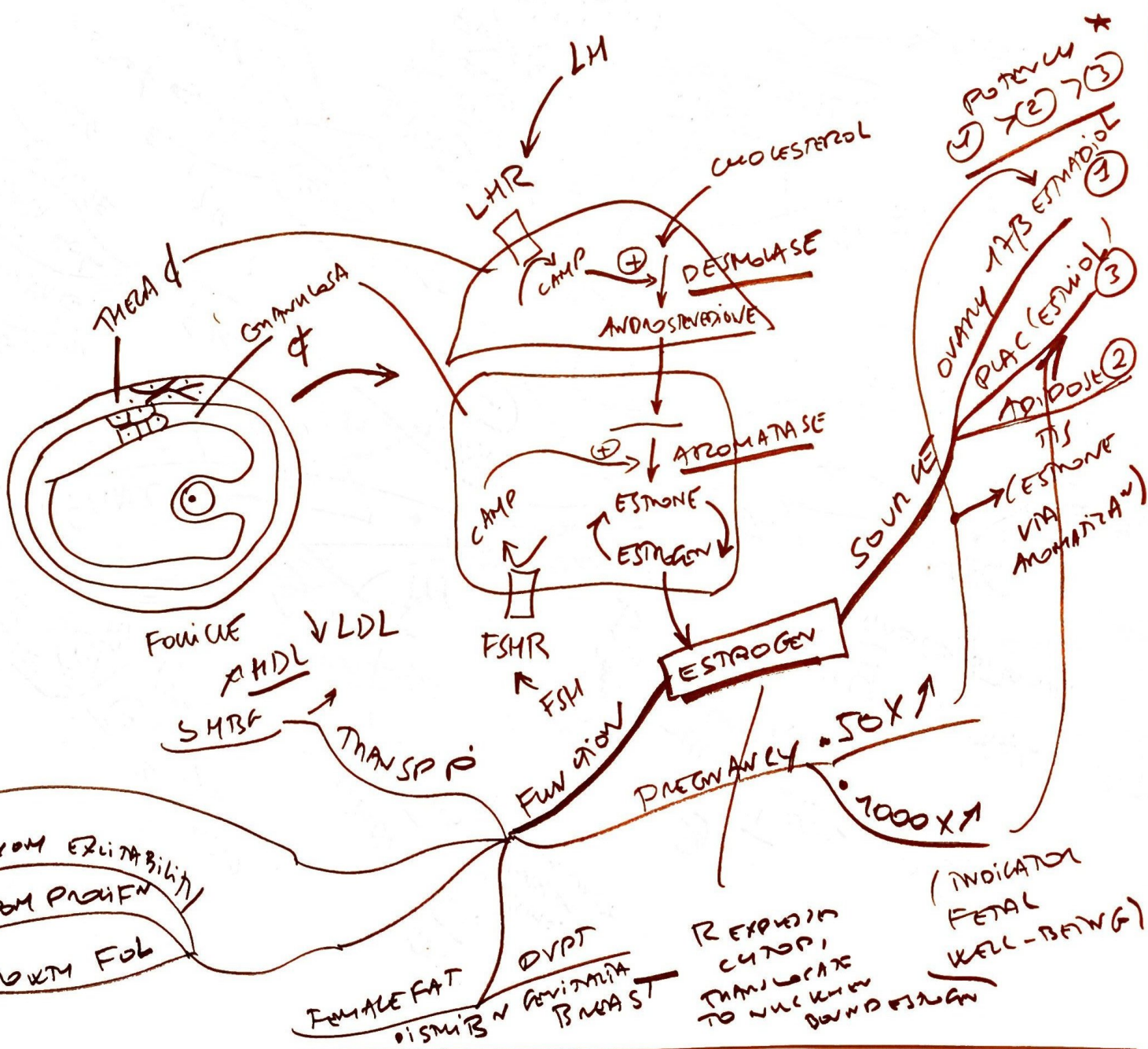
REGULATE SPERMATOGONIA SUPPLY & NON-MITOTIC DIVISIONS

ISOLATE GAMETES FROM IMMUNE ATTACK

TIGHT BARRIER BETWEEN ADJACENT SEMINAL FLUID → BLOOD BARRIERS

PRODUCES MIF

SPERMATOGENESIS



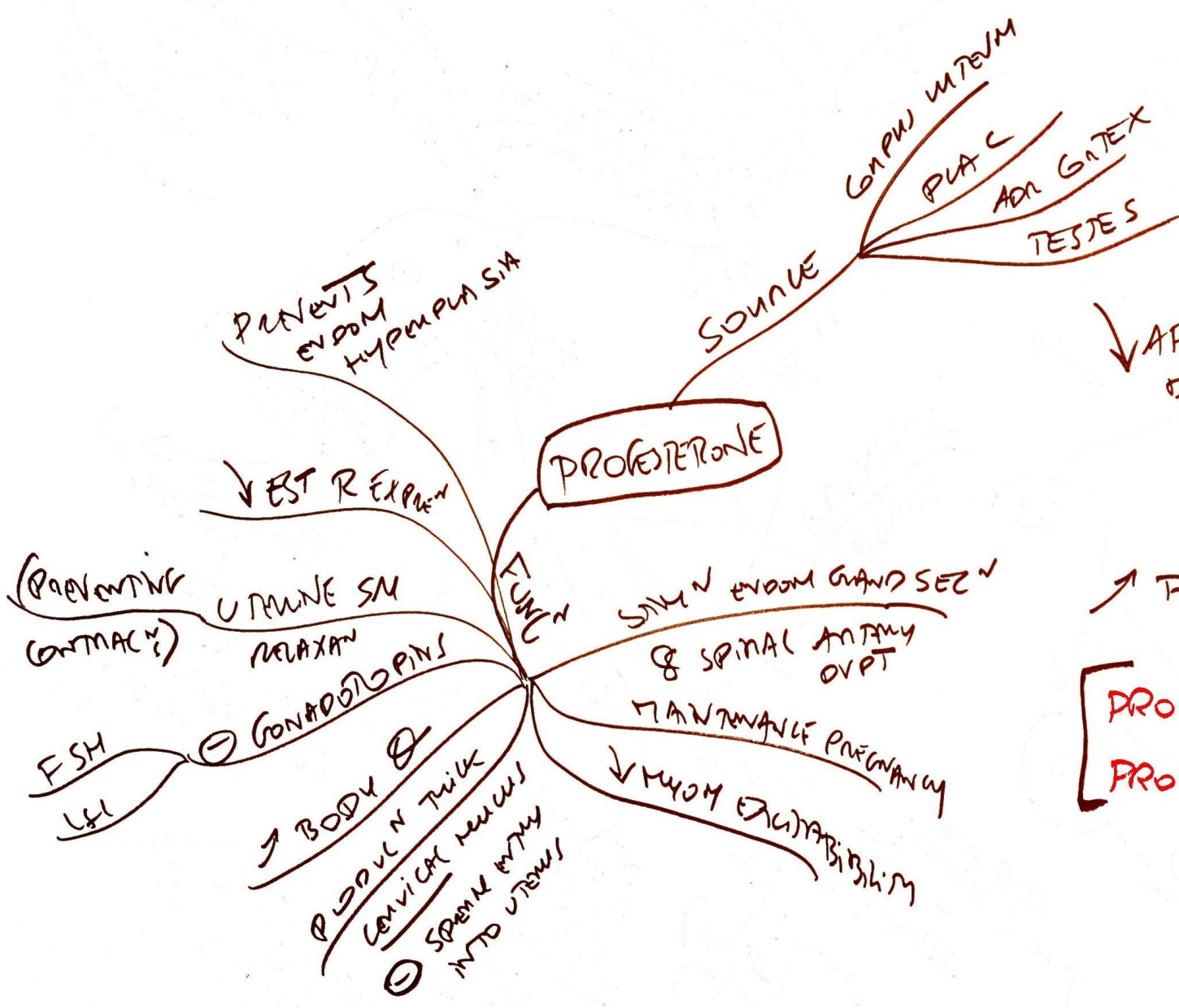
FB \ominus FSH & LH
 THOR LH
 SVAG-
 SATULAN
 PRL SEMEN

UPREG \wedge EST
 LH
 PDR
 R
 \uparrow MYOM EXITABILITY
 ANDAM PROHFN
 GROWTH FOL

FEMALE FAT
 DISTURB \wedge GENITALIA
 BREAST

REPRODUCTION
 TRANSLATE
 TO NUCLEUS
 DOWN REGULATION

(INDICATOR
 FETAL
 WELL-BEING)



↓ AFTER DELIVERY
 DESTINY PRL
 ↓
 LACTAN
 ↑ P INDICATIVE OF OVULATION
 [PROGESTERONE IS PRO-GEST
 PROLACTIN IS PRO-LACTATION]

CON MITTZ
APPROX 15

PROUT
INITIAT
FOL SURVIVE RUPT
FAL TUBE SWIMAN

CRASH

MITTSUMENZ

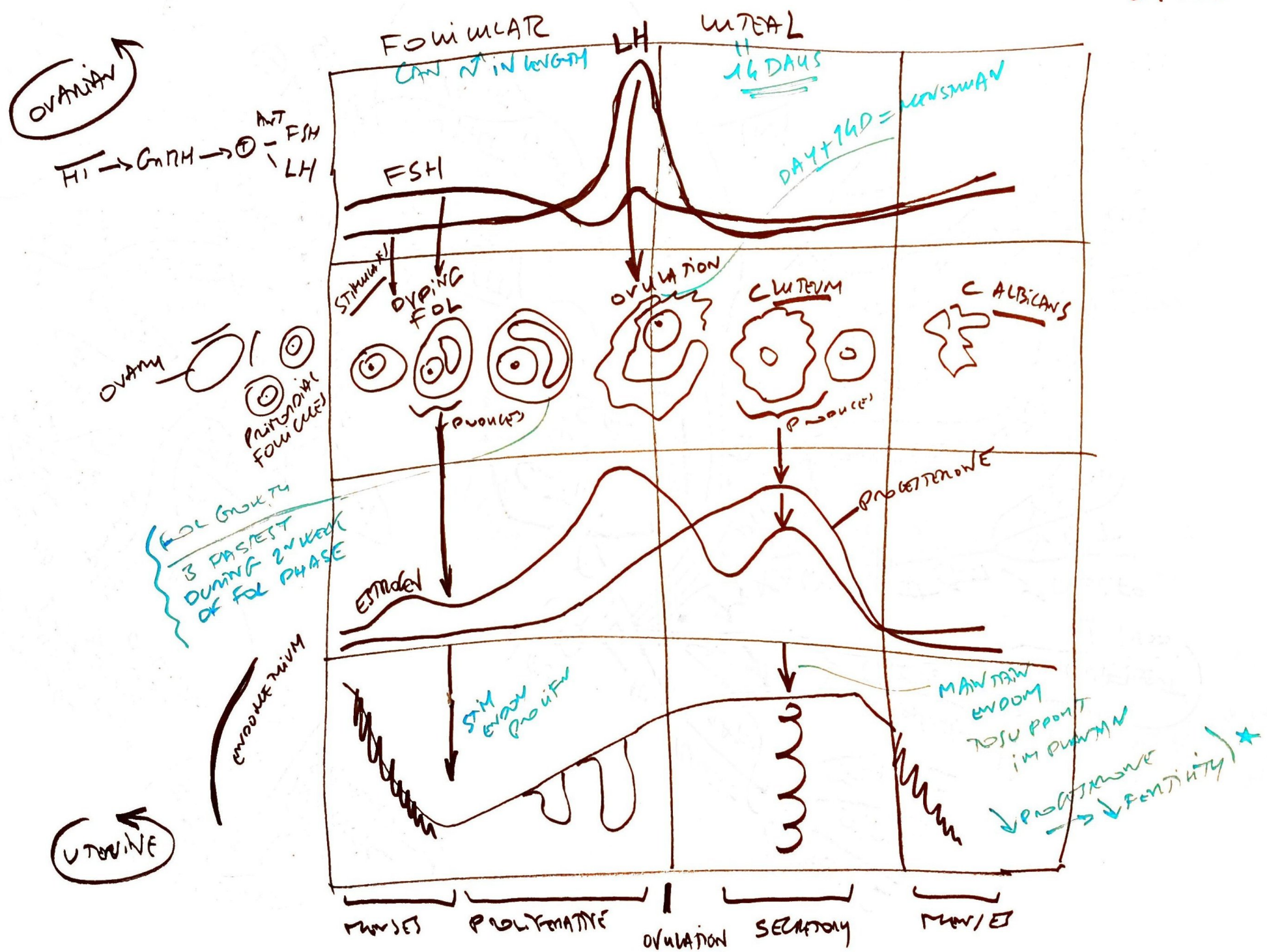
MAXIMT
MID CYCLE
OVUL PAIN
("MIDDLE MUNT")

OVULATION

TEMPERATURE

EST
GROW R ON ANT PIT
EST SURVIVE THER ALL REVERSE
OVULAN (RUPTURE FOL)

MEYNSMAL CYCLE



OVARIAN

HP → GnRH → Ant. Pit. → FSH, LH

OVARY
Primordial Follicles

FOL GROWTH IS FASTEST DURING 2ND WEEK OF FOL PHASE

UTERINE

ENDOMETRIUM

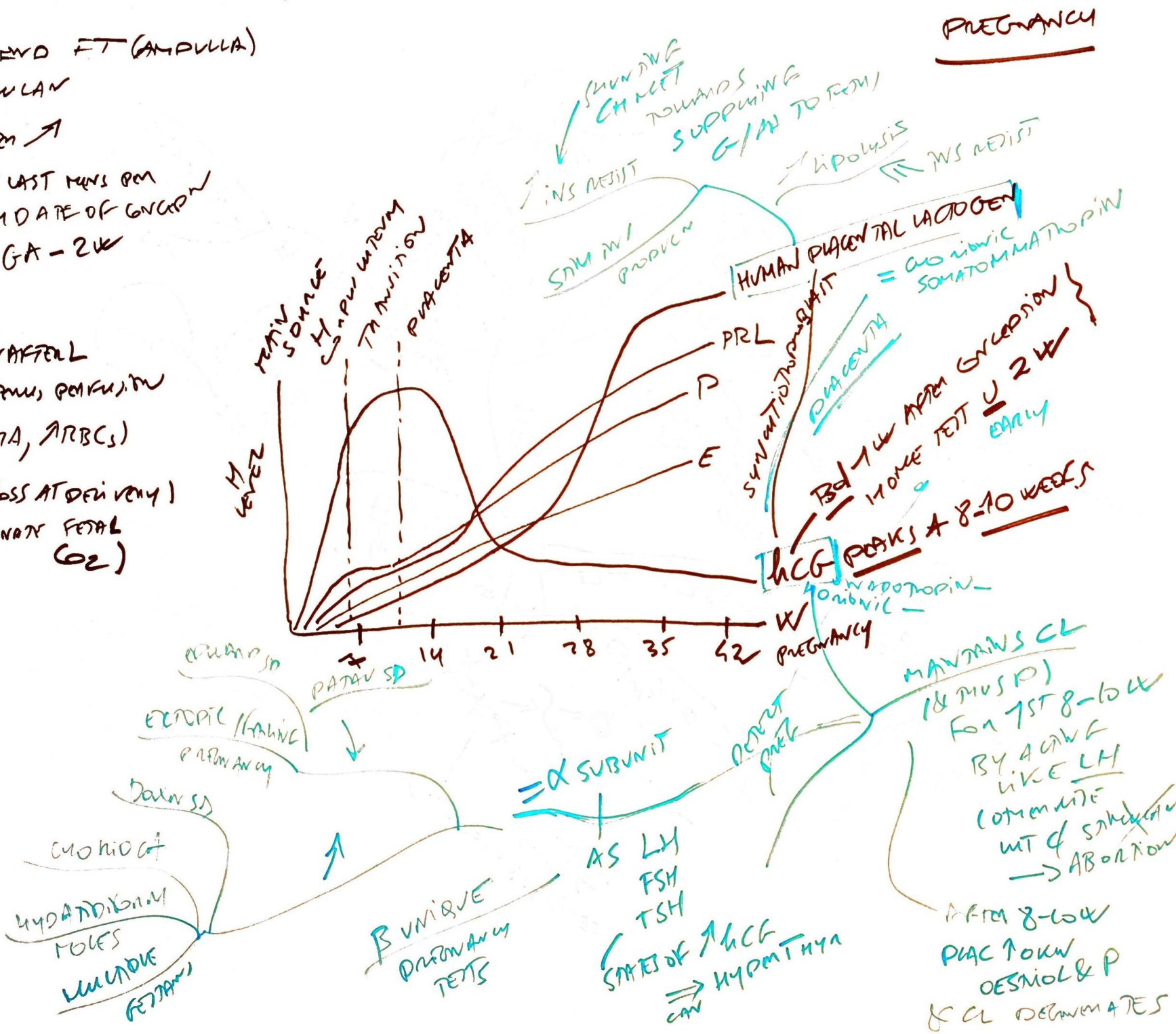PHASES: PROLIFERATIVE | OVULATION | SECRETORY | MENSTRUATION

MAINTAIN ENDOMYOTRIUM PROPT. IN PHASE → ↓ PROGESTERONE → ↓ FERTILITY *

- FERTⁿ MC UPPER END FT (AMPULLA)
- WITHIN 1 D OVULAN
- IMPLANTAN GD AFTER \uparrow
- AGE $\left\{ \begin{array}{l} \text{GESTATIONAL DATE LAST MENS PER} \\ \text{EMBRYONIC FROM DATE OF CONCPⁿ} \end{array} \right.$
- GA - 2W

ADAPTATIONS

- \uparrow CO \uparrow PULS \downarrow AFFERL
- \uparrow HPL \rightarrow PLAC & UTERUS PERFUSION
- ANEMIA (\uparrow PLASMA, \uparrow RBCs)
- HYPONATREMIA (\downarrow BALSS AT DELIVERY)
- \downarrow VENTⁿ (ELIMINATE FETAL CO₂)



PREGNANCY

MAINTAINS CL (CH & CH)
FOR 1ST 8-10W
BY A GONADOTROPIN LIKE LH
(COMMONITE UNIT OF SAME GONADOTROPIN)
 \rightarrow ABORTION
AFTER 8-10W
PLAC PRODUCE OESTROGEN & P
& CL DETERMINATES

α SUBUNIT
AS LH
FSH
TSH
STATES OF \uparrow HCG
 \Rightarrow HYPERTHYR

β UNIQUE PREGNANCY TESTS

CHORIONIC HYDANTHOIN MOLES MUMMOE FETTERS

ECTOPIC PREGNANCY

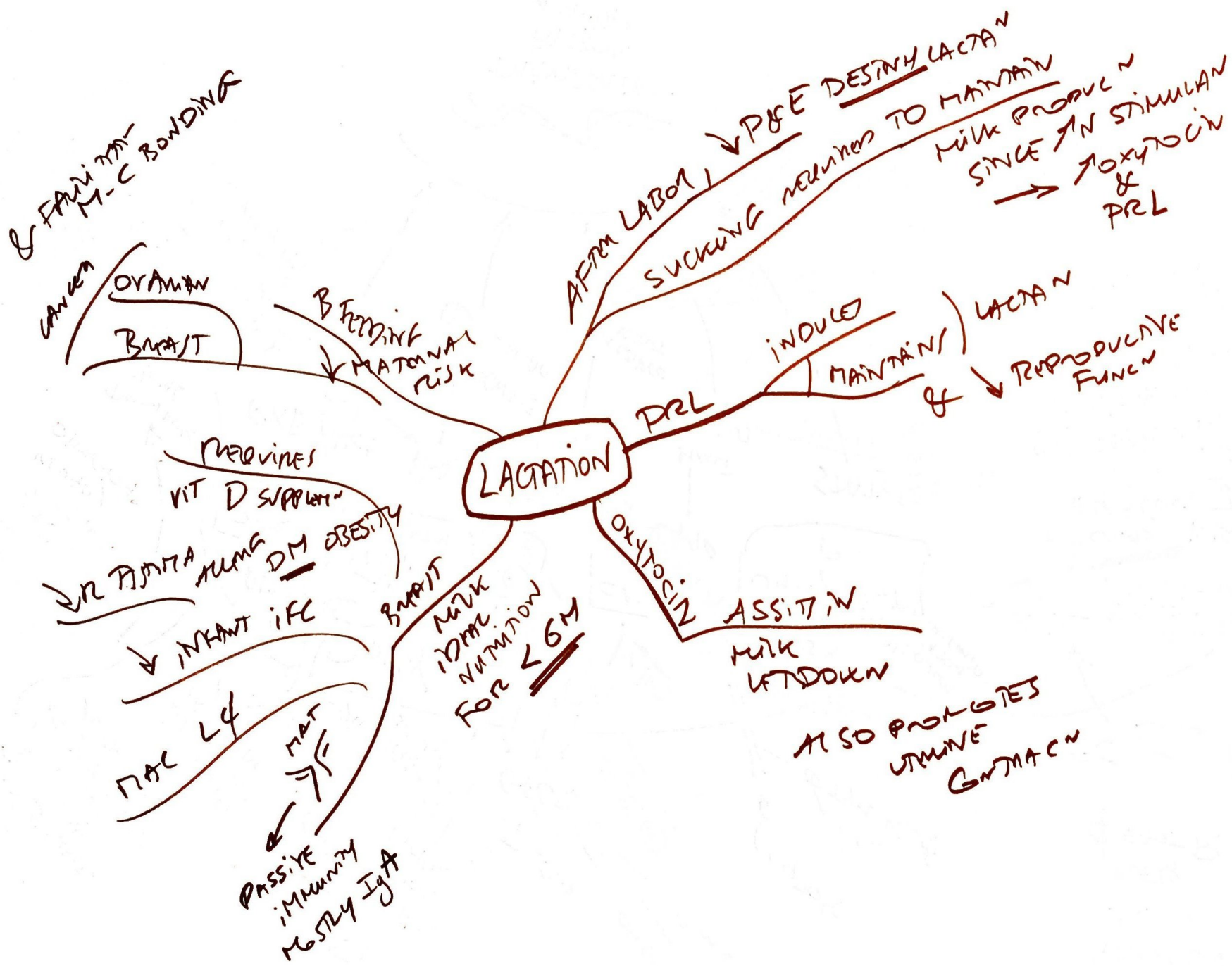
PLACENTA

W PREGNANCY

PLACENTA

PLACENTA

PLACENTA



(PREMATURE
OVARIAN FAILURE)
10 OVARIAN
INSVF

SUCCEEDS
BEFORE
40y

BY AMENOR FOR 12M
↓ E PRODUCTION
AGE-UNKID
DELINE IN # OVARIAN
FOLLICLES
~ AGE ONSET 51y
ESTRADIOL STAGNANT

USUALLY PRESENT BY 4-5y
ON (MENOPAUSE)

SOURCE
ESTRONE
AFTER MENOPAUSE
BROUGHT
FORWARD
GIVE
OF AND
→ AND → MISDIAGNOSIS

MENOPAUSE

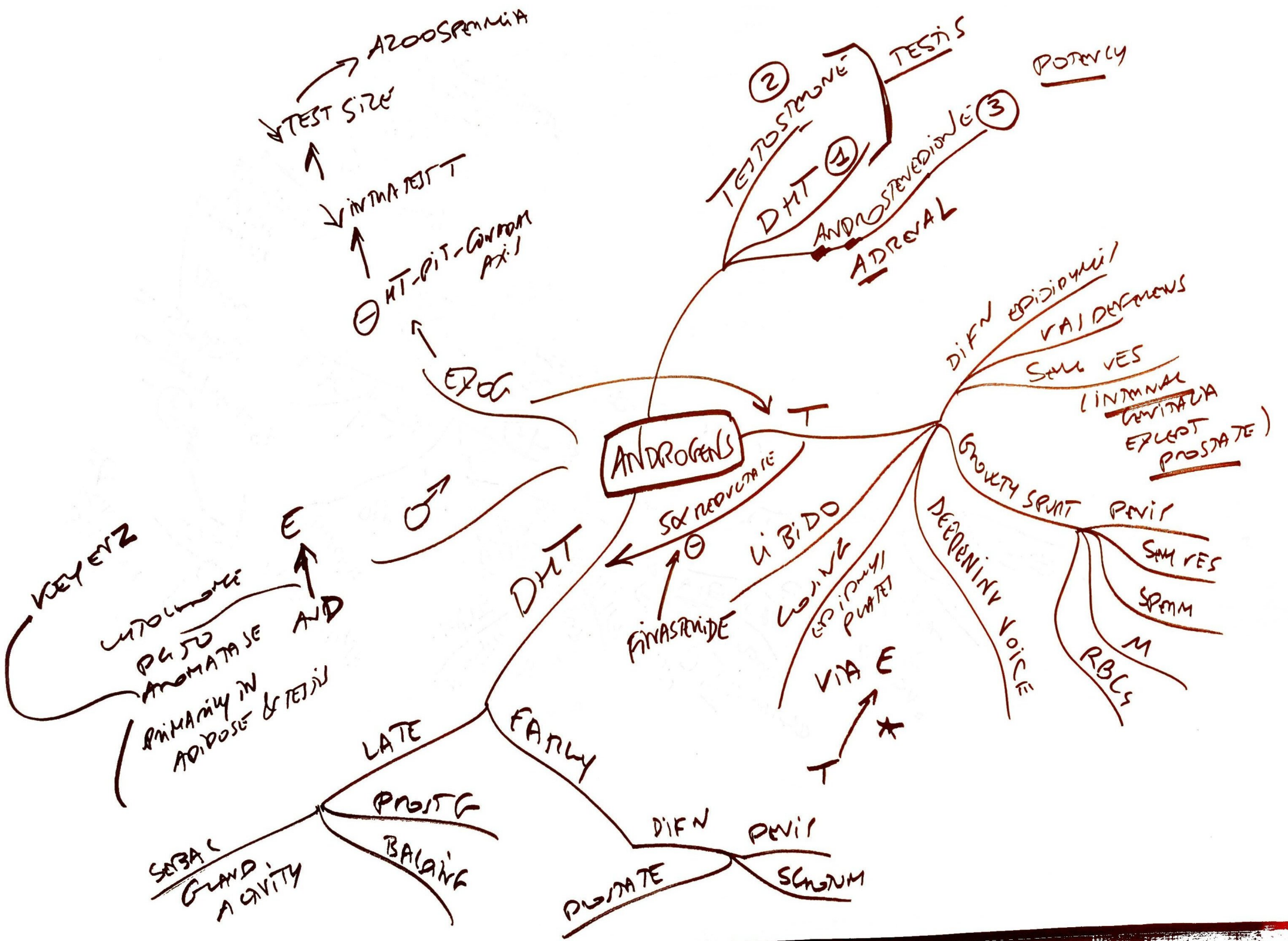- HOT FLASHES
- AUBURN
- VAGINA
- O STROPHOSIS
- C on A D
- SLEEP DISTURBS

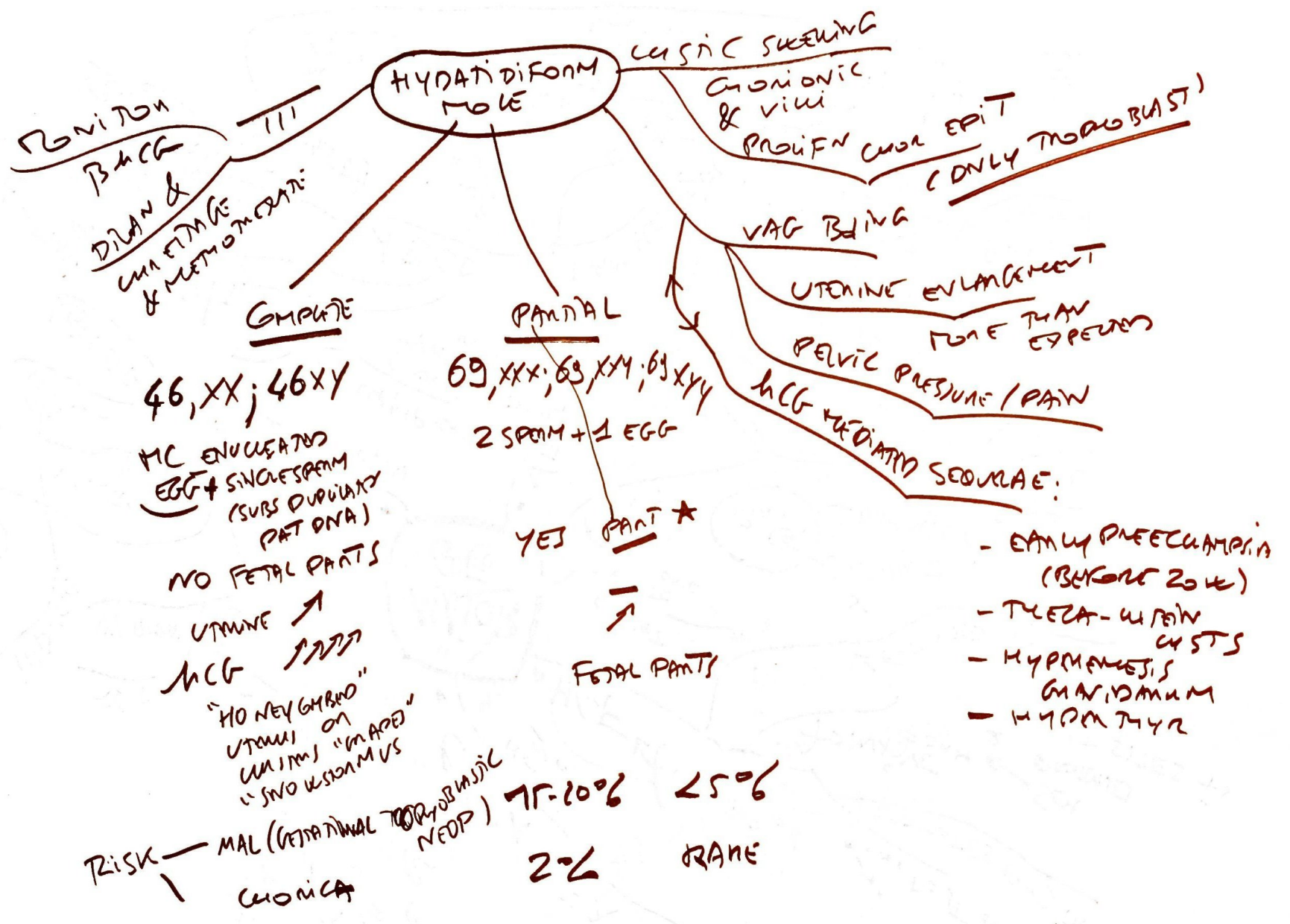

H CHANGES

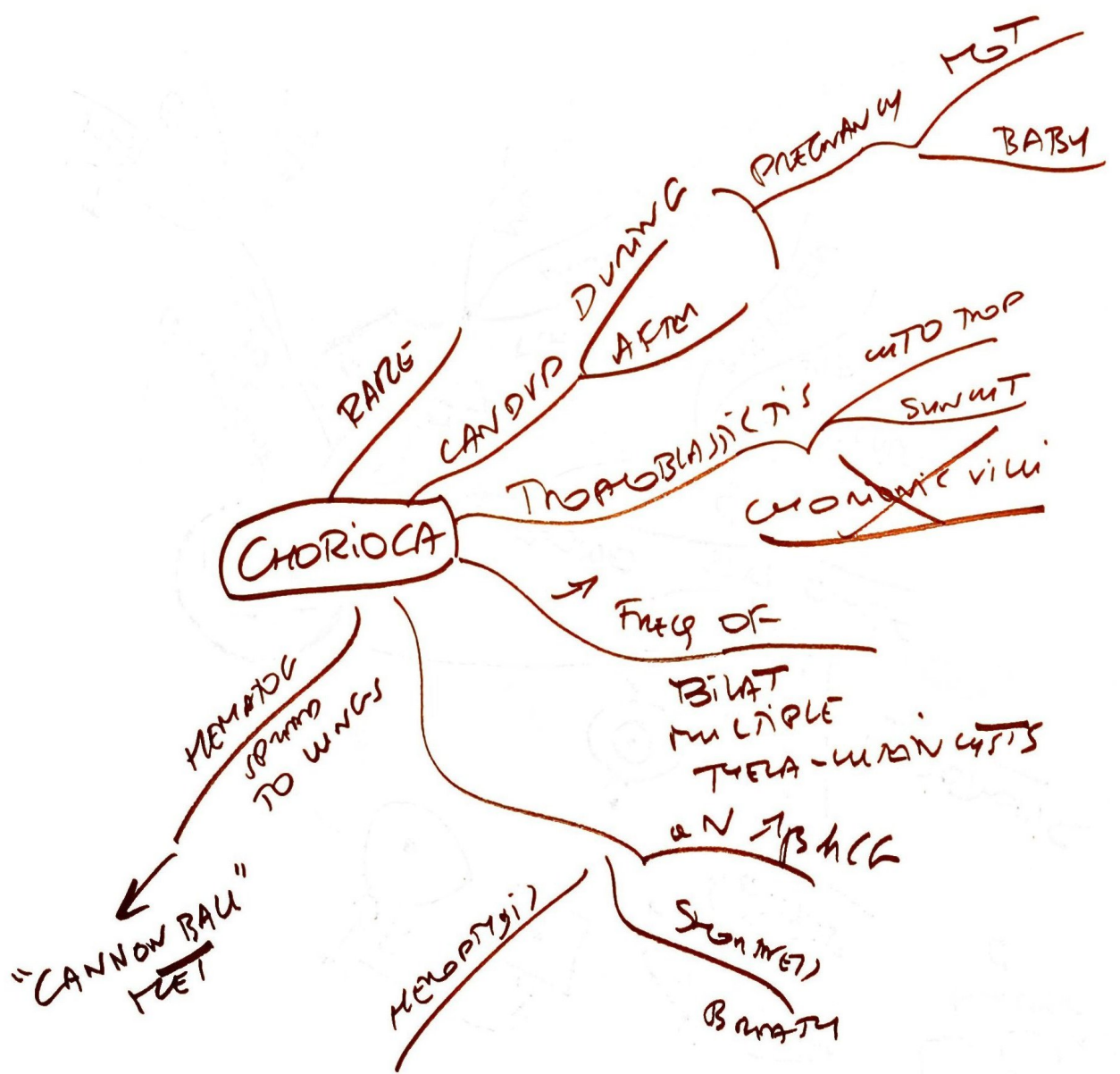
↑ GnRH
↑ LH
(NO SURGE)
↓ E
↑ FSH

↑ FSH SPECIFIC
(LOSS OF FB
ON FSH
↑
↓ E)

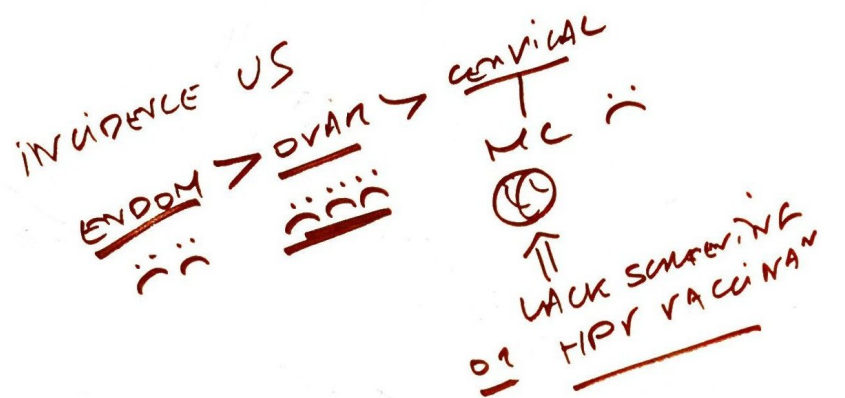




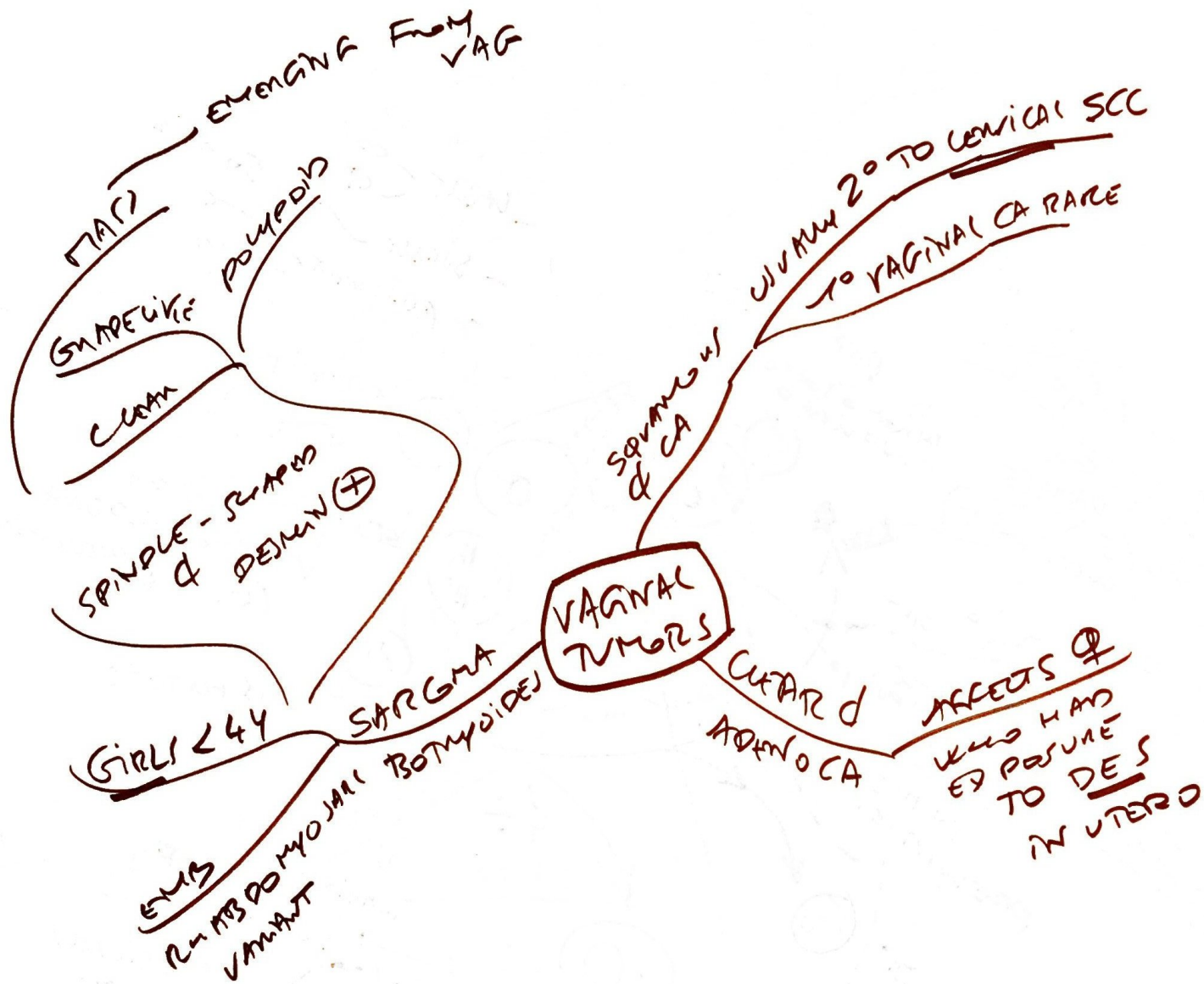
- EARLY PREECLAMPSIA (BEFORE 20 W)
- THECA-UTERINE CYSTS
- HYPOMAGNESIS GYNADANUM
- HYPOMAGNESIA

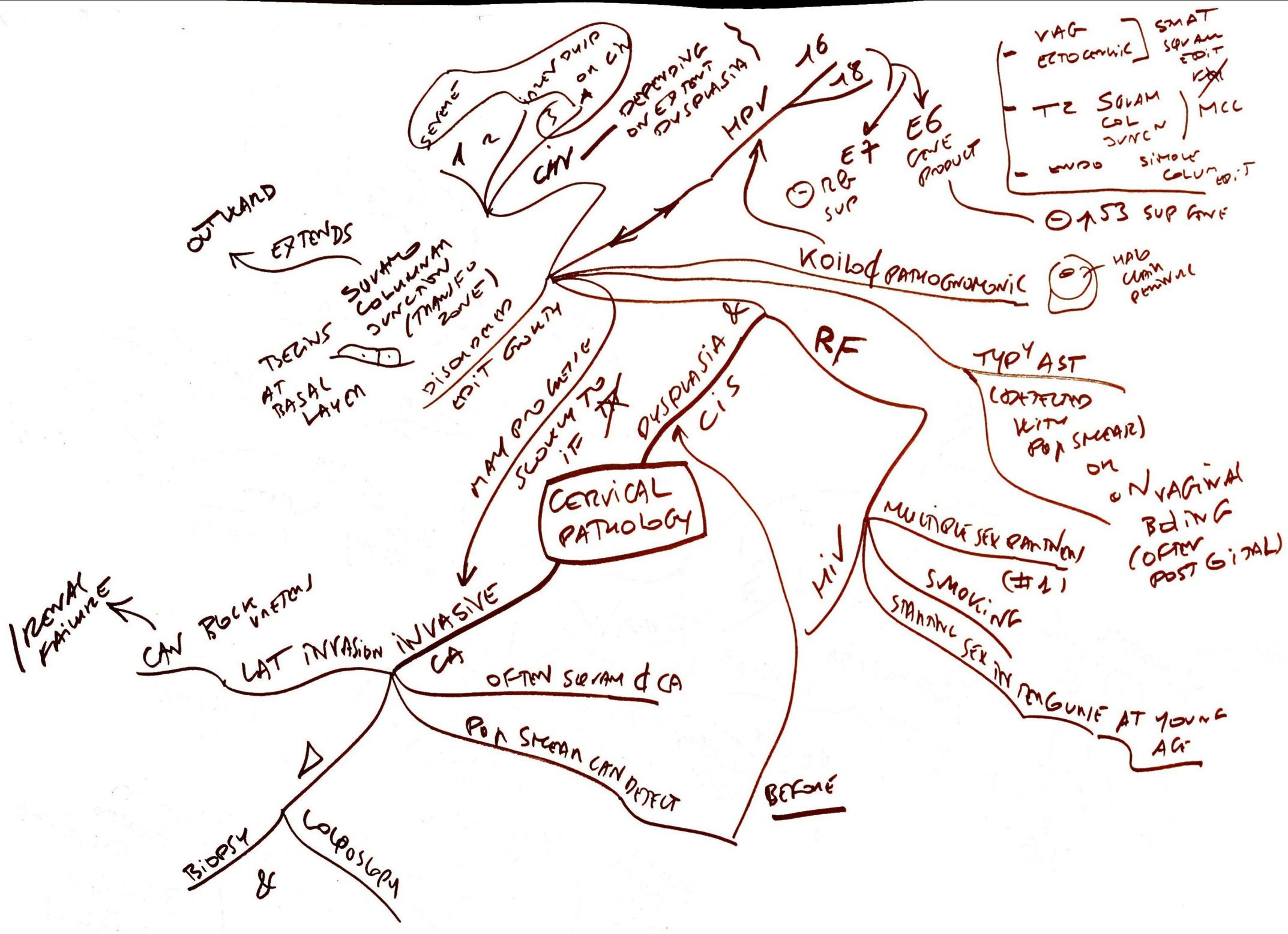


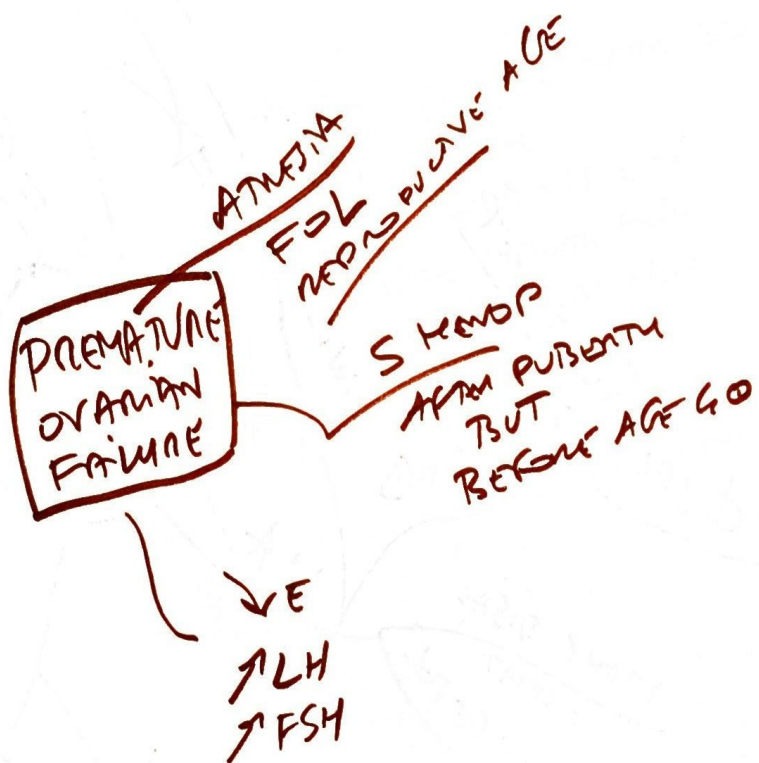
GYNECOLOGIC
TUMOR
EPIDEMIOLOGY



PROGNOSIS







MCC
Anovulation

PREGNANCY
POLYCYSTIC OVAR SD

OBESITY

HPO AXIS 2N

PREMENSTRUAL
PAIN

HYPERANDROGENISM

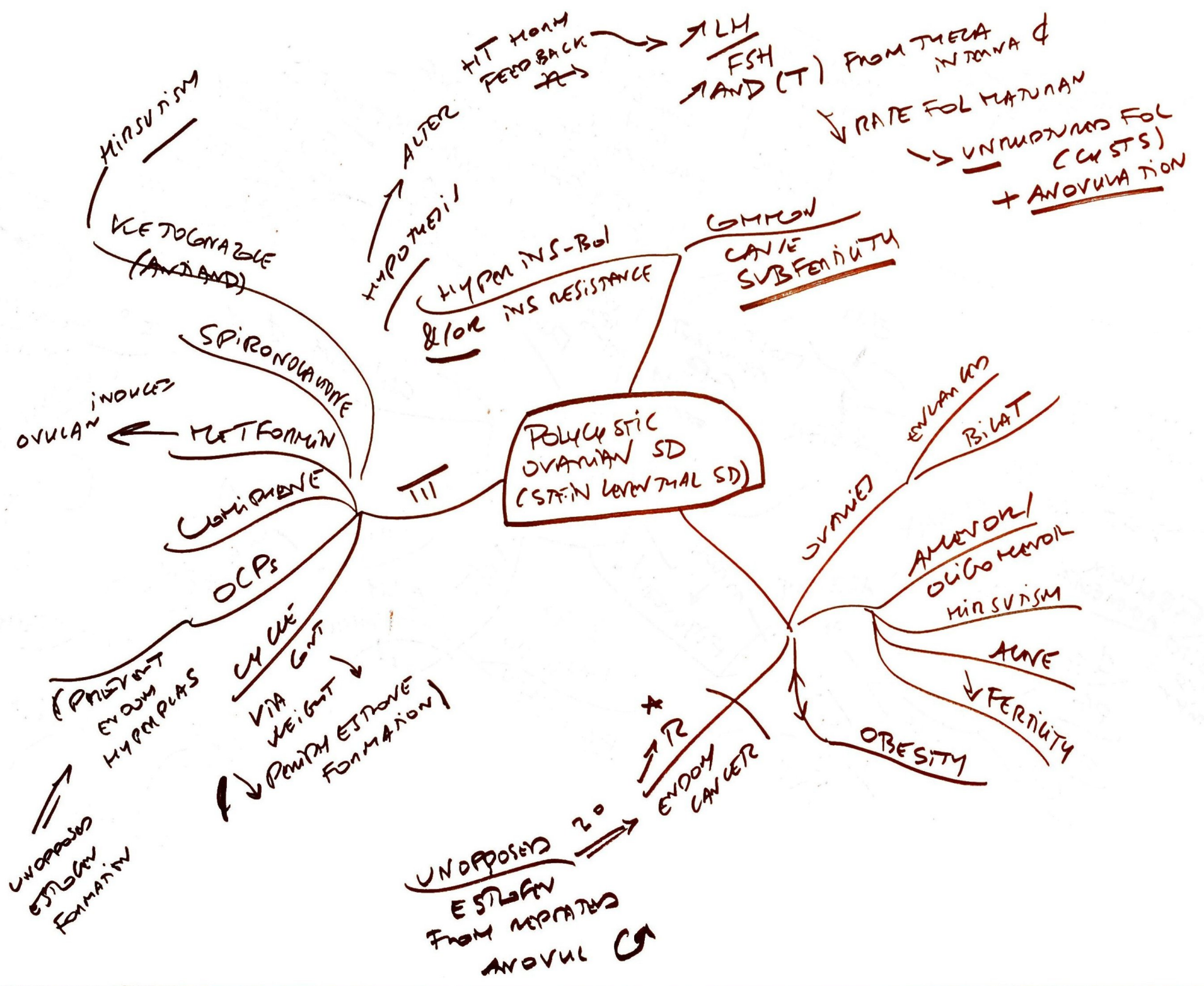THINNING OF HAIR

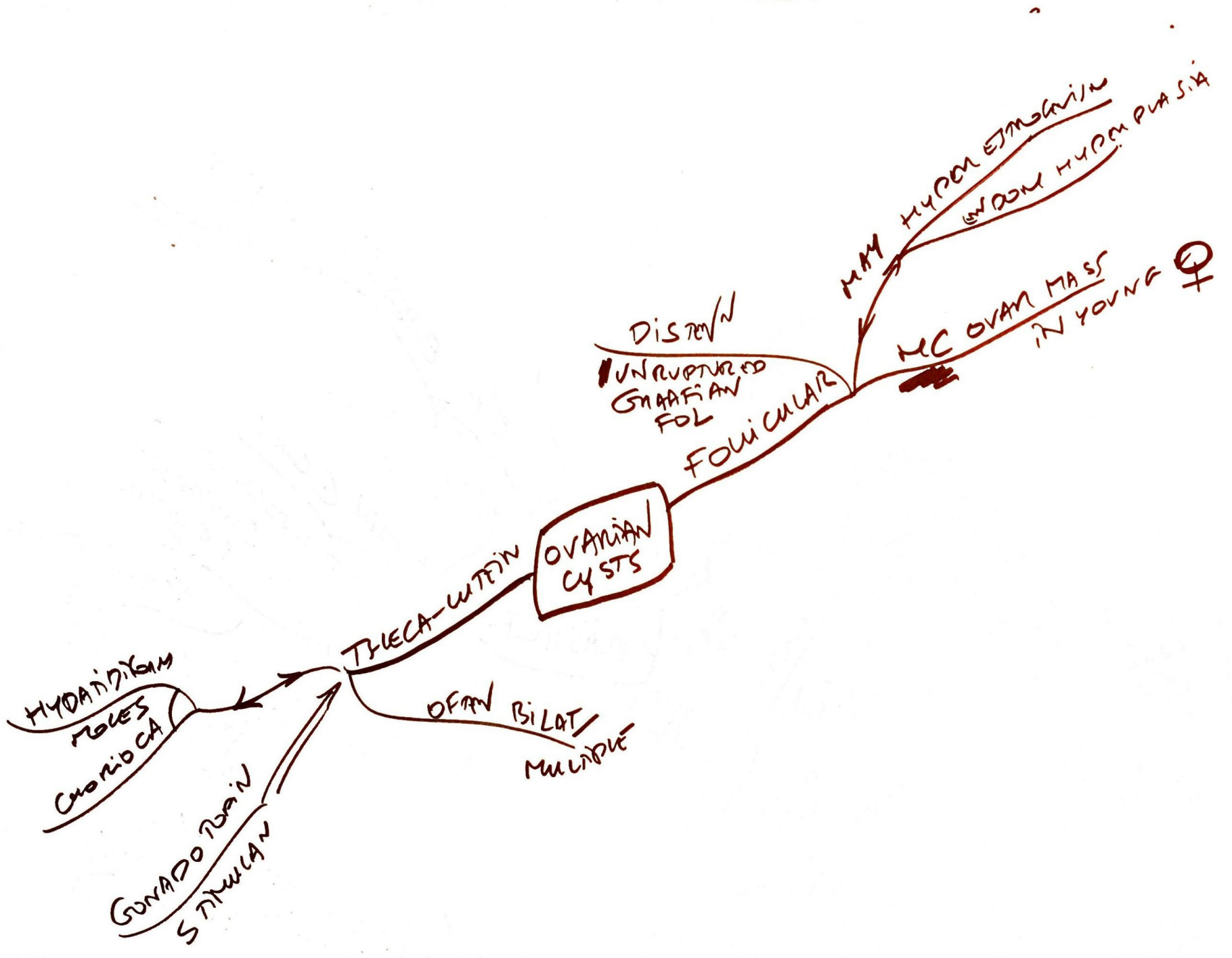
ACNE

EMOTIONAL LABILITY

CHROMOSOMAL ABNORMALITIES

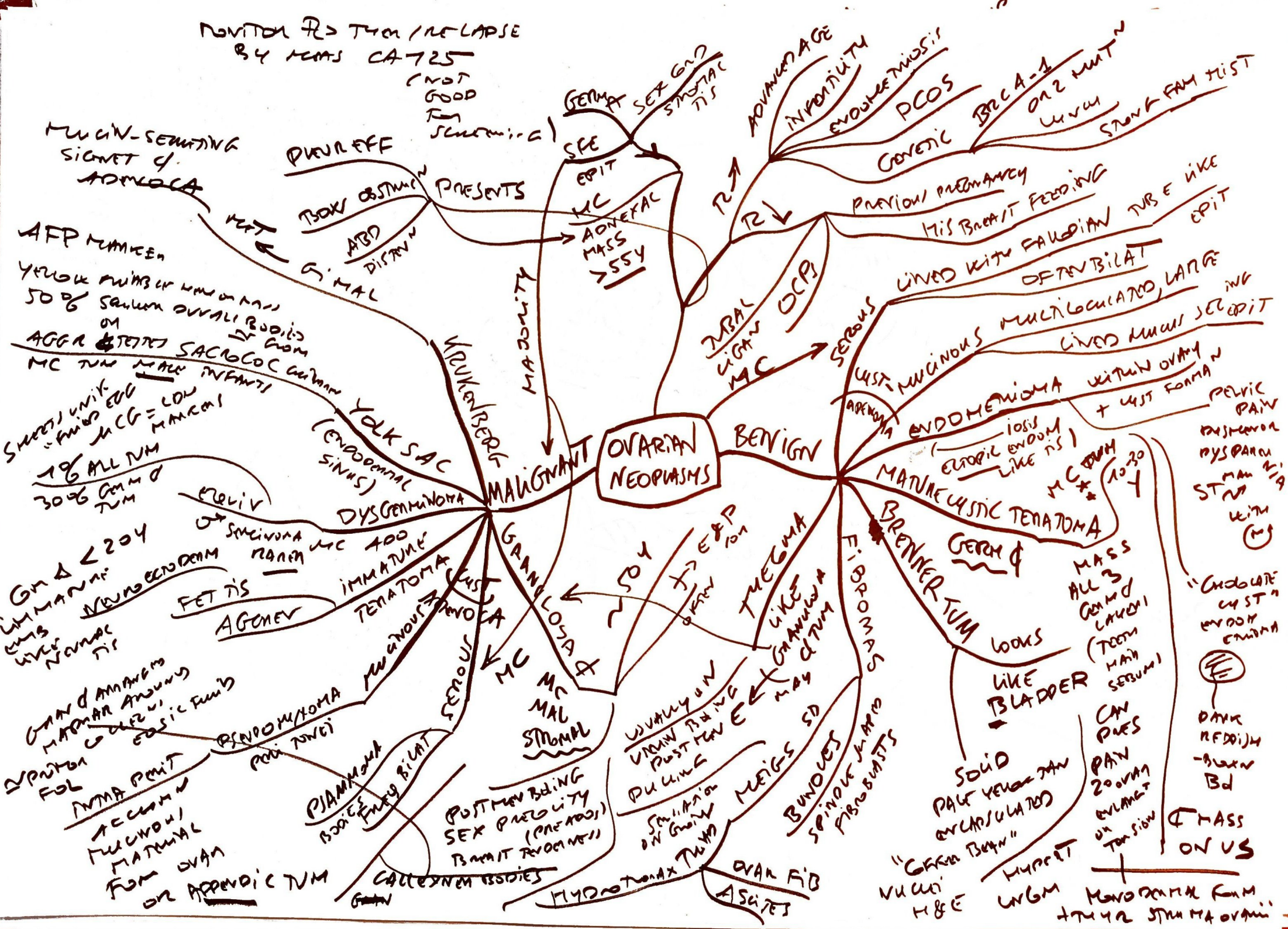
ADONEX

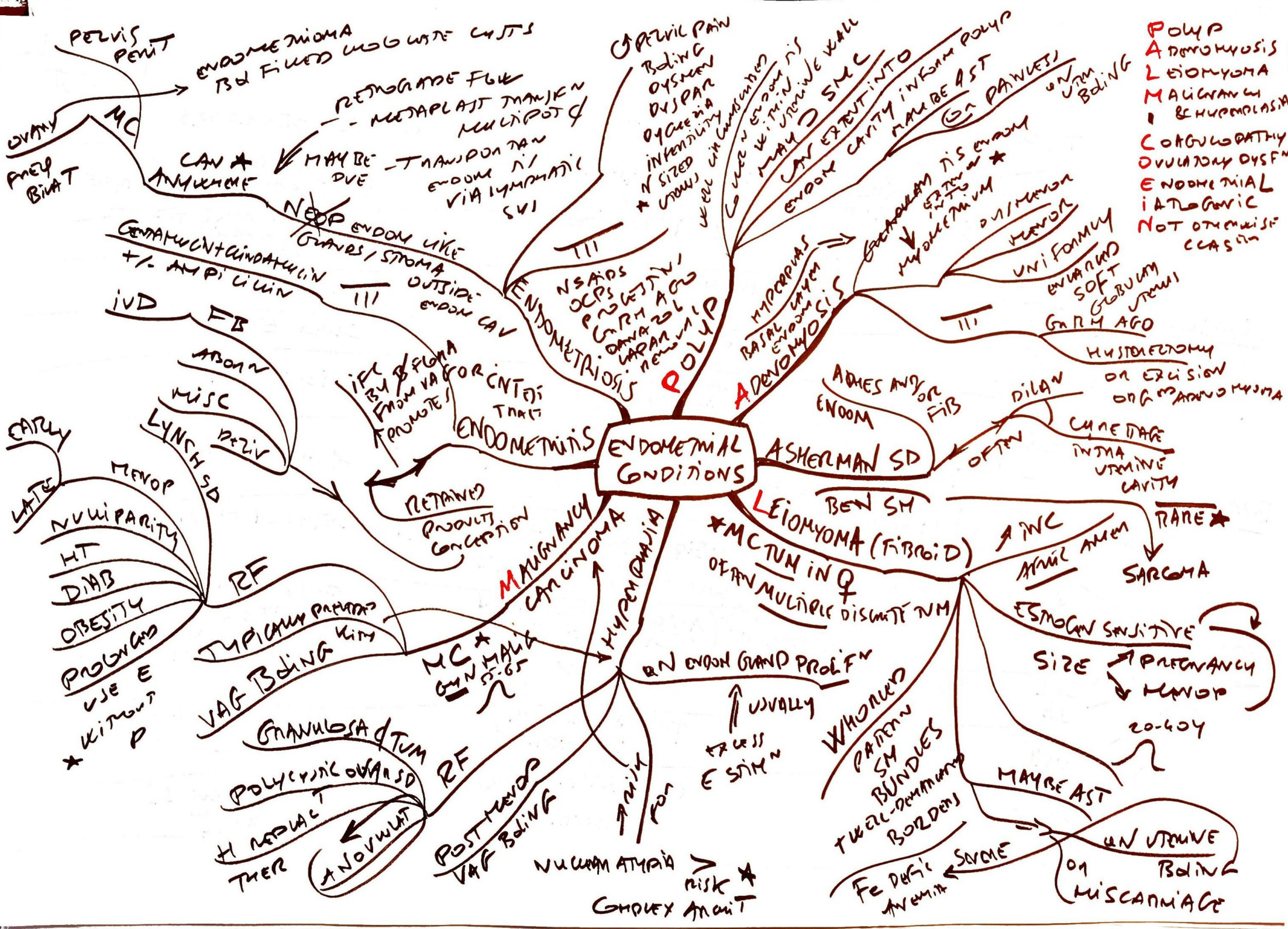




NOVITUM R2 THIN / RE-LAPSE
BY YEARS CA-725
(NOT GOOD
Tm
SURVIVAL)

OVARIAN NEOPLASMS





- POLYP
- ADENOMYOSIS
- LEIOMYOMA
- MALIGNANCY
- BEHPLOPLASIA
- CORRUPTATHY
- OVULATORY DYSFN
- ENDOMETRIAL
- IATROGENIC
- NOT OTMUSIC
- CASIN

PELVIS
PENT

OVARY
PREP
BIAT

EARLY
LATE

NUVIPARITY
HT
DMB
OBESITY
PROGNOS
USE E
* WITHOUT
P

GRANULOSA TUM

POLYCYSTIC OVAR SD

ENDOMETRIOSIS

ENDOMETRIOSIS

ENDOMETRIOSIS

ENDOMETRIOSIS

ENDOMETRIOSIS

ENDOMETRIOSIS

ENDOMETRIOSIS

ENDOMETRIOSIS

ENDOMETRIOSIS

ENDOMETRIOSIS

ENDOMETRIOSIS

ENDOMETRIOSIS

ADENOMYOSIS

ADENOMYOSIS

ADENOMYOSIS

ADENOMYOSIS

ADENOMYOSIS

ADENOMYOSIS

ASHERMAN SD

ASHERMAN SD

ASHERMAN SD

ASHERMAN SD

ASHERMAN SD

ASHERMAN SD

LEIOMYOMA

LEIOMYOMA

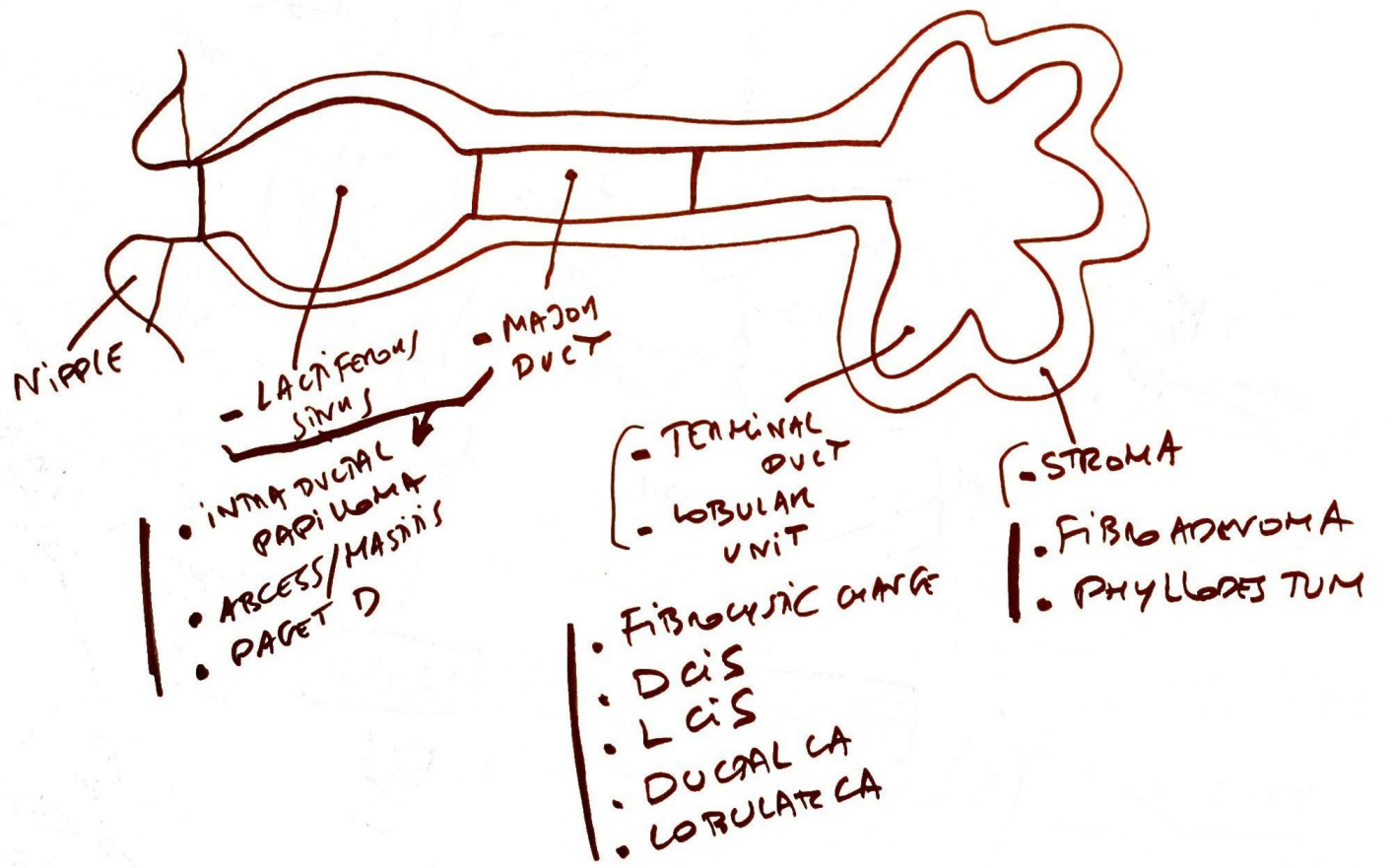
LEIOMYOMA

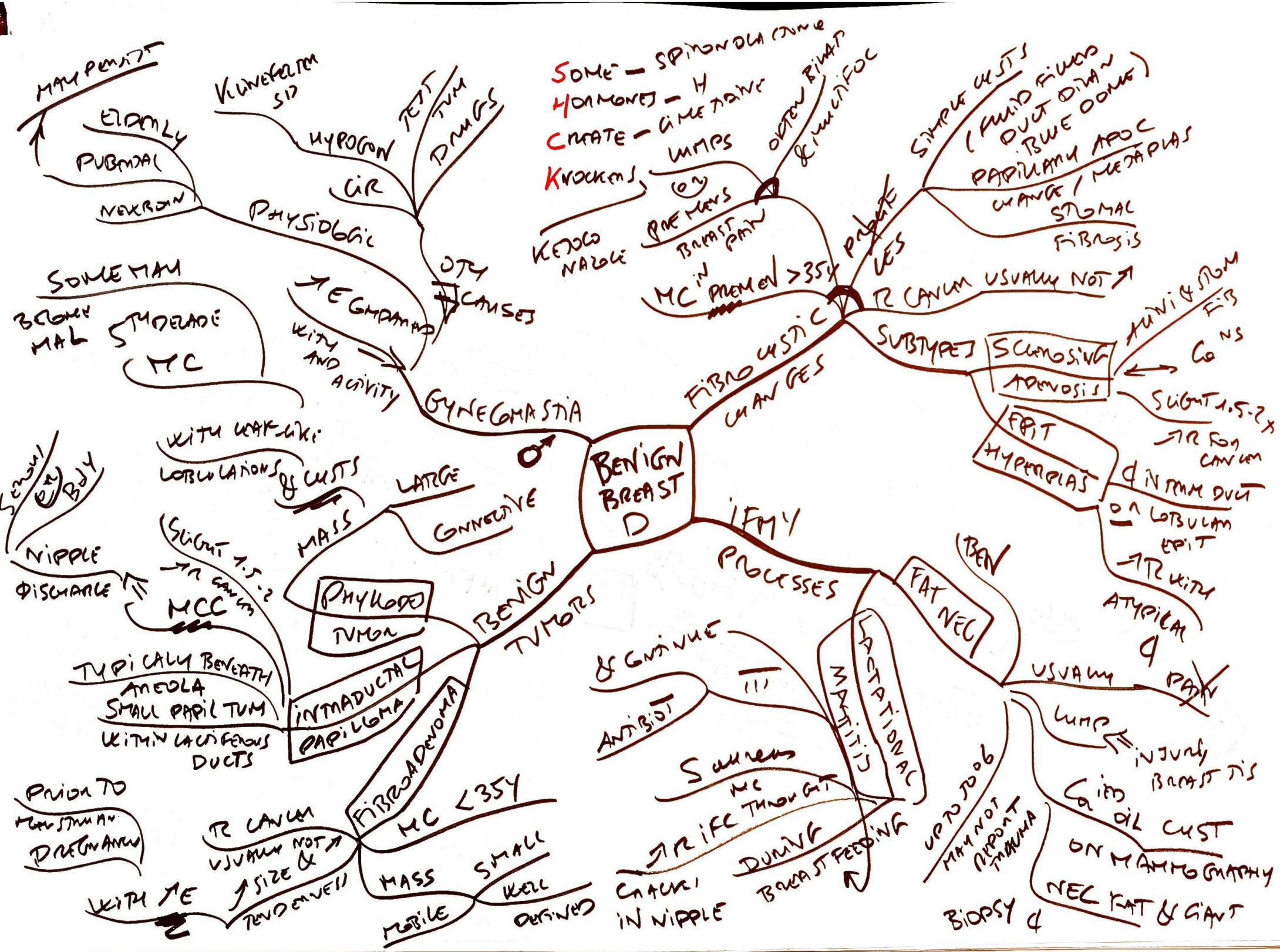LEIOMYOMA

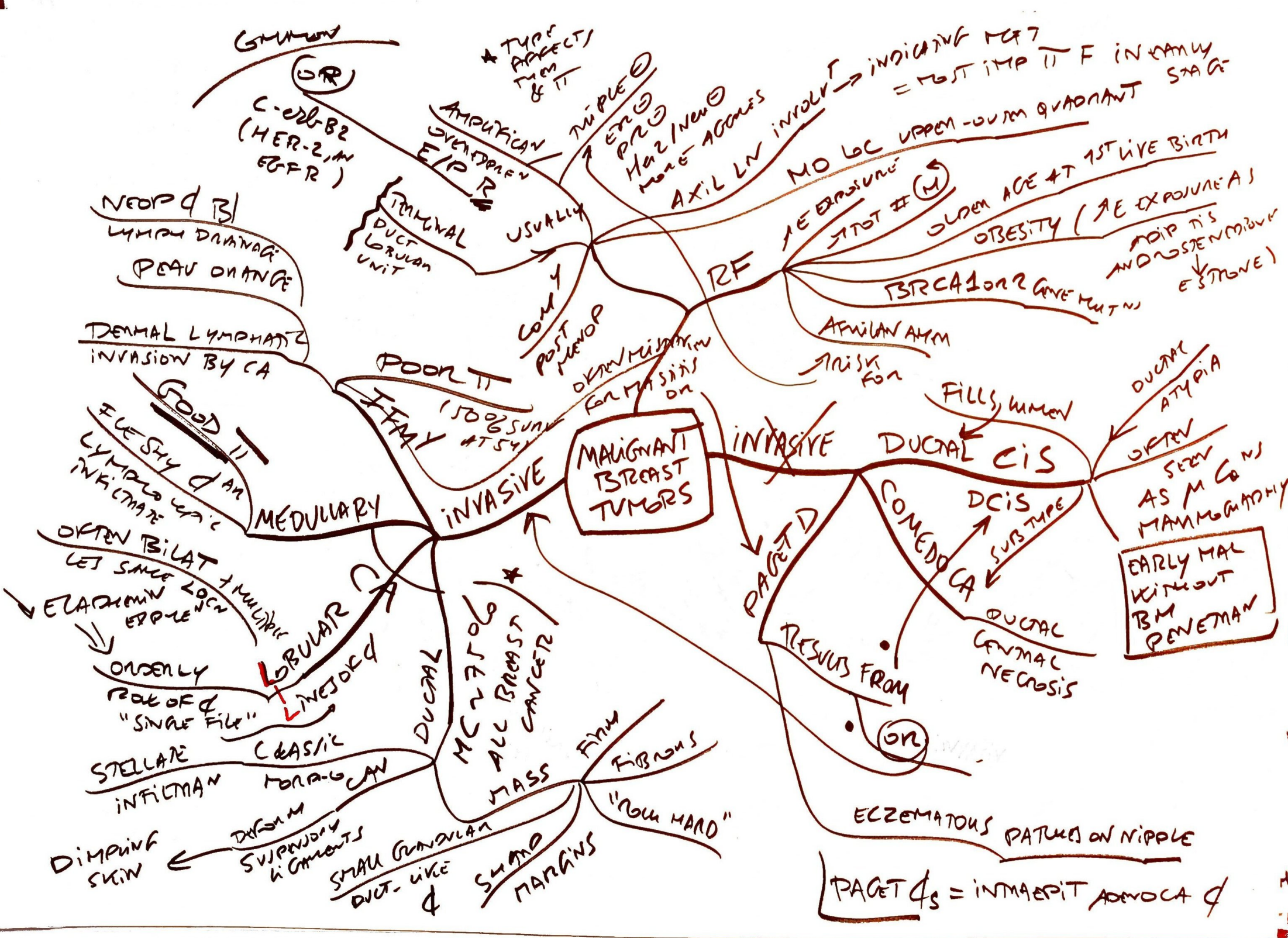
LEIOMYOMA

LEIOMYOMA

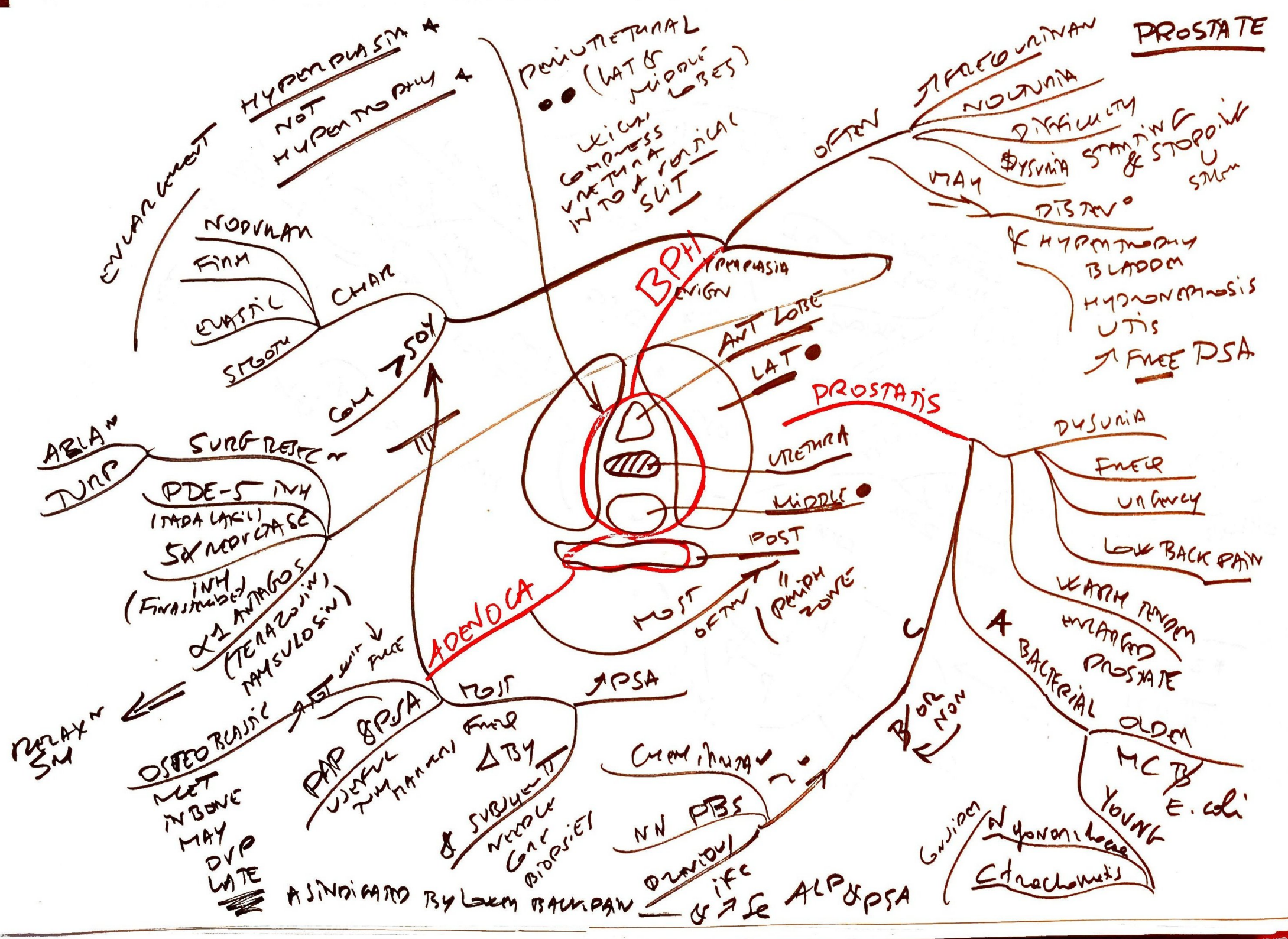
BREAST
PATHOLOGY







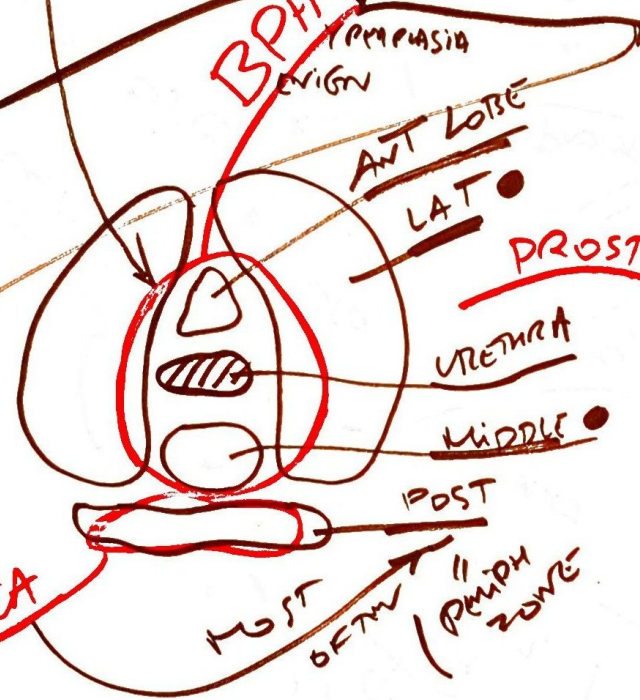
PROSTATE



HYPERPLASIA &
NOT
HYPERPLASIA &

PENILE RETRACTION
••• (LAT & MIDDLE LOBES)
WHICH COMPRESS URETHRA INTO A FIBRIL, SUT

STRECO URINARY
NOLUNA
DIFFICULTY
DYSURIA STARTING & STOPPING U
MAY
DISTURB
& HYPERMOTILITY
BLADDER
HYDRONEPHROSIS
UTIS
FREE PSA



ENLARGEMENT
NODULAR
FIRM
ELASTIC
SMOOTH
CHAIR
COLU 7504
PDE-5 INH (TADA LAKI)
5-ALPHA REDUCTASE INH (FINASTERIDE, DUTASTERIDE)
SURG RESECTION
TURP
ABLATION
TURP
DELAY IN SM
OSTEOBLASTIC
MET IN BONE MAY DVP LATE
AS INDICATED BY LOW BAKPAIN

AdenoCA

PROSTATIS

DYSURIA
PAIN
URINARY
LOW BACK PAIN
WEAK REMAN
ENLARGED PROSTATE
BACTERIAL
OLDER
MC B
YOUNG
E. coli
GUARDIAN
N gonorrhoeae
Chlamydiae

CURATIVE
NN FBS
ORNIDOL
ifc
& ALP & PSA

B/O R NON